

Original Articles

PERFORATION OF THE ESOPHAGUS A 12 – YEAR EXPERIENCE

V. MONTAZERIE, M.D., F.C.C.P.

From the Department of Thoracic Surgery, Imam Khomeini Hospital, Tabriz University of Medical Sciences, Tabriz, Islamic Republic of Iran.

ABSTRACT

Esophageal perforation continues to be a difficult diagnostic and management problem. Recommendations regarding treatment remain controversial. 17 patients with perforation of the esophagus were retrospectively reviewed at the Thoracic Surgery Unit of Imam Khomeini Hospital between 1981 and 1992. The majority of the injuries involved the thoracic esophagus (10 or 59%), followed by the cervical (6 or 35%), and the intra-abdominal esophagus (1 or 6%). Perforations caused by external trauma constituted most of the injuries (47%), followed by ingested foreign bodies (29%), iatrogenic causes (18%), and spontaneous perforation (6%). Excluded from this study were patients with tracheoesophageal fistulas, postoperative esophageal anastomotic leaks, and perforations due to esophageal carcinoma. Esophageal radiographic contrast studies with either Gastrografin or barium were performed in 11 patients with 2 (18%) false-negative results. Fever, chest pain, dysphagia, dyspnea and crepitus were common clinical findings. 2 patients (12%) were treated conservatively, 3 (18%) by primary repair and drainage, and 12 (70%) by drainage and diversion with or without exclusion. The author puts great emphasis on mediastinal drainage and irrigation in addition to diversion in late diagnosed cervical or thoracic esophageal perforations with pleural and mediastinal contamination.

MJIRI, Vol. 10, No. 2, 99-111, 1996.

INTRODUCTION

Whenever "esophageal perforation" appears in a paper, phrases like "true emergency",¹⁵ "catastrophic event",⁷ or "life-threatening condition"¹⁷ follow it. This seems rational for an occurrence that is nearly 100% fatal without treatment, and which continues to be associated with a mortality rate of more than 20% despite

modern forms of therapy.⁴¹

The condition was considered to be uniformly fatal for 200 years, after Boerhaave's description of spontaneous rupture of the esophagus in 1724,¹⁶ until the first successful drainage by Frink¹⁹ in 1941 and the first successful closure by Barrett⁴ in 1947. Since then a number of investigators have established the fact that early diagnosis and prompt initiation of treatment are essential

for acceptable results.

Rupture of the esophagus is a difficult clinical problem and its prompt diagnosis demands a high index of suspicion and excellent clinical judgement. Part of the problem in making an early diagnosis is that esophageal perforation is not a single entity. The patients are a heterogenous group, with perforations occurring from the cervical region to the intra-abdominal esophagus. Each location of injury poses its own particular problems in diagnosis and treatment. Delay in diagnosis commonly occurs in patients with "Boerhaave's syndrome", an unsuspected spontaneous rupture of the esophagus, mostly due to lack of consciousness of the disease, and consequent tendency to diagnose the cases as perforated peptic ulcer, pancreatitis, acute coronary disease, etc.³⁴

When the diagnosis of rupture is delayed, repair of the esophageal tear is hindered by the infection present at the margins to be sutured. Frequently, disruption of these sutures will occur, producing a recurrent leak at the point where badly damaged mediastinal tissue already exists.

Despite numerous reports that document a wide range of experiences in the treatment of esophageal injury, recommendations regarding treatment, particularly in the late diagnosed cases, remain controversial. The major clinical goal is to determine the optimal form of therapy in a heterogenous group of patients faced with a high degree of morbidity and mortality.

With these points in mind, we retrospectively reviewed a 12-year experience with 17 patients who had esophageal perforation, concentrating on the incidence, cause, anatomic location of the perforation, and the results of therapy. Trends in the treatment of esophageal perforation are documented and recommendations for management proposed.

PATIENTS AND METHODS

From March 1981 to March 1993, a total of 17 patients with a discharge diagnosis of esophageal perforation had undergone treatment at the Thoracic Surgery Unit of Imam Khomeini Hospital, a major teaching hospital of Tabriz University. We have divided this time interval into two periods, from 1981 through 1988 (during war period), and from 1989 to March 1993 (after cease fire), because we believe that this special situation of our country has had a great influence on the incidence and etiology of esophageal rupture.

13 male (76%) and 4 female (24%) patients were admitted. 9 of these patients were seen during the past 4 years (after cease fire), while only 8 patients were treated for esophageal perforation during the preceding

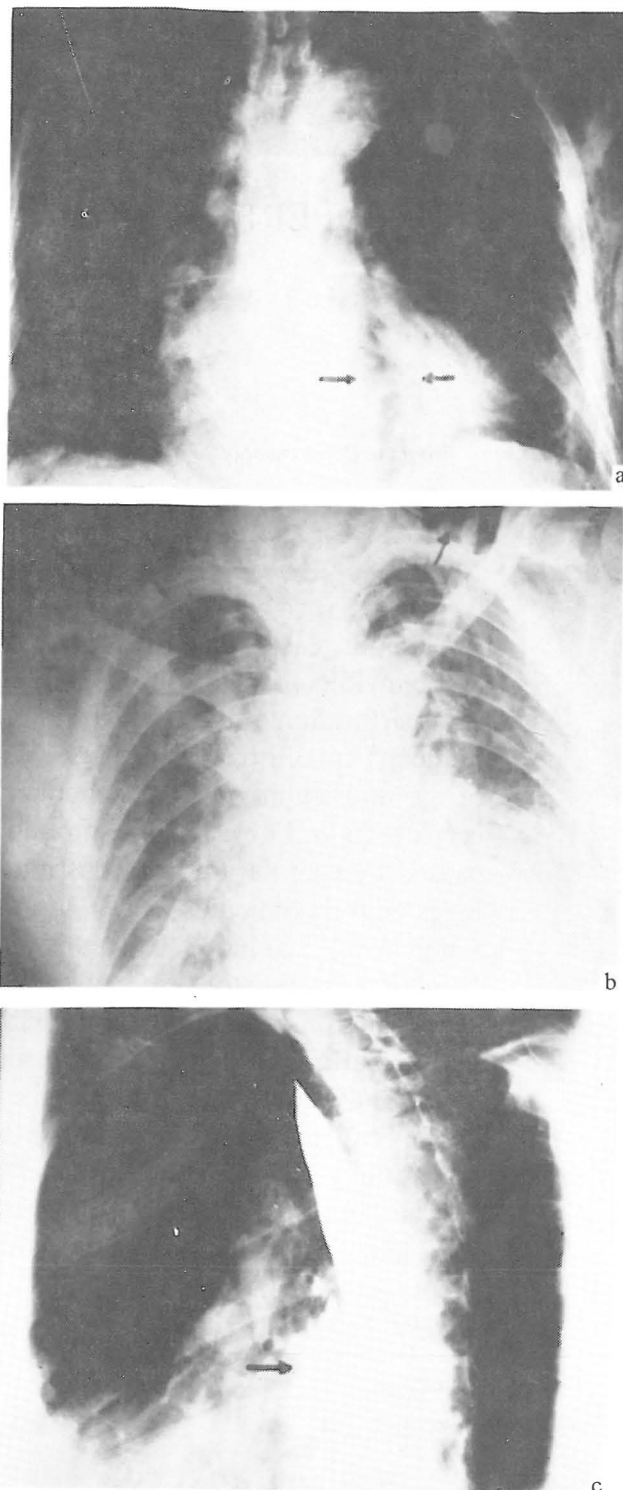


Fig. 1-a,b,c. Spontaneous perforation of the esophagus. Roentgenographic studies of a 77 year old man who was admitted with sudden chest pain of 24 hours' duration. Note the widened mediastinum and pneumomediastinum (a), severe subcutaneous emphysema, radiolucent streaks of air at the base of the neck, chest wall, and mediastinum (b), and extravasation of radiopaque contrast material into the mediastinum (c).

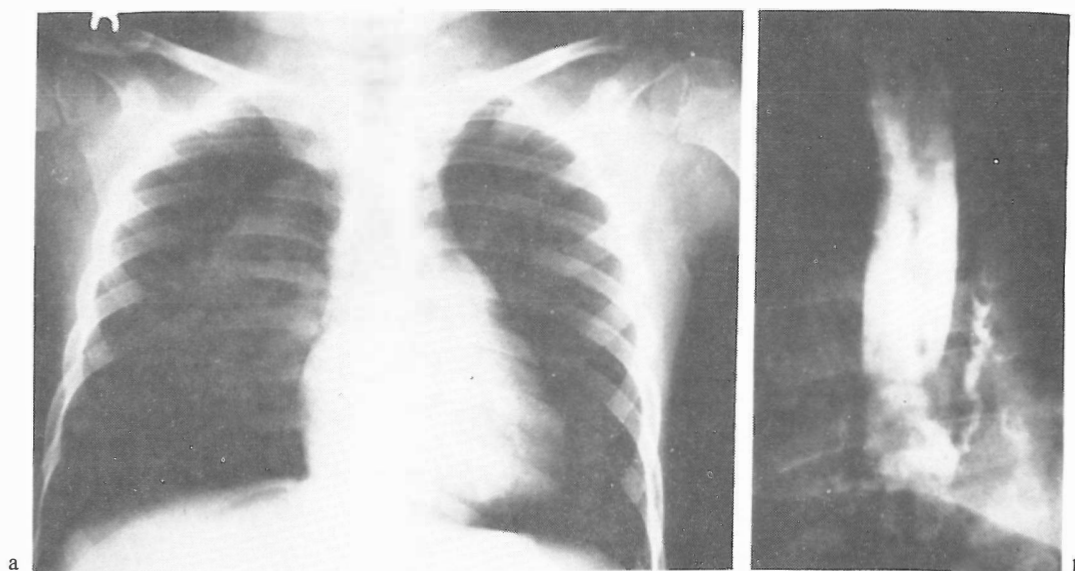


Fig. 2-a,b. Instrumental perforation of the esophagus. Right pneumothorax following esophageal dilation in a 6 year old boy (a), and extravasation of Gastrografin in the pleural space (b).

8 years (during the war). 5 of them were soldiers serving at the fronts, and esophageal perforation in all 5 of them was due to missiles. Their age range was from 7 to 77 years with a mean of 34 years. The mean age of patients in the past four years was 46 years, while it was 21 years in the war time.

The site of esophageal perforation was cervical in 6 cases, intrathoracic in 10 patients, and intra-abdominal in only one. Of 6 cervical perforations, one occurred during endoscopy, 3 were from missiles, foreign body ingestion (a pin) was the cause of one perforation, and one case was due to a stab wound. Intrathoracic esophageal perforation followed endoscopy in one patient, while foreign bodies (bones) were the cause in 4 cases. Perforation was due to Heller's myotomy in one patient. Missiles caused disruption in 2 patients. Spontaneous rupture occurred in one patient and we had one case of intrathoracic esophageal perforation caused by blunt trauma (automobile accident). Gun-shot wound was the cause of the only case of intra-abdominal perforation.

Excluded from this study were patients with tracheoesophageal fistulas, postoperative esophageal anastomotic leaks, and perforations due to esophageal carcinoma.

Upon evaluation of the records, clinical signs and symptoms were taken into notice. Neck or chest pain, dysphagia, dyspnea, crepitus, and elevated body temperature were common findings. All patients had a routine posteroanterior chest roentgenography on admission. Occurrence of mediastinal or subcutaneous air, pneumothorax, widening of the mediastinum and evidence of pleural fluid favoured the diagnosis (Figs. 1

and 2). Esophageal radiographic contrast studies with either water soluble medium (Gastrografin) or barium were performed in 11 patients. In 10 cases Gastrografin was used initially in order to prevent contamination of the mediastinum and pleura with barium, if a perforation was demonstrated (Fig. 3). There was no extravasation of contrast material in 2 patients (18%). In one of them, the examination was repeated with barium, which also failed to show the perforation. Methylene blue swallow examination in the lateral decubitus position was performed in 4 patients. In one case, there was a high index of suspicion for esophageal perforation, while contrast studies with both Gastrografin and barium were normal, and spill-out of dye was not seen. Endoscopy also failed to demonstrate the perforation. The diagnosis was made on the basis of the characteristic history, clinical data, and chest x-ray findings. In the other 3 patients the examination was performed immediately following clinical suspicion and yielded two positive and one false-negative result. Diagnostic endoscopy was performed in 2 cases. In one patient, mentioned above, it was done when all other procedures failed to demonstrate the perforation. The esophagus was falsely reported to be totally normal. The procedure was performed in the patient with Boerhaave's syndrome, demonstrating the perforation site and underlying esophageal disease. In all patients who had ingested foreign bodies, endoscopy was performed in an attempt to remove the bone.

In the review of records, an elevated white blood cell count was the usual laboratory finding. From 6 patients with cervical esophageal perforation, 5 had an

elevated white blood cell count, as was the case in all of the patients with intrathoracic perforations.

The management of perforations in this series as well as others can be categorized into three general forms. The first is nonoperative or conservative, which is generally accepted as giving the patient nothing by mouth, administering intravenous fluids and antibiotics, nasogastric drainage and optimal hyperalimentation. 2 patients in our series were treated in this fashion. The second form of therapy is operative debridement, suture closure of the perforation, optimal buttressing or patch procedures, drainage tube gastrostomy, and feeding jejunostomy. 3 of our patients were in this category, although one of them had a buttressing procedure with pleural flap. The third form of therapy is commonly designated as drainage, diversion and exclusion. This category includes 12 of our patients. Drainage of the pleura and mediastinum was achieved through closed thoracotomy. Diversion of esophageal and gastric contents was performed by using nasogastric suction and drainage tube gastrostomy. In 4 cases exclusion of the esophagus was accomplished by esophagostomy or esophageal band. Transesophageal mediastinal irrigation was performed in 6 of 9 cases of thoracic esophageal perforations treated by drainage, diversion and exclusion methods.

The method of transesophageal mediastinal irrigation

The method consists of profuse transesophageal irrigation of the mediastinum with orally ingested fluid provided with wide drainage of the mediastinal area involved by the noxious bacterial and chemical materials spilled from the esophagus, associated with adequate antibiotic coverage. Such irrigation removes from the mediastinum bacterial organisms, fibrin and debris via the chest tubes. If the patient cannot drink, mediastinal irrigation is accomplished with a nasogastric tube positioned in the upper esophagus proximal to the perforation and connected to a bottle containing saline solution that is allowed to drip at a rate sufficient to keep the mediastinum clean. This technique was described by Santos et al. in 1986.⁴³ We start with 50 to 70 ml saline and 250 mg of metronidazole oral solution on alternate hours that is enough to wash irritating agents away from the mediastinum and to instill a high concentration of antibiotics at the site of perforation. It is continued until the egress fluid through the outflow tubes is clear of debris. As the irrigation progresses, increasing amounts of fluid will go down into the gastrointestinal tract, making it possible to decrease in comparable amounts intravenous or jejunal hydration. At this stage, careful monitoring of electrolytes will determine the concentration of saline solution to be used for irrigation. Fluid

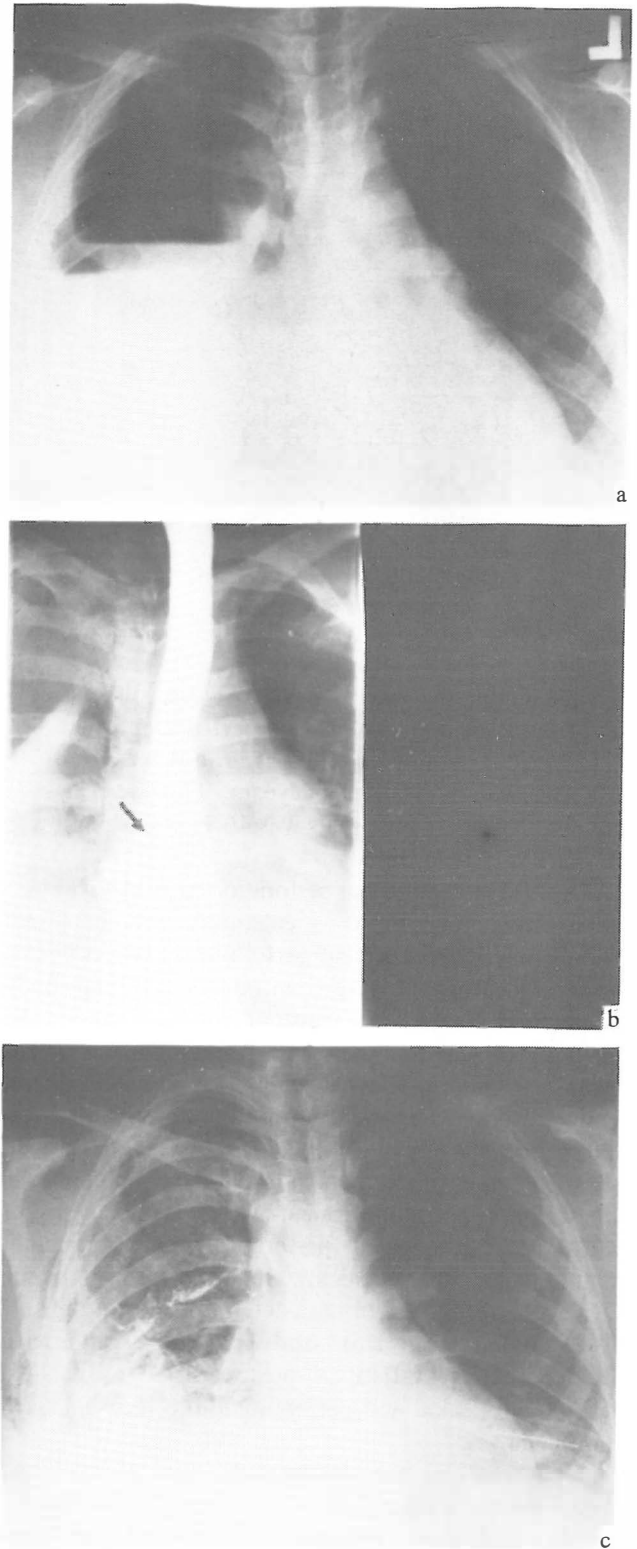


Fig. 3-a,b,c. Postero-anterior chest x-ray revealing a right hydropneumothorax seen after rupture of the esophagus (a); esophagogram of same patient showing extravasation of Gastrografin in the right pleural space (b), and chest x-ray (PA) after drainage of the right pleural cavity (c).

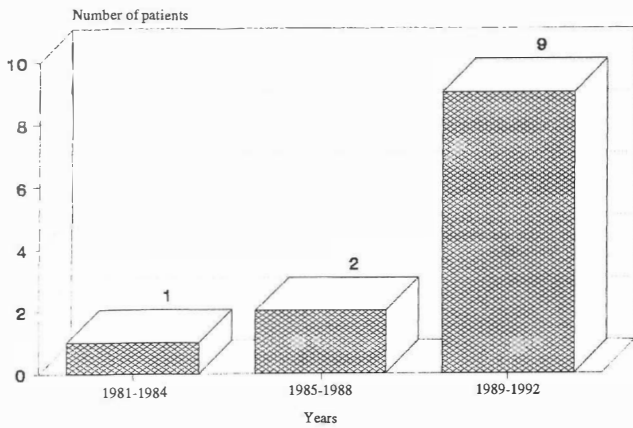


Fig. 4. Incidence of esophageal perforation at Tabriz University Medical Center from 1981 to 1992.

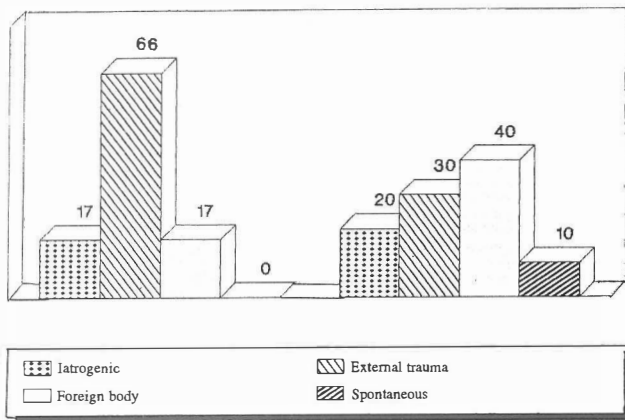


Fig. 5. Causes of esophageal perforation according to anatomical site.

overload is avoided by accurate measurement of fluids entering the esophagus and leaving the drainage tube.

As soon as the patient's condition improves, more nourishing liquids can be given orally. Care should be taken to finish the feeding with clear water in order to wash out particulate matter which could stimulate bacterial growth.

The draining catheters are removed when esophageal leakage has stopped for several days and confirmed by an esophagogram.

RESULTS

Incidence

The incidence of esophageal perforation between 1981 and 1992 is shown in Figure 4. The 5 cases of esophageal perforation due to missiles are excluded for a more accurate evaluation of the trend of incidence.

Etiology

(a) **Iatrogenic perforation:** 3 patients (18%) had an iatrogenic perforation of the esophagus. 2 cases occurred during diagnostic esophagoscopy in patients complaining of dysphagia and no underlying esophageal disease. One perforation occurred after Heller's myotomy. All three survived.

(b) **Spontaneous perforation or Boerhaave's syndrome:** Only one case of spontaneous perforation was seen during this 12-year period. It occurred after an episode of vomiting. There was no predisposing esophageal disease, and the patient expired.

(c) **Perforation caused by foreign body:** Perforation was due to foreign body ingestion in 5 patients (29%). It was the most common cause of esophageal perforation during the past four years. 4 patients survived.

(d) **External trauma:** The cause of esophageal perforation was external trauma in 8 patients (47%). One case of perforation was the result of blunt trauma related to a motor vehicle accident. Another patient had a rupture of the esophagus from a stab wound. 6 other perforations were caused by missiles. There was one death in this group, which occurred in a patient with abdominal esophageal perforation caused by a gun-shot wound.

The cervical esophagus was the most frequently injured portion as the result of external penetrating trauma, while iatrogenic perforations and spontaneous rupture occurred more often in the thoracic portion. (Fig. 5).

Symptoms and signs

Most patients (88%) experienced pain. 13 patients (76%) had a temperature greater than 38°C during their hospitalization. Subcutaneous emphysema was present in 4 (67%) of 6 patients with cervical perforation and 5 cases (50%) of thoracic esophageal perforation. 3 patients (18%) were hypotensive at the time of diagnosis. Leukocytosis was present in 94% of the patients. Dysphagia and dyspnea were common presenting symptoms (47% and 65%, respectively).

Routine upright chest roentgenograms revealed that 71% of the patients had pleural effusion, 24% pneumothorax, and 41% pneumomediastinum (Fig. 6).

Extravasation of contrast material was obvious in 9 (82%) of 11 esophagograms which were performed. False-negative results occurred in 25% of the thoracic perforations.

Diagnosis

The diagnosis of esophageal perforation was usually

Perforation of the Esophagus

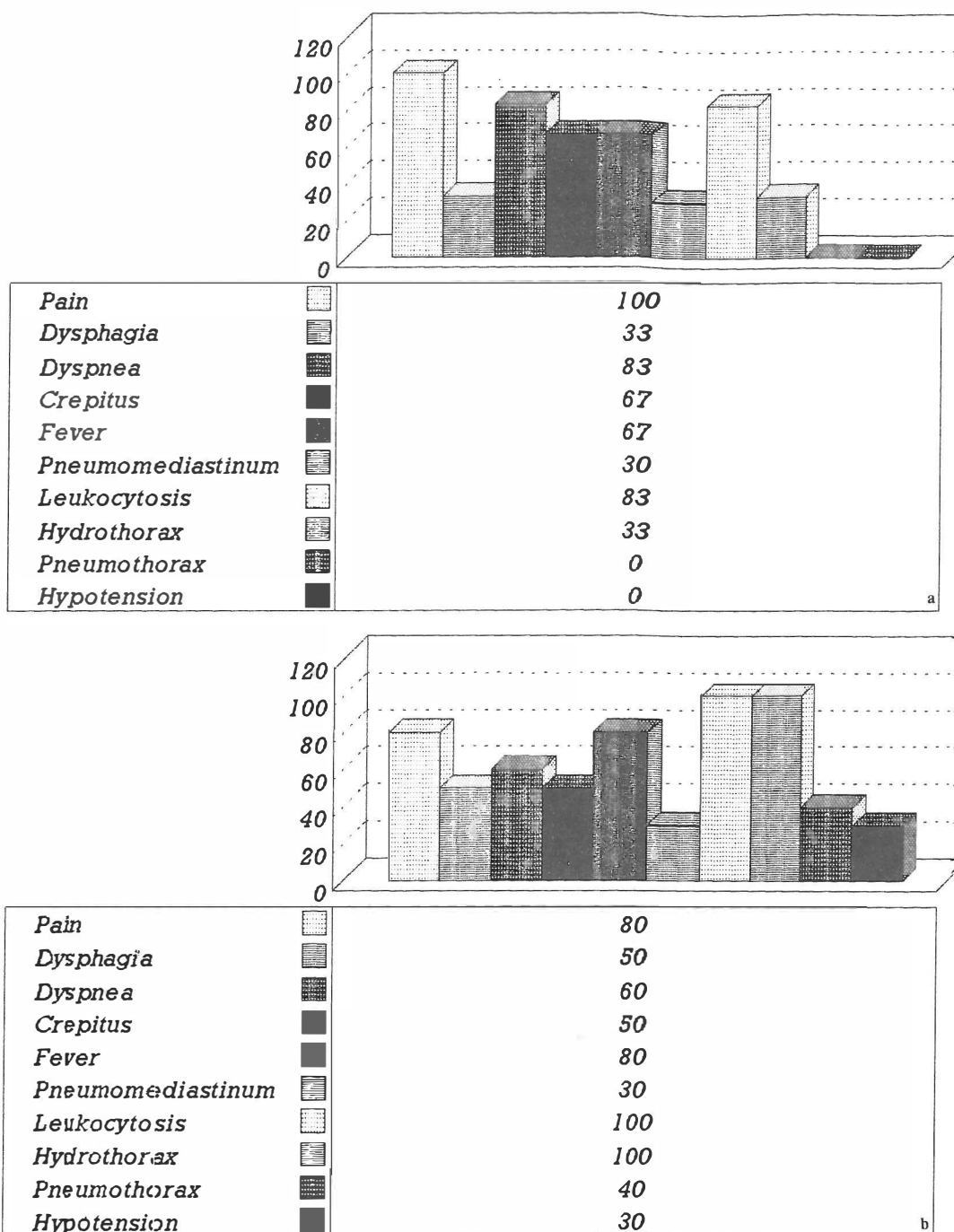


Fig. 6-a,b. Distribution of signs and symptoms after perforation of the cervical and thoracic esophagus.

suspected on the basis of presenting signs and symptoms, the suspicion being corroborated by the fact that the signs and symptoms followed clinical events such as esophagogastric instrumentation.

Roentgenographic examination of the chest and the esophagogram were the most valuable diagnostic studies. A roentgenogram of the cervical spine was helpful in some cases suspected of having perforation of the cervical esophagus. Air was often evident in the

prevertebral tissue planes.

The interval between perforation and its diagnosis exceeded 24 hours in 12 patients (71%). This delayed diagnosis in the majority of cases was mostly due to late referral from other medical centers.

Treatment

(a) Nonoperative treatment: This was elected in 2 patients (12%) with cervical esophageal perforation. This

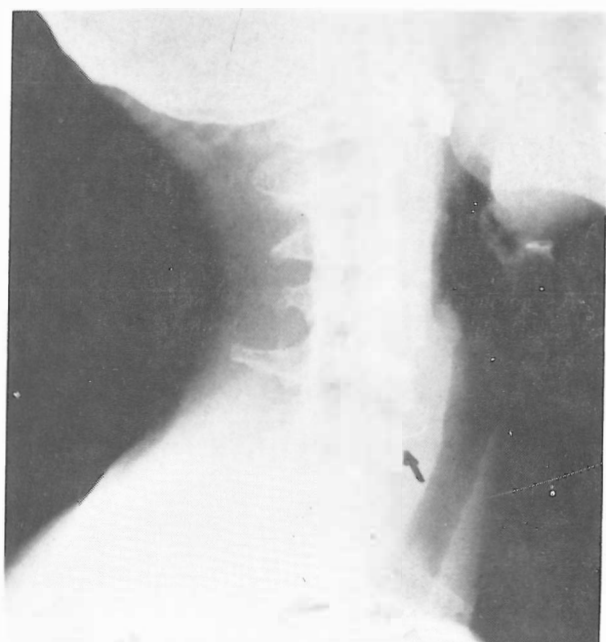


Fig. 7. Perforation of the cervical esophagus following pin ingestion.

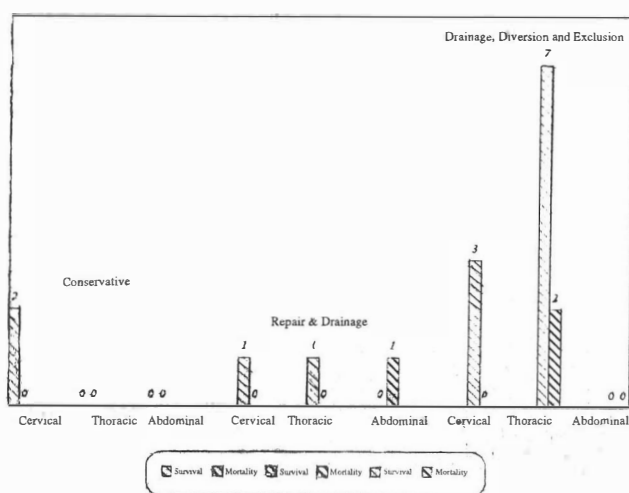


Fig. 8. Outcome of esophageal injuries related to mode of therapy.

approach included the use of antibiotics, intravenous hydration, and nasogastric suction. One patient was placed on hyperalimentation. She developed perforation secondary to iatrogenic manipulation. The diagnosis was made four hours after endoscopy. She was discharged after seventeen days, only to develop an esophagocutaneous fistula two months later. The fistula healed following drainage and debridement. The other patient had a perforation due to foreign body ingestion (a pin) (Fig. 7). Therapy was uncomplicated.

The average time lapse between the incident and ini-

tiation of therapy was 50 hours. The average hospital stay was 17 days and was associated with no mortality.

(b) Repair and drainage: 3 patients underwent suture closure of perforations with drainage. This group consisted of one patient with a cervical perforation due to a stab wound, another patient with a thoracic esophageal perforation following blunt trauma, and the only case of abdominal esophageal perforation, which was caused by a gun-shot wound.

The average period between perforation and treatment was 15 hours, and the average length of hospital stay was 27 days with a mortality rate of 33%.

Primary closure was performed either as a single or double layer in association with chest tube and Penrose drainage. One patient had a buttressing procedure with pleural flap. In one case a jejunostomy was performed for feeding purposes. There was one death in the repair and drainage group, occurring in the patient with perforation of the intra-abdominal esophagus and associated liver and stomach ruptures. He developed postoperative suture line leakage and died after a series of septic and hemorrhagic complications.

(c) Drainage, diversion and exclusion: 12 patients were treated with drainage, diversion and exclusion, including one patient with a perforation secondary to endoscopy, and one perforation due to Heller's myotomy. The non-iatrogenic group included 5 patients with perforations caused by missiles, 4 cases of perforation following foreign body ingestion, and one case of Boerhaave's syndrome.

The average interval between perforation and therapy was 95 hours with an average hospital stay of 29 days, and a 17% mortality.

Of the two patients who died in the drainage, diversion and exclusion group, one had Boerhaave's syndrome with thoracic esophageal perforation in whom an absorbable ligature was applied above the cardia, in addition to drainage and nasogastric suction. He developed pneumonia, significant arrhythmia and hemorrhagic complications, and died of multiple organ failure. The second death occurred in a 71 year old man with foreign body ingestion who developed acute renal failure. The 10 survivors included 3 patients with cervical perforations caused by missiles. Tube jejunostomy was performed for feeding purposes in 2 cases, associated with tube gastrostomy for gastric decompression in one patient. 2 patients underwent neck exploration and cervical esophagostomy which was double barrel in one case and distal end closure - proximal end esophagostomy in the other patient. A feeding tube was passed through the distal end of the esophagus in the patient with a double barrel esophagostomy.

All had diversion of secretions by nasal intubation. 2 patients required a tracheostomy because of associated injury of the trachea. One had a thyroid laceration and underwent thyroid debridement. One patient had a retained fragment in the mediastinum and developed mediastinitis which was controlled. The remaining 7 survivors had thoracic esophageal perforations. All of them underwent closed thoracotomy for pleural drainage. They had a feeding jejunostomy and nasogastric catheter, positioned proximal to the area of rupture, for suction of secretions. Distal end closure - proximal end cervical esophagostomy with associated gastrostomy for gastric decompression was performed in one case. The esophagus was also sutured at the cardia. Transesophageal mediastinal irrigation was accomplished in 6 patients in the drainage and diversion group, including the 2 expired cases. 2 patients whose esophageal perforations had been caused by missiles, had associated multiple abdominal visceral lacerations and underwent several operations. They recovered. One patient, a 16 year old boy with a retained foreign body and a seven day delay in diagnosis, developed septic shock and respiratory distress syndrome. He was treated successfully. A 65 year old man who had thoracic esophageal perforation due to foreign body ingestion, returned 10 days after discharge with a recurrence of symptoms. Esophagography revealed a perforation at the same location. The previous diversion and drainage procedures were repeated. He recovered after 7 days of hospital stay. In 3 patients with perforations caused by Heller's myotomy, endoscopy and retained foreign body, the convalescence period was uneventful.

Drainage and diversion with or without exclusion was performed in 3 patients with cervical perforations with no mortality, and in 9 patients with thoracic perforations with 2 deaths (Fig. 8).

Factors correlated with mortality rate

The overall mortality rate in this group of 17 esophageal perforations was 18% (3 patients). All of the patients had the diagnosis of esophageal perforation correctly made during their hospital stay.

The mortality rate related to primary repair was 33% (1 of 3 patients), to diversion, drainage and exclusion 17% (2 of 12 patients), and to conservative management 0% (0 of 2 patients).

The cause of perforation also affected the outcome after treatment. Perforations caused by external trauma resulted in a mortality rate of 13% (1 of 8 patients), by foreign body ingestion 20% (1 of 5 patients), by spontaneous perforation 100% (1 patient), and by iatrogenic perforation 0% (0 of 3 patients).

Only one patient in this study had underlying esophageal disease; a 7 year old girl with achalasia who de-

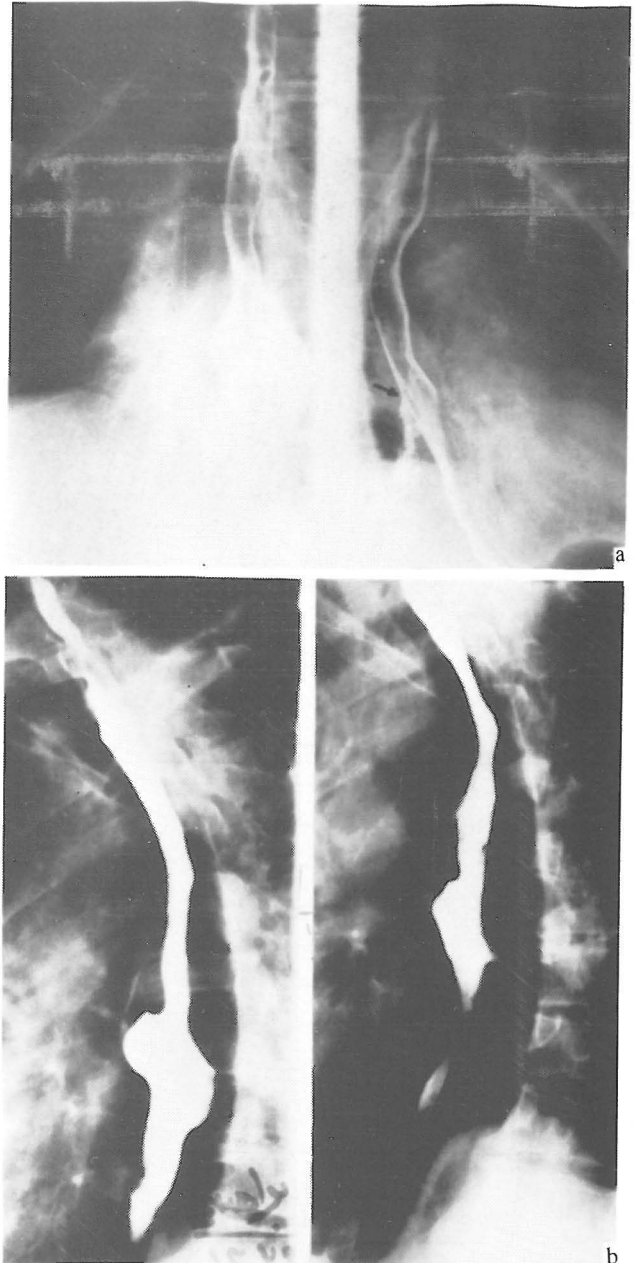


Fig. 9-a,b. Perforation of the esophagus secondary to endoscopy and formation of mediastinal abscess without mediastinitis and without involvement of the pleural spaces; initial esophagogram shows localized extravasation of contrast media into the mediastinum (a); esophagogram of the same patient 1 year later (b). Recovery without surgical intervention.

veloped perforation after Heller's myotomy and recovered uneventfully. For this reason, the influence of underlying esophageal disease on the outcome of treatment cannot be assessed.

The time lapse between the occurrence of the perforation and surgical intervention could have a profound

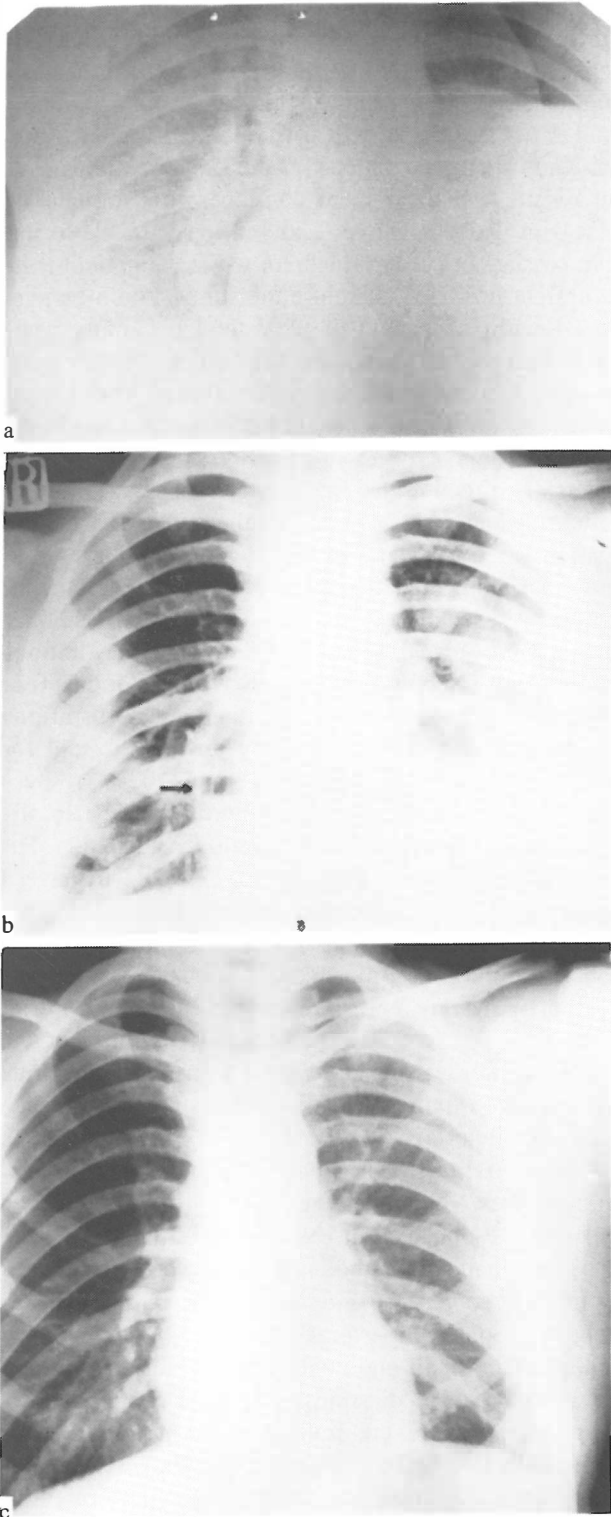


Fig. 10-a,b,c. Pyothorax and purulent pericarditis secondary to esophageal perforation. Admission chest radiograph shows large hydropneumothorax on the left (a). Erect chest x-ray of the same patient after drainage of the left and right pleural cavity. Note air-fluid level in the pericardial sac (purulent pericarditis) (b). Chest x-ray of the same patient 1 year after discharge from the hospital (c).

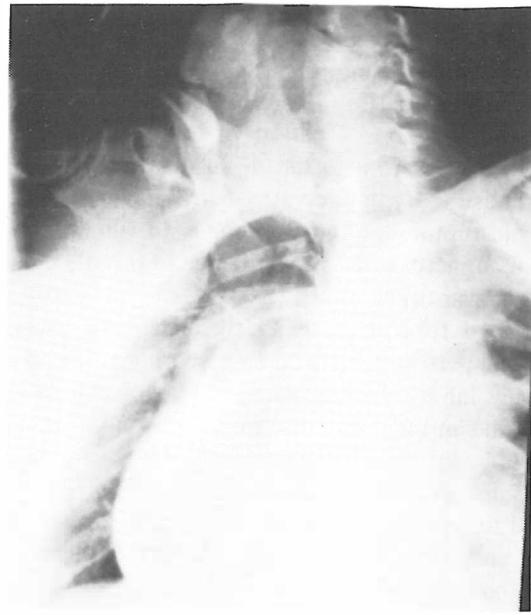


Fig. 11. Contrast swallow roentgenogram of a 35 year old female with penetrating trauma to the chest. Note extravasation of contrast media into the pericardial sac.

influence on morbidity and mortality. In our series, the mortality rate of patients treated within 24 hours of perforation was 40% (2 of 5 patients) versus 8% (1 of 12 patients) for patients managed with a delay of more than 24 hours.

The anatomic location of perforation divided the results of treatment into three groups: cervical perforations with a mortality rate of 0% (0 of 6 patients), thoracic perforations, 20% (2 of 10 patients), and abdominal perforation, 100% (1 patient).

Because of the small number of patients involved, these proportions may not be entirely accurate.

DISCUSSION

Several factors account for the increasing incidence of perforation of the esophagus. The importance of the physician's cognizance of the disease is one factor; another is increased instrumentation for diagnostic or therapeutic purposes.

The most common cause of esophageal perforation is instrumentation.³⁶ Frequent use of upper gastrointestinal endoscopy has led to an increase in the actual number of perforations. Katz² reported a perforation rate of 0.074% with the rigid esophagoscope and 0.093% with the fiberoptic esophagoscope, representing no significant improvement in safety with the use of fiberoptic instruments.

Esophageal perforation due to external blunt trauma is an exceedingly rare injury with an incidence of

0.001%. The most common cause is a violent high speed vehicular accident, but it can occur from minor trauma. The most common site is the cervicothoracic esophagus proximal to the carina.⁵ Because of the relatively well protected location of the esophagus, penetrating injuries are also rare.⁴⁵ In this review perforations caused by penetrating trauma superseded iatrogenic rupture of the esophagus in frequency; the result of an increase in the incidence of missile wounds during the war time.

Retained foreign bodies are a frequent cause of esophageal perforation. In adults, wearing artificial dentures may inhibit feeling an object before swallowing and thus be an indirect cause of swallowing or inhaling a foreign body. Swallowing a piece of artificial denture also occurs. Severe perforations can be caused by attempted removal of foreign bodies, either by a poorly trained endoscopist or by one who tries to push the foreign body ahead of the endoscope into the stomach too vigorously.¹⁶

Spontaneous perforation of the esophagus is being reported with greater frequency, most probably not because the incidence is actually increasing, but because the condition is more generally recognized. This term has been used in the literature to include all perforations involving the entire thickness of the esophageal wall, whenever perforation was associated with forceful or prolonged emesis. Many other causes have been reported: heavy lifting, defecation, seizures, forceful childbirth, and even forceful swallowing.⁶⁻⁴⁰ Factors concerned in spontaneous rupture of the esophagus, as described by Abbott and colleagues¹ are: (1) increased intraluminal pressure, (2) pre-existing esophageal disease, and (3) neurogenic causes of perforation.¹⁴⁻³³ Each of these factors can cause spontaneous rupture independent of the other, but they are commonly combined in an individual patient. In a minority of patients no cause can be found.

The site of rupture in Boerhaave's syndrome has been consistently identified as the left posterolateral aspect of the esophagus, just above the diaphragm.⁹⁻²⁸ The etiology has been attributed to an anatomic weakness in the area resulting from the reduced number and size of longitudinal smooth muscle fibers, and from the entrance of nerves and vessels into the esophageal wall.

The diagnosis of esophageal perforation begins with awareness of this condition. The physician can then proceed quickly and logically to determine its presence or absence. Delay in diagnosis is further fostered by the variety of acute thoracic and abdominal conditions which may present in a similar manner.

Early in the course of an esophageal perforation, the diagnosis may only be suspected from a characteristic history. However, once mediastinitis becomes estab-

lished, chest or abdominal pain, dyspnea, fever, hydropneumothorax or subcutaneous emphysema are highly suggestive of an esophageal rupture. These symptoms and signs demand that an esophagography using either Gastrografin or barium be performed. A repeat study should be obtained if the first one yields normal results and the patient continues to complain of chest pain. False-negative results may occur due to the rapid passage of contrast medium while the patient is in the upright position. Therefore the study should be performed with the patient in the lateral decubitus position.¹⁵ Esophagoscopy may be used when contrast studies fail to demonstrate the perforation.¹⁷ Endoscopic procedures are also indicated in perforations caused by a retained foreign body.³⁹

Factors affecting the outcome of esophageal rupture include the age and general health of the patient, the location, size, and cause of the perforation, the interval between rupture and treatment, the type of treatment, and the presence of pre-existing esophageal disease.¹⁷

In a report by Michel et al.,³⁷ iatrogenic perforations resulted in a mortality rate of 34%, foreign bodies 0%, external trauma 14%, and spontaneous perforations 36%. Our results were completely different except for external trauma (0%, 20%, 13%, and 100%, respectively). As can be seen, reported mortality rates for different causes of esophageal perforation vary greatly. Patients with Boerhaave's syndrome, expected to have a higher mortality rate, do better in some studies.²³⁻⁴⁷ This variation does not allow us to reach a definite conclusion concerning the influence of various causes of perforation on the outcome, in relation to each other.

In the present study, perforations in the thoracic esophagus were associated with a higher mortality rate than cervical ruptures. This finding is supported by data from other reports.⁷⁻¹⁸

The mortality risk in a patient with esophageal perforation rises with advancing age¹⁸ and the presence of underlying esophageal disease.³⁷ The influence of time lapse and treatment method is discussed below.

In this report the guidelines followed for management of esophageal perforations were: (1) conservative treatment for small and contained perforations without any evidence of mediastinitis or pleural contamination, (2) primary closure and drainage performed in cases of perforation diagnosed within 24 hours of occurrence, and (3) drainage, diversion and exclusion performed for esophageal perforations with a delay in diagnosis of more than 24 hours associated with mediastinal and pleural soilage. The only exception was a patient with Boerhaave's syndrome in whom the diagnosis was made within 24 hours of perforation. This patient would likely have undergone surgical repair had he not been considered a very poor surgical risk because of multiple

medical problems and advanced age.

Criteria for considering nonoperative management of esophageal perforation have been proposed by Cameron et al. as follows¹⁴: (a) the esophageal disruption should be well contained within the mediastinum or between the mediastinum and visceral lung pleura; (b) the cavity should be well drained back into the esophagus; (c) minimal symptoms should be present; and (d) there should be minimal evidence of clinical sepsis; however, in the early stage after perforation of the esophagus confirmed by extravasation of contrast material, it can be very difficult to determine whether the perforation will remain "contained" or will lead to mediastinitis and pleural contamination with subsequent respiratory failure and septic shock.³⁷

In general, perforations in the neck, which are better tolerated than those located in the thorax or abdomen, can often be managed nonoperatively.¹⁸ When the diagnosis was made early, we reserved nonoperative therapy for cervical perforations accompanied by only mild symptoms and a small (contained) leak evident on the esophagogram. In cases with late diagnosis, only one patient with cervical esophageal perforation met the criteria for conservative management. With thoracic perforations, when the diagnosis is made late, the extent of the infection is often evident and decisions regarding treatment may be simpler than early after the perforation. In cases of thoracic esophageal perforation with delayed diagnosis, mild signs of infection and a small leak, nonoperative treatment is acceptable. The same is true for early diagnosis of cervical perforations when symptoms are minimal²² (Fig. 9).

There is no role for nonoperative treatment in traumatic esophageal perforations, regardless of location, because the wounding instrument disrupts the tissue planes which might have otherwise contained the spread of infection.¹⁸

The role of antibiotic therapy and intravenous hyperalimentation, as the main aspects of conservative management, should be emphasized. Gentamicin, clindamycin and penicillin can eliminate all of the aerobes and anaerobes that are encountered in the oral cavity and gastrointestinal tract, and this antibiotic combination is the regimen of choice.¹¹ Intravenous hyperalimentation is important in placing the patient in positive nitrogen balance so that the infection can be more readily controlled and wound healing encouraged.

Primary closure is the ideal treatment when the patient is in good health, there is no underlying esophageal disease, and the perforation is discovered early.¹⁸ This characterizes the average patient whose esophageal perforation follows external trauma. The results of numerous studies show that primary suture repair of esophageal perforations yields the most favorable re-

sults in early diagnosed cases.^{7,10,13,17,37} The high mortality rate (33%) related to primary repair in proportion to other treatment methods (0% for conservative and 17% for drainage, diversion and exclusion) in this review is due to the small number of patients (3 patients) who underwent operation, and is not statistically significant.

If primary closure can be performed, the repair site should be buttressed, if possible, to prevent subsequent leak at the suture line. The tissue flaps used for buttressing include the pericardium, diaphragm, intercostal muscles, stomach wall, parietal pleura, lung and sternocleidomastoid muscle.^{3,17,36} Closure of any perforation of the thoracic esophagus should be supplemented by draining the mediastinum and pleural cavity. In addition, a gastrostomy tube for gastric drainage instead of an indwelling nasogastric catheter with its attendant pulmonary hazards, and a feeding jejunostomy should be established in critically ill patients.

The presence of an obstructing lesion of the esophagus (e.g., cancer, hiatal hernia with stricture, postoperative stenosis) requires relief of the obstruction for successful treatment of the perforation. In these situations, immediate esophagectomy, resecting both the perforation and the original obstructing lesion, is better than relying on drainage or repair alone.²⁴

Four principal options are available when more than 24 hours has elapsed after the perforation, as occurred in 70% of the patients in our series: (1) continuation of nonoperative treatment, if the conditions listed above prevail; (2) repair and reinforcement with drainage; (3) an esophageal exclusion procedure in the face of severe pleuromediastinal infection; or (4) irrigation and drainage of contaminated tissue with esophageal and gastric decompression via a nasogastric tube and tube gastrostomy, leaving the esophageal tear to heal spontaneously.

Some authors⁴⁴ believe that early suture closure and drainage should be performed in all patients with esophageal perforation, irrespective of the time interval following perforation. These authors advocate esophageal exclusion and diversion in continuity, in addition to closure after debridement, drainage, nutritional support, and antibiotic therapy for esophageal perforations that are diagnosed late. Their method of treatment involves placing an absorbable ligature around the esophagus above the cardia in order to prevent gastroesophageal reflux that might interfere with healing.⁸⁻¹² T-tube cervical esophagostomy plus absorbable ligature applied to the cervical esophagus distal to the esophagostomy are added to the above method by Chang et al.¹²

Miscellaneous techniques of exclusion of the esophagus are used in the treatment of esophageal per-

forations with delayed diagnosis and a very large perforation.³ Johnson and co-workers²⁶ recommend complete exclusion of the esophageal perforation by suture closure of the esophagus at the esophageal perforation by suture closure of the esophagus at the cardia and cervical esophagostomy with closure of the distal end. The technique was modified by Menguy³⁵ and later Urschel and colleagues⁴⁸ who placed a tape around the cardia to prevent reflux and performed a loop cervical esophagostomy in order to divert oropharyngeal secretions. Nevertheless, these techniques necessitate a second-stage operation for reconstruction or removal of the esophageal tape after healing. The method recommended by Lee et al.³¹ is the use of a T-tube as a splint and 1-0 chromic catgut tie restriction to prevent drainage of saliva to the lower esophagus. The catgut tie will gradually lose its tensile strength and be absorbed in two or three weeks, after which the esophageal T-tube can be removed easily and without the need for a second operation. The reported results of these procedures have not been uniformly satisfactory. In a compilation of published reports on the results of these procedures,³⁵ 58 patients treated with an exclusion-diversion procedure had a 35% mortality rate and 22 patients treated with T-tube, a 36% mortality rate. Our experience with exclusion-diversion procedures had better results (25% mortality rate, 1 of 4 patients).

When the diagnosis is made late, the goal of therapy is control of sepsis. This can be achieved by adequate drainage of the pleura and mediastinum via a closed thoracotomy in addition to diverting esophageal and gastric secretions through nasogastric tube suction and decompression tube gastrostomy. This treatment method does not carry the risks and complications of major operations needed for exclusion and suture repair of late diagnosed perforations. A feeding tube jejunostomy should be performed for the adequate nutritional support that is essential for a successful outcome. Transesophageal mediastinal irrigation, along with the instillation of high concentrations of antibiotic at the site of perforation, helps to control infection in a shorter period of time, thus hastening spontaneous healing of the perforation. In the present study, this treatment method had the most favorable outcome with a mortality rate of 13% which is lower than previously reported rates. Sawyers and colleagues⁴⁴ reported 40%, and Flynn et al.¹⁸ and Goldstein and associates²² a rate of 29%.

Early recognition of the perforation is regarded as all-important, and a 3-5 fold increase in mortality rate is reported in late diagnosed cases.³²⁻⁴⁴ In the present series overall mortality rate was conversely influenced by the lag between perforation and therapy of choice, and survival was significantly better after a delay of more

than 24 hours (40% vs. 8%). This paradoxical result may be due to the small group of patients, but another possibility is the excellent outcome of the diversion, drainage and exclusion method performed in "late" cases. Despite the overall seriousness of esophageal perforation, the present review documents a trend toward improved survival. This trend appears to be related to more effective and less aggressive treatment modalities in late diagnosed cases.

The retrospective nature of the study design and the small number of cases in this series do not allow firm recommendations on how patients with a perforation of the esophagus should be treated. Yet we feel that there are grounds to put great emphasis on wide drainage and irrigation of the mediastinum and pleural cavity in addition to diverting esophageal and gastric secretions in late diagnosed patients with cervical or thoracic esophageal perforation associated with pleural and mediastinal contamination.

Finally, despite advances in management, it appears certain that the treatment of esophageal perforation will remain a challenge, as the number of patients seen each year is increasing.

REFERENCES

1. Abbott OA, Mansour KA, Logan WD, et al: Atraumatic so-called "spontaneous" rupture of the esophagus: a review of 47 personal cases with comments on a new method of surgical therapy. *J Thorac Cardiovasc Surg* 59: 67, 1970.
2. Attar S, Hankins JR, Suter CM, Coughlin TR, Sequeira A, McLaughlin JS: Esophageal perforation: a therapeutic challenge. *Ann Thorac Surg* 50: 45, 1990.
3. Barlow CW, Schein M: Primary sternocleidomastoid muscle flap in emergency reconstruction of traumatic oesophageal defect: case report. *Eur J Surg* 157: 419, 1991.
4. Barrett NR: Report of a case of spontaneous perforation of the esophagus successfully treated by operation. *Br J Surg* 35: 216, 1947.
5. Beal I, Pottmeyer EW, Spisso JM: Esophageal perforation following external blunt trauma. *J Trauma* 28: 1425, 1988.
6. Beal JM: Spontaneous rupture of the esophagus. *Arch Surg* 59: 710, 1949.
7. Berry BE, Ochsner JL: Perforation of the esophagus: a 30 year review. *J Thorac Cardiovasc Surg* 65: 1, 1973.
8. Bladergroen MR, Lowe JE, Postlethwait RW: Diagnosis and recommended management of esophageal perforation and rupture. *Ann Thorac Surg* 42: 235, 1986.
9. Blichert-Taft M: Spontaneous oesophageal rupture. *Scand J Thorac Cardiovasc Surg* 5: 111, 1971.
10. Brewer LA, Carter R, Mulder GA, Stiles QR: Options in the management of perforation of the esophagus. *Am J Surg* 152: 62, 1986.

11. Cameron JL, Kieffer RF, Hendrix Tr, Mehigan DG, Baker RR: Selective nonoperative management of contained intrathoracic esophageal disruptions. *Ann Thorac Surg* 27: 404, 1979.
12. Chang CH, Lin PJ, Chang JP, Hsieh MJ, Lee MC, Chu JJ: One stage operation for treatment after delayed diagnosis of thoracic esophageal perforation. *Ann Thorac Surg* 53: 617, 1992.
13. Cohn HE, Hubbard A, Patton G: Management of esophageal injuries. *Ann Thorac Surg* 48: 309, 1989.
14. Cushing H: Peptic ulcers and interbrain. *Surg Gynecol Obstet* 55: 1, 1932.
15. DeMeester TR: Perforation of the esophagus. *Ann Thorac Surg* 42: 231, 1986.
16. Derbes VJ, Mitchell RE: Hermann Boerhaave's (1) *Atrocis, nec Descripti prius, Morbi Historia*; (2) the first translation of the classic case report of rupture of the esophagus, with annotations. *Bull Med Libr Assoc* 43: 217, 1955.
17. Finley RJ, Pearson FG, Weisel RD, Todd Tr, Ilves R, Cooper J: The management of nonmalignant intrathoracic esophageal perforation. *Ann Thorac Surg* 30: 575, 1980.
18. Flynn AE, Verrier ED, Way LW, Thomas AN, Pellegrini CA: Esophageal perforation. *Arch Surg* 124: 1211, 1989.
19. Frink NW: Spontaneous rupture of esophagus: report of a case with recovery. *J Thorac Surg* 16: 291, 1947.
20. Froggatt DI, Gunning AJ: Treatment of esophageal perforation. *Thorax* 21: 524, 1966.
21. Gardner CM: "Spontaneous" rupture of the esophagus. *Arch Surg* 59: 710, 1949.
22. Goldstein LA, Thompson WR: Esophageal perforations: a 15 year experience. *Am J Surg* 143: 495, 1982.
23. Graeber GM, Niezgoda JA, Albus RA, Burton NA, Collins GJ, Lough FC, Zajchuk R: A comparison of patients with endoscopic esophageal perforations and patients with Boerhaave's syndrome. *Chest* 92: 995, 1987.
24. Hendren WH, Henderson BM: Immediate esophagectomy for instrumental perforation of the thoracic esophagus. *Ann Surg* 168: 997, 1968.
25. Isaguirre SFS, Haggerty JT, Eckert G: Spontaneous rupture of the esophagus. *Surgery* 67: 607, 1970.
26. Johnson J, Schwegman CW, Kirby CK: Esophageal exclusion for persistent fistula following spontaneous rupture of the esophagus. *J Thorac Surg* 32: 827, 1956.
27. Katz D: Morbidity and mortality in standard and flexible gastrointestinal endoscopy. *Gastrointest Endosc* 15: 134, 1969.
28. Keighley MRB, Girdwood RW, Ionescu MI, et al: Spontaneous rupture of the esophagus. *Br J Surg* 59: 649, 1972.
29. Kinsella TJ, Morse RW, Hertzog AJ: Spontaneous rupture of esophagus. *J Thorac Surg* 17: 613, 1948.
30. Kraeft NH, Hughes FA: Rupture of the normal esophagus: report of a case with recovery following unusual complication. *Surgery* 31: 219, 1952.
31. Lee YC, Lee ST, Chu SH: New technique of esophageal exclusion for chronic esophageal perforation. *Ann Thorac Surg* 51: 1020, 1991.
32. Lyons WS, Seremetic MG, DeGuzman VC, Peabody JW: Ruptures and perforations of the esophagus: the case for conservative supportive management. *Ann Thorac Surg* 25: 346, 1978.
33. MacIver IN, Smith BJ, Tomlinson BE, Whitey JD: Rupture of the oesophagus associated with lesions of central nervous system. *Br J Surg* 43: 505, 1956.
34. Maggiore E, Cavaliere F, Cascone C, Ofria F, Maggiore D, Francioni F, Cerulli G: *Larottura spontanea dell' esofago*. *Minerva Chir* 46: 617, 1991.
35. Mengury R: Near-total esophageal perforation: report of a case. *Ann Surg* 173: 613, 1971.
36. Michel L, Grillo HC, Malt RA: Esophageal perforation. *Ann Thorac Surg* 33: 203, 1982.
37. Michel L, Grillo HC, Malt RA: Operative and nonoperative management of esophageal perforations. *Ann Surg* 194: 57, 1981.
38. Mitchell RE, Derbes VJ, Akenhead WR: Rupture of the esophagus: two instances of a hitherto undescribed complication of status asthmaticus. *Ann Allergy* 13: 15, 1955.
39. Pairolero PC, Trastek VF, Payne WS: Esophageal perforation. In: Schwartz SI, Shires GT, et al (eds.), *Principles of Surgery*. New York: McGraw-Hill Book Company, pp. 1145-1150, 1989.
40. Raffle EJ: Spontaneous rupture of the esophagus and bronchial asthma. *Lancet* 1: 938, 1958.
41. Rosoff L, White EJ: Perforation of the esophagus. *Am J Surg* 128: 207, 1974.
42. Sandrasagra FA, English TAH, Milstein BB: The management and prognosis of oesophageal perforation. *Br J Surg* 65: 629, 1978.
43. Santos GH, Frater RWM, et al: Transesophageal irrigation for the treatment of mediastinitis produced by esophageal rupture. *J Thorac Cardiovasc Surg* 91: 57, 1986.
44. Sawyers JL, Lane CE, Foster JH, Daniel RA: Esophageal perforation: an increasing challenge. *Ann Thorac Surg* 19: 233, 1975.
45. Shama DM, Odell J: Penetrating neck trauma with tracheal and oesophageal injuries. *Br J Surg* 71: 534, 1984.
46. Skinner DB, Little AG, DeMeester TR: Management of esophageal perforation. *Am J Surg* 139: 760, 1980.
47. Triggiani E, Belsey R: Oesophageal trauma: incidence, diagnosis, and management. *Thorax* 32: 241, 1977.
48. Urschel HC, Razzuk MA, Wood RE, et al: Improved management of esophageal perforation: exclusion and diversion in continuity. *Ann Surg* 179: 587, 1974.

