

Case Reports

A VERY RARE CASE OF FOREIGN BODY IN THE CORONARY ARTERY

FEREIDOON NOOHI, M.D., NADER GIVTAJ, M.D., AND
MOHAMMADREZA SAIDI, M.D.

*From the Cardiovascular Research Center, Shahid Rajai Heart Hospital,
Tehran, Islamic Republic of Iran.*

ABSTRACT

A 56 year old man was admitted to our center for further evaluation of typical chest pain of ten months' duration. Selective coronary angiography was done and showed a sewing needle-like foreign body which was lying in very close proximity to the anatomic location of the right coronary artery.

At operation two pieces of sewing needles were removed, one from the coronary sinus and the other from the right coronary artery before the crux.

MJIRI, Vol. 10, No. 2, 165-167, 1996.

INTRODUCTION

Foreign bodies in cardiac chambers, myocardium and pericardium have been rarely reported. However intracoronary foreign bodies are very rare and, with the development of invasive procedures and interventional cardiology, are most often iatrogenic.

Case report

A 56 year old man was admitted to the cardiovascular center for further evaluation of typical chest pain of ten months' duration. He had a history of insulin-dependent diabetes mellitus. There was no remarkable abnormal finding on physical exam except for an old small scar at the left sternal border (Fig. 1) which was ignored before coronary angiography.

The patient recalled that he had an automobile accident 35 years ago which led to transient unconsciousness and also to chest trauma. At that time he was a soldier and the identification card of the soldier was customarily attached to the left side of the military uniform by a sewing needle.

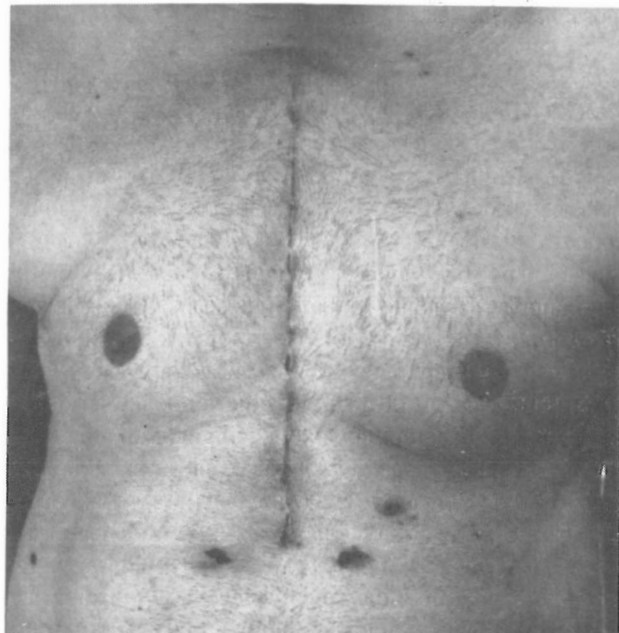


Fig. 1. Postoperative photograph of the patient. Note old left parasternal scar.

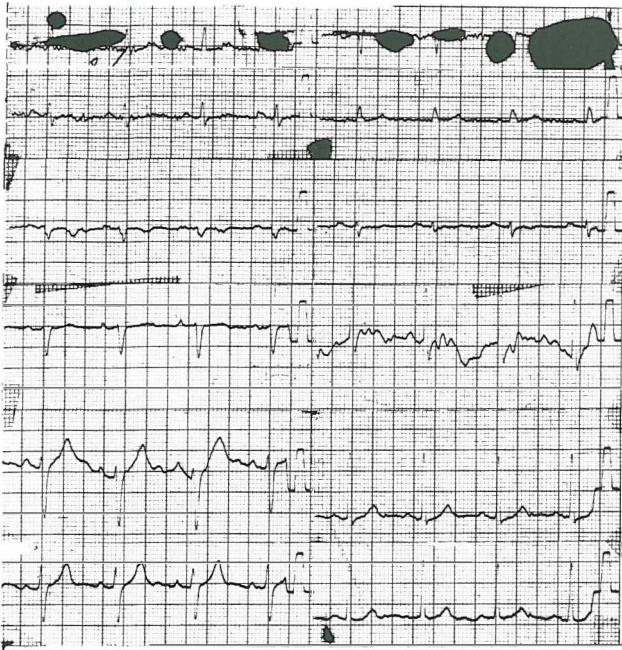

Fig. 2. The patient's ECG (normal).

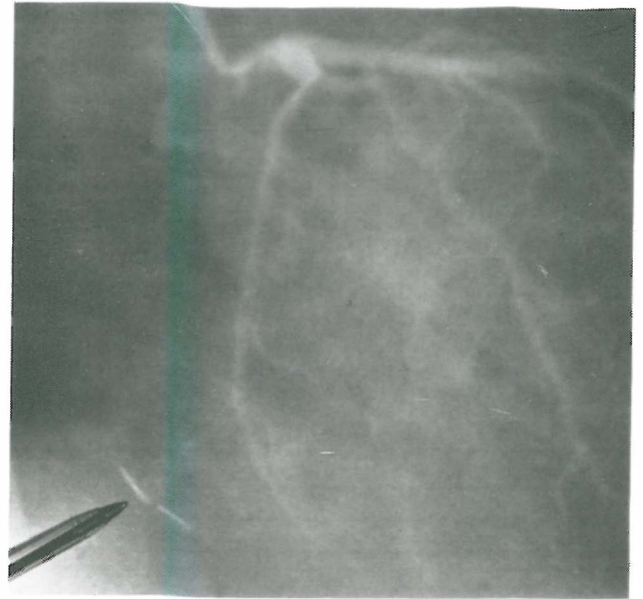


Fig. 4. Left coronary angiogram demonstrating normal anatomy. Note sewing needle.

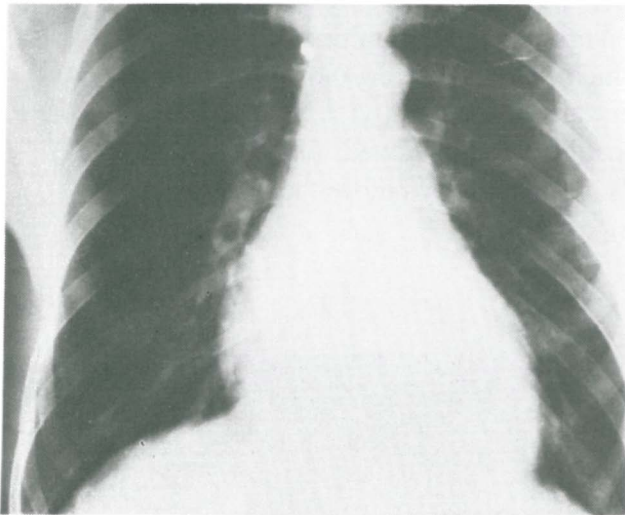


Fig. 3. Preoperative chest X-ray.

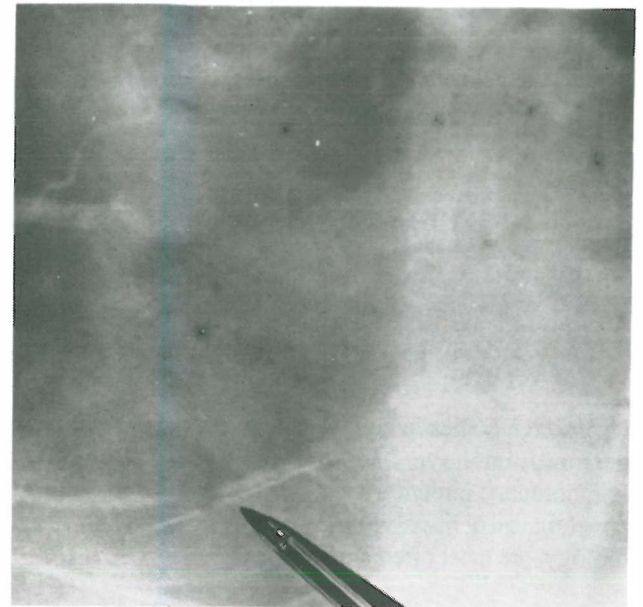


Fig. 5. Right coronary angiogram demonstrating significant lesion and foreign body.

The ECG was normal (Fig. 2). Chest x-ray revealed a mildly increased cardiothoracic ratio and no evidence of a sewing needle (Fig. 3). Echo findings showed: LVEDd 5.3, LVESd 3.8, and EF: 45%.

Selective coronary angiography and left heart catheterization showed mild left ventricular enlargement and slightly decreased contractility.

Ejection fraction was about 45 percent. Left coronary angiogram showed no significant lesion (Fig. 4). Right coronary angiogram showed a significant stenosis before the crux associated with foreign body (Fig. 5).

The patient underwent operation for CABG and removal of the foreign body. There were two pieces of sewing

needles, one of them in the RCA and one in the coronary sinus, both of which were removed successfully. There was adhesion at the site of foreign bodies to the adjacent pericardium which was leading to RCA occlusion. The patient was discharged from the hospital in good general condition.

DISCUSSION

Although foreign body in the coronary artery is very

uncommon, it is usually a complication of cardiac catheterization, coronary angiography and angioplasty.¹⁶

Among the intracoronary foreign bodies, guidewire fracture during angioplasty is the most common. Coronary stent migration and paradoxical embolization of a catheter fragment to a coronary artery as well as balloon rupture in the coronary artery have also been reported.^{2,5-7,9-12,14-15}

In the literature review from 1970 to 1994, there was only one case report of a sewing needle in the LAD of a 45 year old patient which was discovered at autopsy.⁴

Therefore this case, which is one of the rarest reported cases of intracoronary foreign bodies, indicates that penetrating objects such as sewing needles can migrate to the heart and even to the coronary artery and lead to non-atherosclerotic coronary artery disease and angina pectoris,

REFERENCES

1. Eeckhout E, Stauffer JC, Goy JJ: Retrieval of a migrated coronary stent by means of an alligator forceps. *Cathet Cardiovasc Diagn* 30(2): 166-8, 1993.
2. Cantarelli MJ, de-Paola A-de-A, Alves CM, Souza JA, Castello Junior HJ, Hermann JL, Lamounier EN, Guimarses RF, Portugal OP, Martinez Filho EE: Percutaneous retrieval of intravascular foreign bodies. *Arq Bras Cardiol* 60(3): 171-5, 1993.
3. Veldhuijzen FL, Bonnier HJ, Michels HR, el Gamal MI, Van Gelder BM: Retrieval of undeployed stents from the right coronary artery: report of two cases. *Cathet Cardiovasc Diagn* 30(3): 245-8, 1993.
4. Istvan B, Miklos S: Foreign body causing coronary artery occlusion. *Morphol Igazsagugyi Orv Sz* 16(3): 184-8, 1976.
5. Hofling B, Erdmann E: Extraction of a broken intracoronary PTCA guide wire perforating the circumflex artery, using a Dotter retrieval catheter. *Z Kardiol* 73(10): 663-5, 1984.
6. Dias AR, Garcia DP, Arie S, da Luz P, Jatene AD: Fracture and intracoronary retention of a guidewire catheter in percutaneous transluminal angioplasty. A case report. *Arq Bras Cardiol* 53(3): 165-6, 1989.
7. Guenot C, Donzeau Gouge P, Desnos M, Cristofinin P, Hagege A, Guerot C: Intracoronary fracture of a guidewire tip in percutaneous coronary angioplasty. *Arch Mal Coeur* 82(3): 405-7, 1989.
8. Klys HS, Calmon AP, DeGiovanni JV: Paradoxical embolisation of a catheter fragment to a coronary artery in an infant with congenital heart disease. *Br Heart J* 66(4): 320-1, 1991.
9. Yajima T, Sakakibara I, Ida T, Tsunemoto H, Ootaki E, Suzuki S: Entrapment of broken guidewire in the right coronary artery during percutaneous transluminal coronary angioplasty. *Nippon Kyobu Geka Gakkai Zasshi* 39(9): 1813-5, 1991.
10. Savas V, Schreiber T, O'Neill W: Percutaneous extraction of fractured guidewire from distal right coronary artery. *Cathet Cardiovasc Diagn* 22(2): 124-6, 1991.
11. Krone RJ: Successful percutaneous removal of retained broken coronary angioplasty guidewire. *Cathet Cardiovasc Diagn* 12(6): 409-10, 1986.
12. Steele PM, Holmes DR Jr, Mankin H, Schaff HV: Intravascular retrieval of broken guidewire from the ascending aorta after percutaneous transluminal coronary angioplasty. *Cathet Cardiovasc Diagn* 11(6): 623-8, 1985.
13. Schrader R, Krause E, Blum U, Kober G: Rupture and fragmentation of a catheter in a calcified coronary artery stenosis. *Z Kardiol* 79(3): 199-202, 1990.
14. Mikolich JR, Hanson MW: Transcatheter retrieval of intracoronary detached angioplasty guidewire segment. *Cathet Cardiovasc Diagn* 15(1): 44-6, 1988.
15. Hartzler GO, Rutherford BD, McConahay DR: Retained percutaneous transluminal coronary angioplasty equipment components and their management. *Am J Cardiol* 1; 60(16): 1260-4, 1987.
16. Waller BF: Atherosclerotic and nonatherosclerotic coronary artery factors in AMI. In: Pepine CJ (ed): AMI. Philadelphia: FA Davis, pp. 29-104, 1989.

