

Original Articles

CEREBRAL HYDATIDOSIS: A REAPPRAISAL

BIZHAN AARABI, M.D.,
MUSA TAGHIPOUR, M.D.,
AND AHMAD KAMGARPOUR, M.D.,

From the Nemazee and Beheshui Hospitals, Shiraz University of Medical Sciences, Shiraz, Islamic Republic of Iran.

ABSTRACT

The remarkable evolution of surgical management of cerebral hydatidosis towards an earlier diagnosis and proper treatment is evident from this 22-year retrospective study of our experience with 19 cases seen at Shiraz University Medical Institutions. Both cases of iatrogenically-induced infected cysts were seen during the pre-CT era. The optimistic view of being able to remove all the cysts intact seems to be elusive because six cysts ruptured during extraction even with application of the Dowling technique. These cases were followed for a mean of 44 months and in only one case was the patient referred again with subarachnoid cysts of the lumbosacral region after two years. In six cases we had involvement of other organs also. There were two cases of multiple cysts in the brain, a case with *de novo* infection of the cyst contents, and one in which the cyst was epidural in the parieto-occipital region. One patient died pre-operatively and three were lost to follow-up; however, fifteen patients were followed for a mean of 27 months with eleven being neurologically intact and four with focal neurological deficits. One patient with a tapped cyst before extraction was readmitted two years later with paraplegia due to drop parasitic infestation of the thoracolumbar region.

MJIRI, Vol. 10, No. 1, 1-5, 1996.

INTRODUCTION

Traditionally Iran is oriented towards sheep raising for domestic meat consumption and export. Hydatidosis therefore has always been looked upon as an endemic process. For various reasons it is hard to break the life-cycle of *Echinococcus granulosus* and prevent human beings from acting as intermediate hosts. Despite this, there has been a slow but definite evolution towards better diagnosis and management of cerebral hydatidosis in this country.^{1,18-20} One of the major factors in better evaluation and surgical planning is the introduction of modern imaging

devices for accurate diagnosis and localization of single or multiple cysts.^{2,16} The major hurdles in treatment are to prevent spillage of the cyst contents in the surgical field, to be able to differentiate between the embryonal and the scolecal cysts, and to effectively treat other organ involvement. In this article we present our experience with 19 cases of cerebral hydatidosis treated in Shiraz during the past 22 years.

PATIENTS AND METHODS

From March 1970 to March 1992, nineteen patients were

treated with a diagnosis of cerebral hydatidosis at Shiraz University Medical Institutions (Nemazee and Beheshti Hospitals). There were ten female and nine male patients. Their mean age was 18 ± 10 years (range 6-45, median 16). There was no predilection for a specific region in the southern part of the country.

RESULTS

Clinical complaints and findings of the patients

Sixteen patients had headache, seven weakness of one side of the body, four visual difficulties and two major seizures as their complaint. The mean duration of symptoms was 11.6 months.

Fourteen patients showed papilledema (including five patients with decreased visual acuity due to secondary optic atrophy), and nine hemiparesis. Homonymous hemianopsia, nuchal rigidity, and a large head were noted in each of three patients. Examination was normal in one patient.

Radiological studies and cyst location

Calcification of the exocyst was not seen in our patients and information concerning splitting of the cranial sutures was not complete due to widespread application of brain CT scanning without bone windows.^{1,4,14,33} Only four patients were studied with angiography and air ventriculography; the rest of the patients had brain CT scans. Angiography typically indicated moderate to extreme shift of the cerebral blood vessels—a character which is referred to as "spider legs."⁴ Computerized tomography of the brain is preferred to every study and is only rivalled by magnetic resonance imaging. CT is usually indicative of a round cystic lesion with little enhancement of the exocyst; however, if the adventitial reaction is relatively prominent, we may see enhancement of the exocyst.^{2,11,20} A case has been reported in which a hyperdense rim was seen without calcification or enhancement.¹⁸ In one of our cases with *de novo* infection of the cyst there was enhancement of the wall of the cyst (Fig. 1). Extradural or multiple primary intradural cysts are more commonly polygonal rather than spherical^{27,35} (Fig. 2). In the only reported MR study of cerebral hydatidosis, the signal intensity of the fluid inside the cyst was very much like CSF with a fine hyper-intense rim on T2-weighted images. Ten cysts were located in the parietal lobe, four in the frontoparietal, two in the frontal and one in each of the following regions: parieto-occipital and parietotemporal. In one patient with metastatic cysts caused from a ruptured one lodged in the septum of the heart, there were at least seventeen cysts all over both hemispheres (Fig. 3).

Serologic and blood studies

Considering the diagnostic accuracy of computed tomography and magnetic resonance imaging and the fact

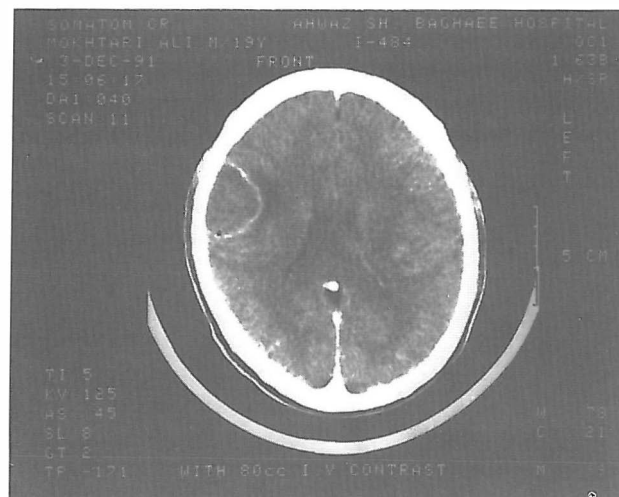

Fig. 1. Computerized axial tomography of a 22 year old man with a one year history of generalized seizure disorder, showing a cystic right fronto-parietal mass with rim enhancement which turned out to be an infected hydatid cyst.

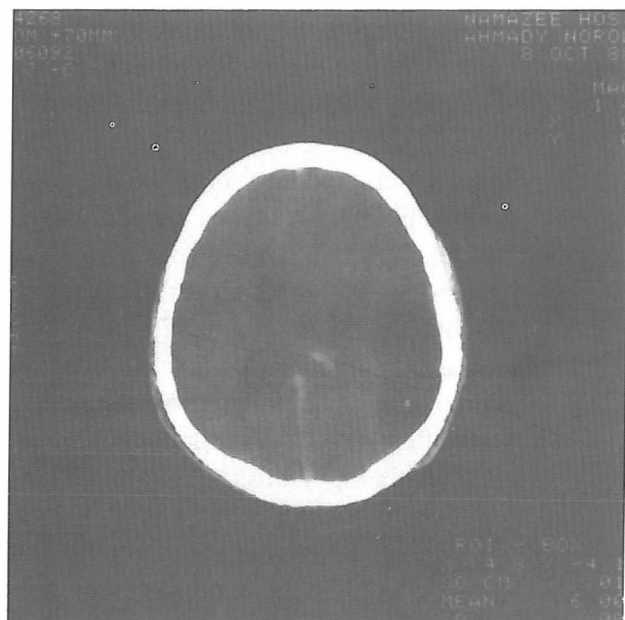


Fig. 2. Computerized axial tomography of the brain of a 35 year old man with a five month history of headache and evidence of increased ICP indicating multiple epidural hydatid cysts over the left parieto-occipital area.

that in only a minority of the primary cerebral cysts did we have other organ involvement, immunologic tests such as Casoni, Weinberg and CCIE were not used routinely. The value of serologic tests and eosinophilia is questioned in the primary infestation of cerebral hydatidosis.^{4,10,16}

Involvement of other organs

Hydatidosis is less frequently associated with other

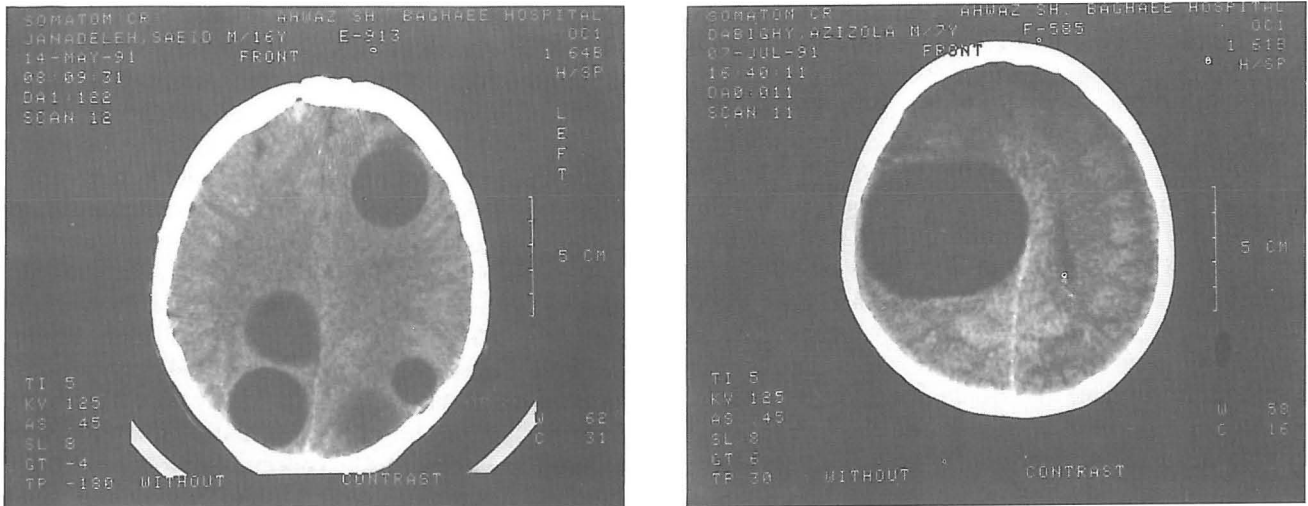


Fig. 3. Computerized axial tomography of the brain of a 14 year old boy, and a 22 year old lady with multiple widespread secondary (left) and localized primary (right) hydatid cysts of the brain.

organ infestation.^{1,4,28} In six patients there was involvement of other organs: three patients had pulmonary cysts; one isolated, one with hepatic and the last one with hepatic and renal cysts. In two patients there was isolated involvement of the liver and in the last patient a cyst was noted in the cardiac septum. The only case of metastatic cerebral hydatidosis was seen in the latter patient.

Surgical intervention

It is generally accepted that when a diagnosis of cerebral cyst is established, the ultimate goal should be to remove the cyst intact. To achieve this goal, the patient's head is correctly positioned, enabling us to take advantage of gravity. We rotated a large osteoplastic bone flap centered on the cyst. The dura would usually have very little adhesion to the cortex. However, this was not always so if there was prominent adventitial reaction. Since there was no guarantee that with even the finest dissection the endocyst would stay intact, we usually covered all the unused cortex with cottonoids, making the surgical field at any time very limited. Corticotomy was performed along one of the available sulci to unravel the cyst. With enough of the endocyst exposed, the cyst would begin to deliver itself. At this time the method used by Dowling and described by Arana-Iniguez and San Julian was used to deliver the cyst safely by injecting saline solution between the endocyst and the adventitial exocyst.^{1,4,20} When the cyst was out we would always look for daughter cysts in the bed of the original cyst. In case of rupture of the endocyst, we would limit the exposed cortex to a minimum degree and empty some of the cyst contents. Then we injected either 0.5 percent silver nitrate, 1 percent formalin or 3 percent hypertonic saline inside the cyst to kill the fertile scoleces. The rest of the cyst contents were then emptied and the endocyst removed. We used this technique in case # 9 and she has been free of recurrence for the past 11 years and only suffers from

occasional epileptic seizures.

Surgical exploration was performed in four of five patients with cysts in their livers, lungs and kidneys; simultaneously with their craniotomy in one and between 2-6 months later in three. In two patients with pulmonary, hepatic and cardiac infestation, only long-term mebendazole was used to arrest the progress of the parasite with moderate success.

Ruptured cysts

In seven patients the parasitic cyst ruptured at the time of removal. In three patients the rupture of the endocyst was inadvertent and occurred at the time of cortical dissection. The metastatic cysts numbered 17 in a fourth patient and during his third exploration one cyst ruptured. The fifth patient had numerous left parieto-occipital epidural cysts and it was impossible to keep all of them intact. The violation of the endocyst was intentional in the last two patients. In one the cyst was tapped at first before extraction of the endocyst. This patient was readmitted exactly two years later with numerous spinal subarachnoid drop metastatic cysts. In the second patient we considered a right temporoparietal arachnoid cyst (angiographic diagnosis) and the patient's cyst was shunted. This patient developed shunt infection which necessitated removal of the system and intraoperatively part of the endocyst exposed itself through a cranial burr hole. No organism was cultured from the infected cyst cavity. Except for the patient with a shunted cyst which was lost to follow-up, the rest of the patients were followed for a mean of 44 months with the only recurrence being the patient with spinal cysts described above.

Infected cysts

An infected cyst was noted in three patients. One patient (a 16 year old male) suffered from headache, hemiparesis, low visual acuity, convulsions, and a discharging sinus from

his right parietal scalp of 18 months' duration. Angiography and ventriculography revealed a right parietal mass. Around that time a general surgeon performed a burr-hole exploration of the brain of the patient. Exploration revealed remnants of an infected cyst extending from the subgaleal region through the skull and defective dura into the parietal lobe. Cultures of the cyst contents revealed coagulase positive *S. aureus*. This patient was lost to follow-up. The second patient developed an infected (sterile) cyst following a shunting procedure as described previously. The last patient (a 22 year old man) was admitted with a one year history of convulsive seizures. Brain CT revealed a ring-shaped enhancing lesion in the right fronto-parietal region (Fig. 1). Exploration revealed a superficial cortical infected hydatid cyst which was collapsed on itself and contained sterile pus. This was an example of *de novo* infection of a cerebral hydatid cyst. This patient has been followed for the past six months with no problems. Infection of cerebral hydatid cysts are not widely reported in the literature.^{4,25}

Epidural cysts

These cysts are collections of numerous daughter cysts arising from the diploë of the skull and invading the epidural space,^{6,22,33} with or without violation of the dura or brain.^{24,27} Their treatment is truly challenging and difficult, and in this regard they resemble bony cysts whereas there is exogenous vesiculation instead of single cysts.^{12,34} It is almost impossible to prevent these cysts from rupturing. In our only case with epidural hydatidosis, numerous cysts extended from the right parietal area into the epidural space of the occipital area and posterior fossa. Rupture of a few cysts during saline expulsion of the cysts was unavoidable (Fig. 2).

Follow-up of our patients

One patient died in this series pre-operatively due to uncal herniation subsequent to her generalized convulsion the night before her exploration, and three patients were lost to follow-up. At their latest follow-up (mean 27 months), eleven patients were neurologically intact. Low visual acuity, field cut, and hemiparesis were noted in each of three patients. Long-term epilepsy was observed in three patients.

DISCUSSION

From the turn of this century up to now, there has been a steady improvement in our general knowledge of the way this peculiar cestode (*Echinococcus granulosus*) behaves during its life cycle and the way it challenges the human body as an intermediate host.³² Larval infestation of human organs was much more common in the early decades of the twentieth century.^{4,5,26} In most of the reported series after the fifties, the chances of brain infestation has been approximately 2 percent,^{1-3,16} and it comprises about 1-2

percent of space-occupying lesions of the brain.^{2,16,19} In most Asian, South American and African countries, the infestation of human beings is through the domestic cycle, while in North America the sylvatic cycle is also operational.³¹ After ingestion of the parasitic rings, the eggs hatch in the duodenum and subsequently the 25 micron hexacanth embryos penetrate the portal or lymphomesenteric capillaries and are trapped in the liver in 60-70 and lung in 20 percent of the cases. The cycle is completed if the carnivore animal, such as dog or wolf, consumes the raw offal of sheep or cattle.^{4,5,16,30,31} Human involvement is usually prevalent in rural places where livestock is abundant and plenty of stray dogs wander about.^{3,5,31} In our study only three cases were from the Shiraz metropolitan area, and the rest were from small villages or towns. This endemic zoonosis seems to be more pronounced in the western part of Iran.¹ Human brain could be involved primarily via the hematogenous route by fertile embryos, or by metastatic spread when a cyst ruptures in the heart or lung. At times the cysts rupture in situ and produce several daughter cysts. Secondary cysts are less frequent and are usually acephalic and sterile.^{5,30} The majority of the cysts in the brain are single, although multiple cysts occur less frequently by primary or secondary processes.^{1,5,8,9,11,21,22,29,35} We had two such cases (one from a cyst rupture in the heart and the other probably by rupture in situ). When the embryo migrates as an embolus, it may cause infarction of that territory of the brain which at times could be fatal.^{7,29} The growth of the embryonal cyst is more pronounced in the pediatric age group and is about 9-100 mm per year.^{15,21,36} As the cyst grows, it displaces the brain; this process is so slow that the patient usually does not develop any overt lateralizing signs, but in this situation increased intracranial pressure would usually cause headache and papilledema.^{1,4,33} Less frequent findings which were also seen in our series were hemiparesis and convulsive seizures. The recent progress in the neurodiagnostics of cerebral hydatid cyst has been truly spectacular; however, neither CT nor MRI are able to tell us if the cyst is a fertile (embryonal) one or a scolecal (sterile) one. This would be of utmost importance in our expectation of future recurrence of the cyst if the cyst ruptures. Rupture of the cyst during its dissection is inevitable in a significant number of patients.^{1,6,16,17,19,21-23} Due to difficult dissection some authors have intentionally tapped the cyst before removing its cuticular wall,^{3,21,23} as was the case in two of our patients. It seems logical to conclude that since recurrence of cysts is likely to occur following rupture and medical treatment is also non-curative, the best way to eradicate this endemic zoonosis in Iran is to break the life-cycle of this cestode by what Iceland did at the turn of the century. Aside from this, a more convenient way for our country may be to prevent the accessibility of raw offal of sheep to stray dogs via strict hygienic control of city abattoirs by the government officials.^{5,31}

REFERENCES

1. Abbassioun K, Amir Jamshidi A, Rahmat H, Mehrazin M, Shakeri M, Azar M: Intracerebral hydatid cyst: a review of 22 cases. *Iranian Journal of Medical Sciences* 13: 2-9, 1986.
2. Abbassioun K, Rahmat H, Amell NO, Tafazoli M: Computerized tomography in hydatid cyst of the brain. *J Neurosurg* 49: 408-411, 1978.
3. Anderson M, Bickerstaff ER, Hamilton JG: Cerebral hydatid disease in Britain. *Journal of Neurology, Neurosurgery, and Psychiatry* 38: 1104-1108, 1975.
4. Arana-Iniguez R, San Julian J: Hydatid cysts of the brain. *J Neurosurg* 12: 323-335, 1955.
5. Ayres CM, Davey LM, German WJ: Cerebral hydatidosis: clinical case report with a review of pathogenesis. *J Neurosurg* 20: 371-377, 1963.
6. Balakrishnan D, Natarajan M: Hydatid cyst of the skull. *J Indian Med Assoc* 61: 88-91, 1973.
7. Byard RW, Bourne AJ: Cardiac echinococcosis with fatal intracerebral embolism. *Arch Dis Child* 66: 155-156, 1991.
8. Carcassonne M, Auberspy P, Dor V, et al: Hydatid cysts in childhood. *Prog Pediatr Surg* 5: 1-35, 1973 (see pp. 26-32).
9. Carrea R, Dowling E Jr, Guevara JA: Surgical treatment of hydatid cysts of the central nervous system in pediatric age (Dowling's technique). *Childs Brain* 1: 4-21, 1975.
10. Coates R, Von-Sinner W, Rahm B: MR imaging of an intracerebral hydatid cyst. *AJNR* 11: 1240-1250, 1990.
11. Demir K, Karsli AF, Kaya T, et al: Cerebral hydatid cysts: CT findings. *Neuroradiology* 33: 22-24, 1991.
12. Deve F: *L echinococcoses osseuse*. Montevideo: Monteredere & Co., pp. 236 (see pp. 30-47, 67-68), 1948.
13. Dew HR: Primary cerebral hydatid disease. *Aust NZ J Surg* 24: 161-171, 1955.
14. el-Khamlichi A, el-Ouahabi A, Amrani F, et al: Development of intracerebral hydatid cyst evaluated with x-ray computed tomography. A case report. *Neurochirurgie* 36: 312-314, 1990.
15. Fabiani A, Trebini F, Torta R: Brain hydatidosis: report of two cases. *Journal of Neurology, Neurosurgery, and Psychiatry* 43: 91-94, 1980.
16. Geiger LE: Hydatid cyst of the brain: report of a case. *J Neurosurg* 23: 4446-9, 1965.
17. Gonzalez-Ruiz CA, Isla A, Perez-Higuera A, et al: Unusual CT image of a cerebral hydatid cyst. *Pediatr Radiol* 20: 283-284, 1990.
18. Griponissiotis B: Hydatid cyst of the brain and its treatment. *Neurology* 7: 789-792, 1957.
19. Gupta SK, Tandon SC, Khanna S, et al: Multiple intracranial hydatid cysts with postoperative dissemination: case report. *Clin Radiology* 44: 203-204, 1991.
20. Jimenez-Mejias ME, Castillo-Ojeda E, Cuello-Contreras JA, et al: Cerebral hydatidosis. Analysis of a series of 23 cases. *Med Clin Barc* 97: 125-132, 1991.
21. Kaya U, Ozden B, Turker K, Tarcan B: Intracranial hydatid cysts: study of 17 cases. *J Neurosurg* 42: 580-584, 1975.
22. Krajewski R, Stelmasiak Z: Cerebral hydatid cysts in children. *Childs Nerv Syst* 7: 154-155, 1991.
23. Krebs E, Lemoyne J, Loisel G, et al: Syndrome paralytique unilatéral des quatre dernières paires crâniennes du côté gauche, seule traduction clinique d'une échinococcose primitive de l'os occipital. *Rev Neurol* 2: 635-639, 1934.
24. Mingde Q, Zhesheng H: Echinococcosis of the central nervous system. *Chinese Medical Journal* 93 (4): 269-274, 1980.
25. Morquio L: Le kyste hidatique de cerveau chez 1 enfant. *Arch Med Enf* 32: 377-394, 1929.
26. Negovetic L, Lupret V, Smiljanic D, Arsenic B: Cranial vault and gigantic intracranial hydatid cyst in a young woman. *Neurosurgery* 27: 480-482, 1990.
27. Ozgen T, Erbenli A, Bertan V, et al: The use of computerized tomography in the diagnosis of cerebral hydatid cysts. *J Neurosurg* 50: 339-342, 1979.
28. Pasaoglu A, Orhon C, Akdemir H: Multiple primary hydatid cysts of the brain. *Turk J Pediatr* 31: 57-61, 1989.
29. Pearl M, Kotsilimpos DG, Lehrer HZ, et al: Cerebral echinococcosis, a pediatric disease: report of two cases with one successful five-year follow-up. *Pediatrics* 61: 915-920, 1978.
30. Robinson RG: Hydatid disease affecting the nervous system. *Annals of the Royal College of Surgeons of England* 26: 145-156, 1960.
31. Saidi F: *Surgery of Hydatid Disease*. New York: William B. Saunders Co., pp. 352-68, 1976.
32. Samly E, Zadeh FA: Cranial and intracranial hydatidosis with special reference to roentgen-ray diagnosis. *J Neurosurg* 22: 425-433, 1965.
33. Samly E: Involvement of the central nervous system by hydatid cyst. *The British Journal of Clinical Practice* 22: 143-151, 1966.
34. Sharma A, Abraham J: Multiple giant hydatid cysts of the brain: case report. *J Neurosurg* 57: 413-415, 1982.
35. Sierra J, Oviedo J, Berthier M, et al: Growth rate of secondary hydatid cysts of the brain: case report. *J Neurosurg* 62: 781-782, 1985.

