

## OMENTAL GRAFT APPLICABILITY IN EXPERIMENTALLY INDUCED SPINAL CORD COMPRESSION IN RATS

ABDOLREZA SHEIKHREZAE, M.D., SEYYED ALI F. TABATABAI,  
M.D., REZA NAZARI, \*GILA BEHZADI, Ph.D. AND ZAHID  
HUSSAIN KHAN, M.D.

*From the Department of Neurosurgery, Imam Khomeini Hospital, Tehran University of Medical Sciences, Tehran, and the \*Department of Physiology, Shaheed Beheshti University of Medical Sciences, Tehran, Islamic Republic of Iran.*

### ABSTRACT

One of the most important factors responsible for axonal degeneration following spinal cord trauma is ischemia produced by cord compression. Previous studies have revealed that omental transposition upon the injured site of the spinal cord could be beneficial in the induction of partial improvement of neuroelectrical and motor function in laboratory animals. The purpose of this study is to verify the effects of early placement of pedicled omentum on recently traumatized rat spinal cord as measured by subsequent clinical, electromyography (EMG), motor evoked potential (MEP) and horse-radish peroxidase (HRP) labelling methods.

Forty rats were divided into two groups (A&B). After anesthesia, laminectomies were performed at T<sub>12</sub> level and the left lateral half of the spinal cord was compressed intradurally by an aneurysm clip for seven minutes in both groups. The omentum was transposed in group B rats on the lesioned site.

After 3-5 months, evaluation of the muscular forces in the affected limb according to modified Tarlov's classification showed a significant difference between the two groups ( $P < 0.01$ ). EMG showed a greater degree of spasticity in nongrafted animals than grafted ones. MEP showed a powerful signal in grafted animals, but only a weak signal was recorded in the nongrafted group. Injection of HRP into the spinal cord below the compression site demonstrated retrogradely labelled neurons above the compression site in grafted animals, but transmission of HRP was not seen in nongrafted animals.

These results show that transposition of omentum on the injured site of recently traumatized rat spinal cord could be helpful in axonal regeneration.

**Keywords:** Spinal cord injury, Omental transposition, Electromyography, Motor evoked potential, Horse-radish peroxidase.

*MJIRI, Vol. 10, No. 1, 11-16, 1996.*

## INTRODUCTION

The inability of mammalian central nervous system (CNS) axons to regenerate functionally has been alluded to so often in the literature that for practical purposes it has assumed the status of fact. This dictum however has been challenged in the recent years by a body of findings which indicate that restoration and target organ re-innervation may be possible after axotomy if obstacles preventing neural outgrowth can be removed.<sup>4-7,22,27</sup>

A great deal of research concerning spinal cord injuries has been carried out to define events that cause irreversible cord damage. Almost all pathological studies indicate that ischemia plays a prominent role in its pathophysiology. In order to overcome local ischemic changes, omentomyelosynangiosis<sup>20</sup> operation was performed to augment local spinal cord blood flow. This procedure is based on the principle that the omentum possesses an extraordinary capacity for revascularization, and removing vasogenic edema at the omento-spinal cord interface would overcome local ischemic changes.<sup>8,10</sup>

The purpose of our study was to verify this fact by providing omentomyelosynangiosis after producing ischemia in the spinal cord by aneurysm clip-induced compression.

## MATERIALS AND METHODS

Forty albino rats of Wistar strain, weighing 200-300 grams were equally divided into two groups (A and B). All animals were anesthetized with intraperitoneal Ketalar (75 mg/kg) and diazepam (5 mg/kg).<sup>19</sup> This experiment was carried out over a 3-5 month period of observation after spinal cord compression. All rats in this study were evaluated 3-5 months after injury in terms of their ability to walk according to modified Tarlov's neurological classification.<sup>15</sup> All neurological, electromyographic and motor evoked potential recordings were assessed on a blind basis.

All animals were placed in the prone position, laminectomies were performed at T<sub>12</sub>, the dura opened medially and the left lateral half of the spinal cord compressed by an aneurysm clip for seven minutes<sup>28</sup> (Fig. 1). In group A (control group), the muscles, fascia and skin were approximated over the laminectomy site. Group B animals had a 1 cm laparotomy incision made below the left lateral costal margin. The omentum was gently removed from the abdominal cavity, lengthened to a pedicle using Alday and Goldsmith's technique,<sup>1</sup> keeping its vascular attachment to the stomach intact. The pedicle was tunneled subcutaneously to the dorsal

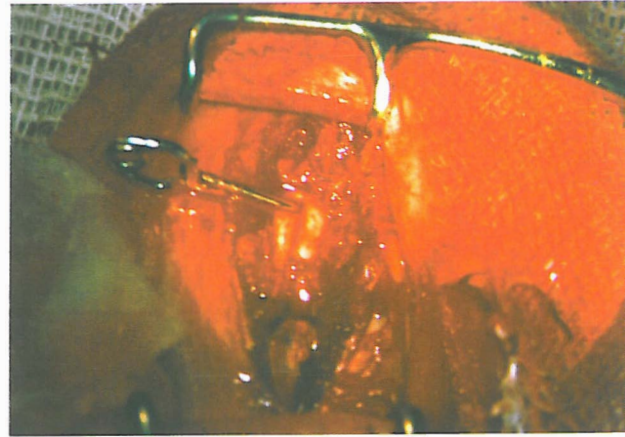


Fig. 1. Spinal cord compression by an aneurysm clip.

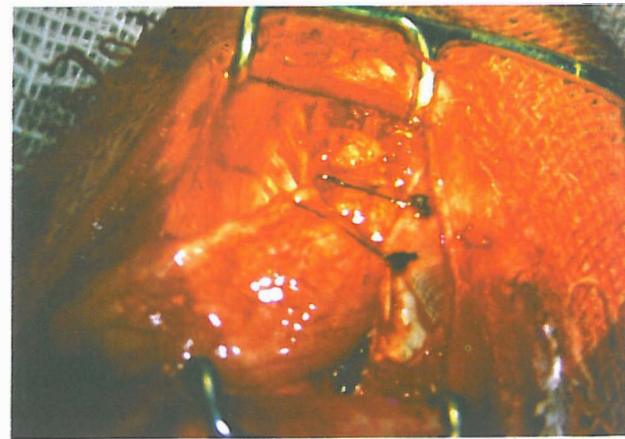


Fig. 2. Omental application on the injured site of spinal cord.

cord,<sup>9</sup> and was laid directly upon the underlying pia mater of the spinal cord afterwards (Fig. 2). Later, the back muscles were sutured loosely in order to maintain close contact at the omento-spinal cord interface. Finally, the fascia and skin were approximated in the same manner as mentioned in group A.

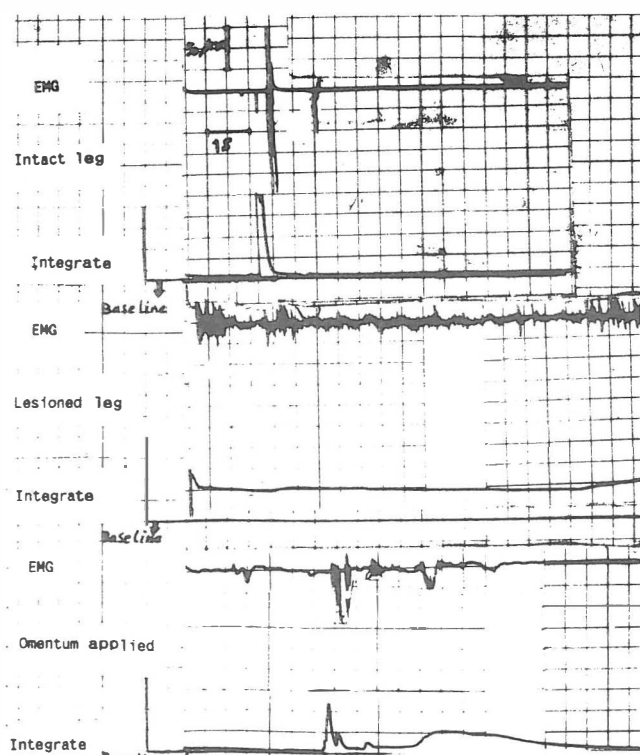
Three rats were randomly chosen from each group according to a simple random sampling method, in order to evaluate the degree of muscular spasticity in the affected limb. For this purpose, two electrodes were inserted into the biceps femoris muscle of the affected limb. Another electrode was employed as a ground electrode for the system, and inserted into another muscle. The same procedure was performed in the unaffected hind limb of the same rat for the purpose of comparison.

Two rats, one from each group, were selected. They were anesthetized in the same manner as mentioned above. Both rats underwent craniotomies and pulses of 50 microsec duration were delivered at a rate of 5/sec to the contralateral motor cortex area of the biceps femoris

**Table I. Comparison of functional data according to modified Tarlov's neurological classification (using Kendall's S test\*).**

Grade	Modified Tarlov classification	Trial cases	Control
6	Complete motor activity	-	-
5	Normal gait but inability to leap	-	-
4	Ability to walk with minor difficulty	1	-
3	Ability to walk with major difficulty	9	2
2	Ability to push up on hind legs and take a few steps	3	4
1	Ability to push up on hind legs but not take any steps	5	4
0	Total paralysis of hind legs	2	10
Total		20	20

\*  $V_s = \frac{n_1 n_2}{3n(n-1)} [n^3 - n(t^3 - t)]$ ,  $S = P - Q$ ,  $V_s = 3022$ ,  $SD = 58.6$ ,  $\text{normalized SD} = \frac{SD}{S} = 3.55$ ,  $P < 0.01$ .



**Fig. 3.** Comparison of EMG activity of lesioned and omentum-applied rats with intact legs of the same animals.

of the affected limb. MEP was recorded from the biceps femoris using an electrode connected to the muscle.

Three days prior to sacrifice, one animal from each group was injected with 5µl of HRP (30% type VI, Sigma) 1 mm below the compressed site. Animals were fixed-perfused and cord tissue from the proximal to

distal regions of the compression site was cut into longitudinal and transverse blocks, sectioned 30 µm in a cryostat and processed for tetramethyl benzidine staining (TMB). Sections were counterstained in neutral red and examined using regular light microscopy.<sup>9,21,26</sup>

## RESULTS

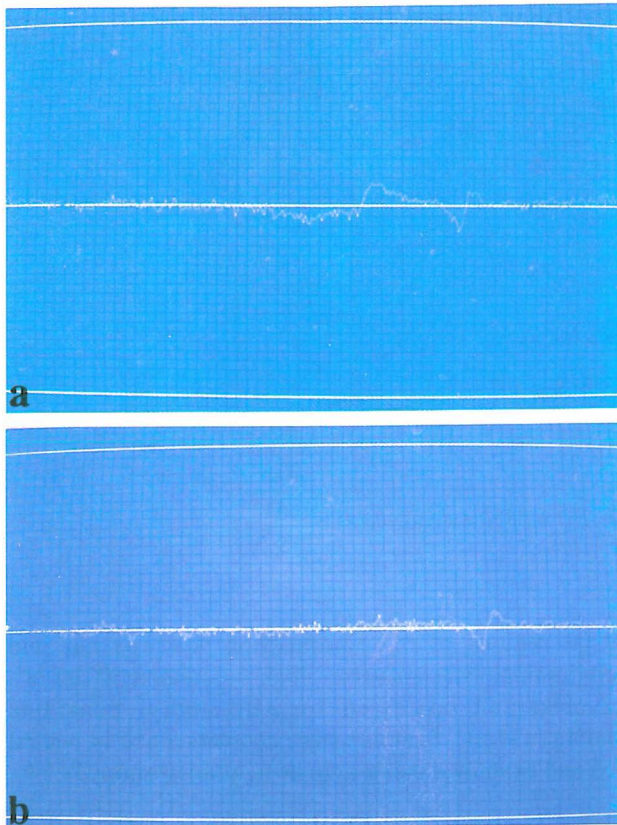
In trial cases, one of the 20 rats was able to walk with minor difficulty; 9 were able to walk with major difficulty; 3 were able to push up on hind legs and take a few steps; 5 were able to push up on hind legs but unable to take a step, and 2 had total paralysis of hind legs.

In control cases, 10 of 20 rats had total paralysis of hind legs; 4 were able to push up on hind legs but unable to take steps; 4 were able to push up on hind legs and take a few steps, and only 2 were able to walk with major difficulty (according to modified Tarlov's neurological classification) (Table I).

We found a significant statistical difference between control and experimental functional levels ( $P < 0.01$  using Kendall's S test).

We compared EMG activity between lesioned and omentum-applied rats with intact legs of the same animals (Fig. 3). There was no degree of spasticity in intact legs of both groups. There was a severe degree of spasticity in affected legs of nongrafted animals but only mild degrees of spasticity were observed in affected legs of grafted animals.

We stimulated a point in the motor cortex of the rat and recorded it from the biceps femoris muscle in the contralateral leg. The recorded signals were powerful in



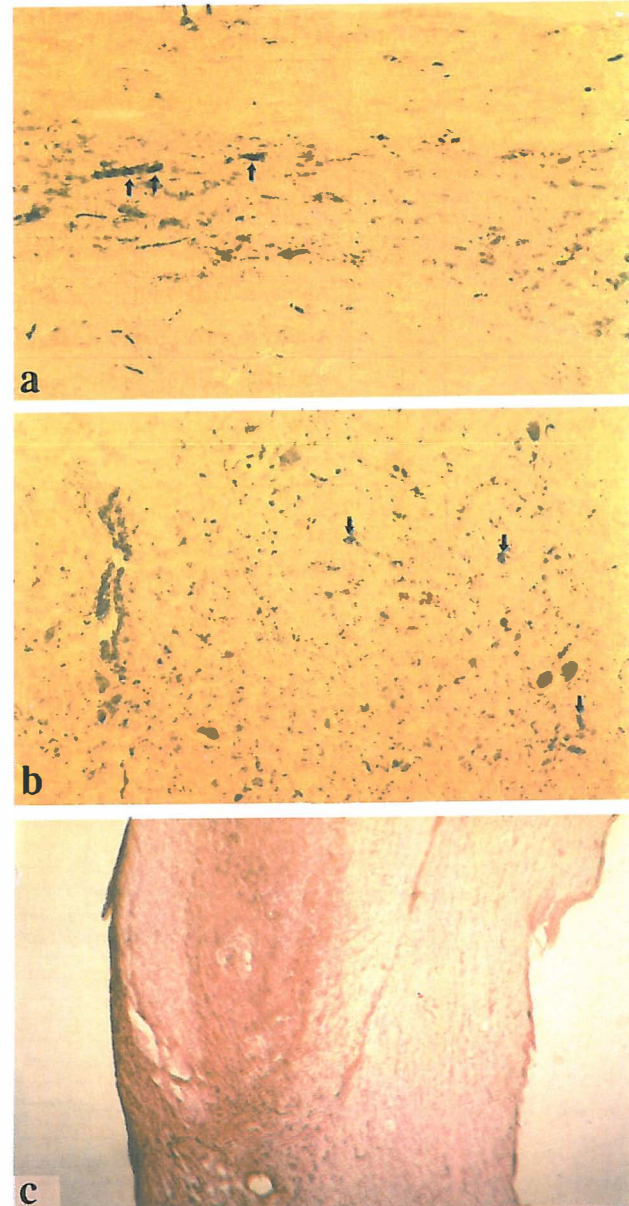
**Fig. 4.** MEP of a representative rat with omental application (a) and without omental application (b). Stimulation pulses of 50 microsec. duration were generated at a rate of 5 stimuli/second with an analysis time of 100 milliseconds.

grafted animals but very weak in the nongrafted group (Fig. 4).

We compared retrograde HRP labelling of neurons in nongrafted and grafted animals with intact animals. Retrograde axonal labelling of neurons 2-3 segments above the compression site was seen in grafted animals, in a manner almost similar to intact animals. Retrograde transport of HRP was not seen in nongrafted animals.

#### DISCUSSION

Pedicle omentum grafting has been used to reconstruct or revascularize damaged organs such as heart,<sup>30</sup> breast,<sup>2</sup> esophagus,<sup>11</sup> liver<sup>12</sup> and tissues requiring reconstructive surgery.<sup>23,29</sup> The advantages of omentoplasty are that the tissue under repair can be quickly revascularized, preserving or increasing its biological viability in the face of impending infection, necrosis and edema. Goldsmith et al. were the first to document that vascular supply to brain<sup>13</sup> and spinal



**Fig. 5.** Retrogradely labelled neurons are seen in the spinal cord of intact rats (a) and grafted animals (b) within Rexed lamina VII, proximal to the compression site, but not in nongrafted cases (c). HRP was injected distal to the compression site 72 hours earlier.

cord<sup>14,15</sup> could be significantly enhanced by transposition of an intact pedicled omentum placed on the lesioned CNS site.

The resultant CNS blood flow increase, using the omental approach, appears to be permanent.<sup>8</sup> These findings have also been confirmed by others.<sup>3,30</sup> Placement of pedicled omentum on an acutely injured

spinal cord results moreover in sensorimotor and neuroelectrical improvement in experimental animals when compared to nontreated controls,<sup>14,15</sup> a fact which has been confirmed by our study as well. The presence of horse-radish peroxidase labelled cells proximal to the injured site, indicates that supraspinal-derived neuritic regeneration has occurred. Retrograde HRP transport has been reported in Rexed lamina VII-IX neurons when an identical collagen matrix plus pedicled omentum was used in a cord-transected cat model. Similarly, we too observed HRP-labelled neurons in Rexed lamina VII in omentum grafted animals. Our results indicate that the substantial regeneration which is achieved by omental transposition may result from improved spinal cord blood flow to the injured site.<sup>9</sup> Since omentum has also been shown to harbor neurotrophic material, neurotransmitters, and a lipid factor which induce rapid angiogenesis in tissue,<sup>18</sup> it is conceivable that a chemical or chemical-vascular phenomenon might be responsible for the clinical and morphologic differences seen between groups A and B.

The notion that an adequate vascular supply to traumatized CNS tissue is critical to the outgrowth potential of severed axons is widely accepted by investigators. As Kiernan<sup>24</sup> has pointed out, growing CNS axons may require proteins released from blood plasma for successful regeneration. However, blood flow or possible derivatives from it are seldom measured or discussed in mammalian CNS regeneration studies. It is unclear as to what "adequate flow" or "minimum flow" requirements are needed to refurbish central axonal regrowth.

Conclusively, we think that determination of the minimal required blood flow rate for optimal axon outgrowth could form the basis for new research attempts towards the solution of this highly perplexed problem.

#### ACKNOWLEDGEMENTS

We wish to thank the Cancer Institute of Imam Khomeini Hospital for giving us the opportunity to use their equipment, the Department of Physiology, Shaheed Beheshti University, for their help in electromyographic evaluation and Mr. Farzam for affording us technical assistance.

#### REFERENCES

1. Alday ES, Goldsmith HS: Surgical technique for omental lengthening-based arterial anatomy. *Surg Gynecol Obstet* 135: 103-107, 1972.
2. Arnold PG, Hartramf C, Jurkiewicz M: One stage reconstruction of the breast using the transposed greater omentum. *Plast Reconstr Surg* 57: 520-522, 1976.
3. Abraham J, Maroun F, Randell R, Jacob J, Wright E: Reduction of posttrauma spinal cord edema by omental transposition. *Can J Neurosci* 14: 211, 1987.
4. Berry M: Regeneration in central nervous system. *Rec Adv Neuropath* 67: 111-132, 1979.
5. de la Torre JC: Experimental problems in spinal cord neural reconstruction. In: Gilad G, Gorio A, Kreutzberg G (eds.). *Process of Recovery From Neural Trauma*. Springer-Verlag, New York, pp. 317-325, 1986.
6. de la Torre JC: Spinal cord injury models. *Progr Neurobiol* 22: 289-344, 1984.
7. de la Torre JC, Hill P, Gonzalez M, Parker J: Evaluation of transected spinal cord regeneration in the rat. *Exp Neurol* 84: 186-206, 1984.
8. de la Torre JC, Goldsmith HS: Increased blood flow enhances axonal regeneration after spinal transection. *Neurosci Lett* 94: 267-273, 1988.
9. de la Torre JC, Goldsmith HS: Collagen omental graft in experimental spinal cord transection. *Acta Neurochir (Wein)* 102: 152-163, 1990.
10. Goldsmith HS, Duckett S, Chen W: Spinal cord vascularization of the intact omentum on the normal and injured spinal cord. In: Kao CC, Bunge RP (eds.). *Spinal Cord Reconstruction*. Raven Press, New York, pp. 235-243, 1975.
11. Goldsmith HS, Kiely A, Randal H: Protection of intrathoracic esophageal anastomoses by omentum. *Surgery* 63: 464-466, 1968.
12. Goinard P: Sur le traitement des kystes hydatiques du foie; la epiploplastie intracavitare. *Presse Med* 58: 1203-1205, 1950.
13. Goldsmith HS, Chen WF, Duckett S: Brain vascularization by intact omentum. *Arch Surg* 106: 695-698, 1973.
14. Goldsmith HS, Duckett S, Chen W: Spinal cord vascularization by intact omentum. *Am J Surg* 129: 262-265, 1975.
15. Goldsmith HS, Steward E, Duckett S: Early application of pedicled omentum to the acutely traumatized spinal cord. *Paraplegia* 23: 100-112, 1985.
16. Gelderd JB: Growth of blood vessels and neurites into a collagen matrix placed between cut ends of transected rat spinal cord. *Soc Neurosci Abs* 13: 395, 1987.
17. Goldsmith HS, McIntosh T, Vezina R, Colton T: Vasoactive neurochemicals identified in omentum; a preliminary report. *Br J Neurosurg* 1: 359-364, 1987.
18. Goldsmith HS, Griffith A, Kupferman A, Catsimpoalas N: Lipid angiogenic factor from omentum. *JAMA* 252: 2034-2036, 1984.
19. Wayforth HB, Flecknell PA: *Experimental and surgical technique in the rat*. London: Academic Press, pp. 118,

## Omental Graft in Spinal Cord Compression

- 1992.
20. Abraham J, Paterson A, Bothra M, Mofti AB, Taylor GW: Omentomyelosynangiosis in the management of chronic traumatic paraplegia: a case report. *Paraplegia* 25: 44-49, 1987.
  21. de la Torre JC, Goldsmith HS: Supraspinal fiber outgrowth and apparent synaptic remodelling across transected-reconstructed feline spinal cord. *Acta Neurochir (Wein)* 114: 118-127, 1992.
  22. Kiernan JA: Hypotheses concerned with axonal regeneration in the mammalian nervous system. *Biol Rev* 54: 155-197, 1979.
  23. Kiricuta I: The use of omentum in plastic surgery. In: Jackson IT (ed.). *Recent Advances in Plastic Surgery*. Churchill - Livingstone, New York, pp. 201-224, 1981.
  24. Kiernan JA: An explanation of axonal regeneration in peripheral nerves and its failure in the central nervous system. *Med Hypoth* 4: 15-26, 1978.
  25. McCluer RH, William J, Griffith A, Catsimpoilas N: Characterization of feline omentum lipids. *Lipids* 22: 229-235, 1987.
  26. Mesulam MM: Tetramethyl benzidine for horse-radish peroxidase neurohistochemistry: a non-carcinogenic blue reaction product with superior sensitivity for visualizing neural afferents and efferents. *J Histochem Cytochem* 26: 106-107, 1978.
  27. Nygren LG, Olson L, Seiger A: Monoaminergic reinnervation of the transected spinal cord by homologous fetal brain graft. *Brain Res* 129: 227-235, 1977.
  28. Rivilin AS, Tator CH: Effect of duration of acute spinal cord compression in new acute cord injury model in the rat. *Surg Neurol* 10: 39-43, 1978.
  29. Turner WR: The use of omental pedicle graft in urinary tract reconstruction. *Br J Surg* 54: 849-853, 1967.
  30. Vineberg A, Lwin M: A new concept to restore the failing enlarged, ischemic heart; a preliminary report. *Chest* 61: 267-271, 1972.