

PAUWELS' OSTEOTOMY FOR FEMORAL NECK NON-UNION

F. ABDINEJAD, M.D., AND M.J. EMAMIE, M.D.

*From the Department of Orthopedics,
Shiraz University of Medical Sciences,
Shiraz, Islamic Republic of Iran.*

ABSTRACT

During a period of nine years (1982-1991), Pauwels' osteotomy was performed for 38 cases of femoral neck non-union. 32 led to consolidation with one osteotomy (84%) and 6 failed (3 needed revision (92%), one died and two were lost to follow-up).

The length of follow-up was 2-11 years, the average time of non-union 12 months (ranging from 4 months to 13 years) and the mean patient age 33 years (ranging from 3-58 years).

According to the method of fixation the cases were divided into 3 groups, and the best results were achieved in group III which were treated via a modification of Pauwels' technique.

MJIRI, Vol. 10, No. 1, 21-26, 1996.

INTRODUCTION

Today, in spite of improved methods of treatment, the fractured femoral neck has a higher percentage of non-union (10% to 20%) than any other fracture.^{1,6,17}

The treatment of non-union may be grouped as follows: 1) osteosynthesis, 2) osteotomy, 3) prosthesis replacement, 4) total hip replacement, 5) excisional arthroplasty, and 6) arthrodesis.^{1,6,17,18}

Most authors recommended osteotomy for those types of non-union in which the head is viable and the neck fairly well preserved in children and in adults less than 60 years of age.^{1,6,17}

Historically, two types of osteotomy have been proposed: 1) displacement osteotomy which was first described by Lorenz in 1919 and then used by Hass in 1924 and finally popularized by McMurray, and 2) angulation osteotomy or Schanz osteotomy which was introduced in 1925.^{1,6,12,16,17} These standard osteotomies have high failure rates because the mechanical situations of different fractures are extremely variable.^{1,6,17}

Pauwels, in 1935, pointed out that different types of non-union need different osteotomies.^{16,17} An x-ray is taken of the hip with the leg in the position that best shows the

pseudarthrosis. An exact tracing is made of the hip joint and the pseudarthrosis. The angle formed by the (H) line and the (Ps) line minus 16° (here 45°) shows the size of the wedge to be resected (Fig. 1 a, b, c, d).

MATERIAL AND METHODS

From 1982 to 1991, Pauwels' osteotomy was performed for 38 femoral neck non-unions. The average age of the cases was 33 (range 3-58) and mean non-union time was 12 months (range 4 months to 13 years).

Fixation

Pauwels used double tension wire bands for osteotomy fixation but for non-union he believed that if there was fibrosis at the non-union site, a fixator is not necessary; otherwise, a fixator is needed.

According to fixation, the patients were divided into three groups.

Group I: Eleven cases (Table I). In this group the osteotomy was fixed by tension wire bands but no fixator was used for the non-union, and a spica cast was applied for 8-12 weeks. 5 cases healed but 6 failed, as 3 needed revision, one died due

Pauwels' Osteotomy for Non-Union

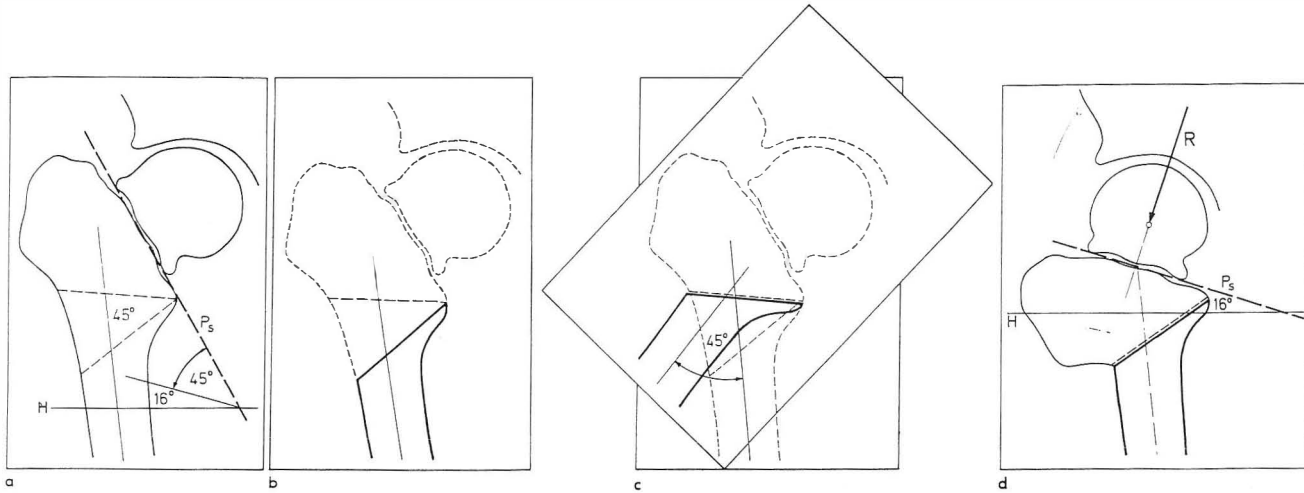


Fig. 1 (A, B, C, D).

- A.** First sheet; a sketch of the X-ray that best shows the pseudoarthrosis
- B.** Second sheet; a drawing of the inferior fragment of the osteotomy.
- C.** Second sheet placed on first sheet and rotated clockwise until the osteotomy lines of two fragments coincide. The upper fragment is then traced.
- D.** Operation diagram

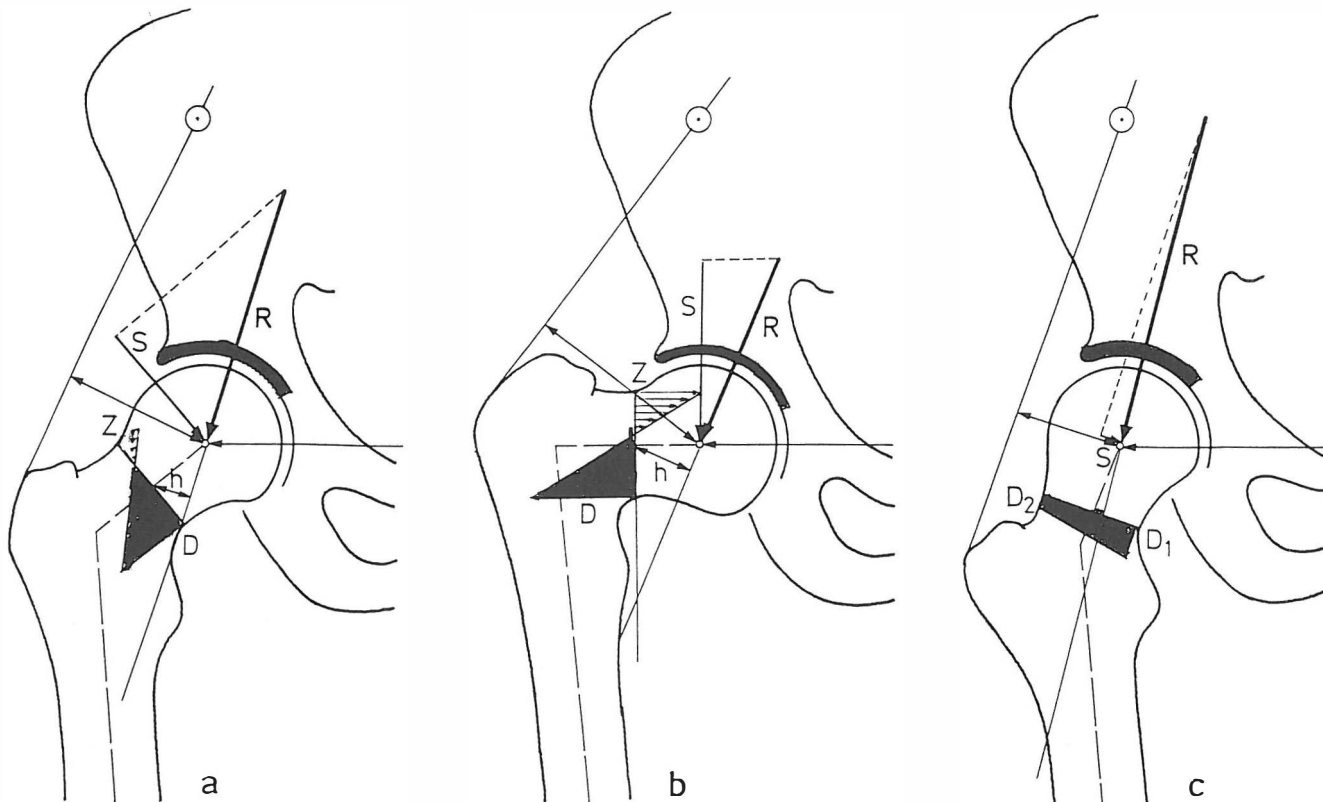


Fig. 2 (A, B, C). Influence of the neck/ shaft angle on the magnitude of the forces

Table I. Group I.

Case No.	Sex	Age	Side	Cause	Previous Procedure	Fixation of non-union	Fixation of osteotomy	Duration of non-union Yrs. + Mo.	Duration of follow-up Yrs.+Mo.	Genu valgum	Shortening cm	Necrotic head before osteotomy	Harris hip score	Results
1	F	3	L	Car accident			wire	8	8 2	10°	1.5		100	united
2	M	10	L	Car accident	Hip nailing		wire	3 6	7	15°	1.5		100	united
3	F	17	L	Falling down			wire	1 3	7	20°	1.5	yes	82	united
4	F	50	R	Falling down	Hip nailing		wire	1 6	1					failed
5	M	14	L	Car accident	Hip nailing		wire	1 2	7 1	15°	1	yes	94	united
6	M	44	R	War injury	Hip nailing		wire	2 3	7 10				92	failed
7	F	14	R	Falling down	Hip nailing		wire	2 1	5 3	10°	2	yes	82	united
8	F	48	L	Falling down	Hip nailing		wire	1 8	3 3				95	failed
9	M	8	R	Car accident	Hip nailing		wire	1 4	1 2					failed
10	M	49	L	Pathologic			wire	1 9	1 3					failed
11	M	43	L	Pathologic			wire	2 6	7 2				95	failed

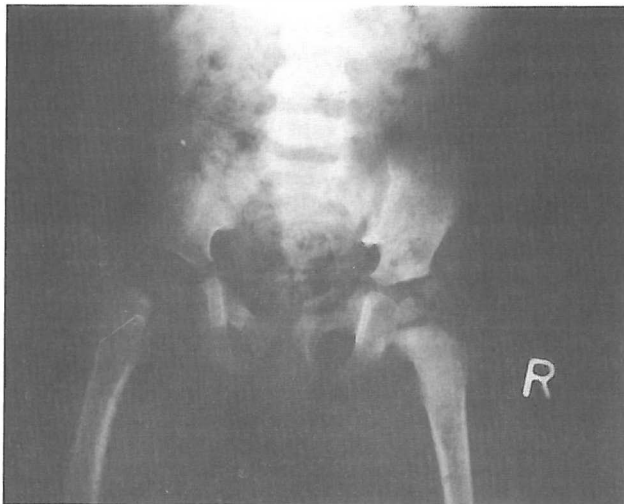


Fig 3, A. Case 1 (pre - op)

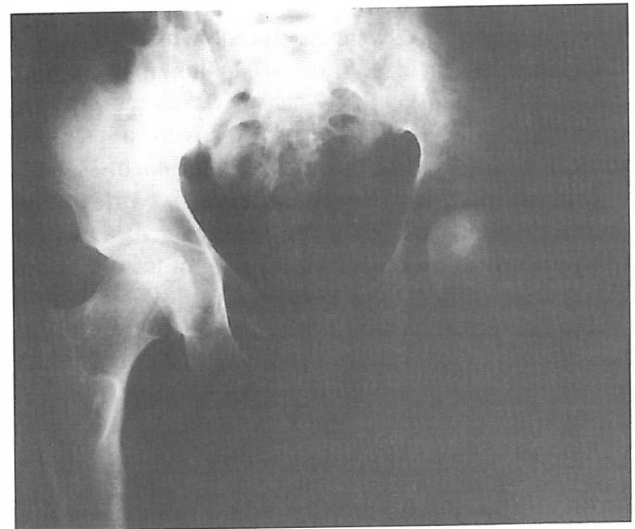

Fig 4, A. Case 12 (pre - op).

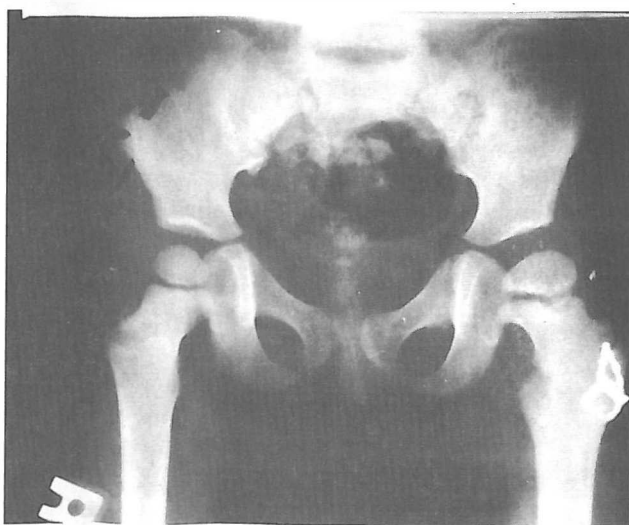

Fig 3, B. Case 1 (2 years 8 months, post op)

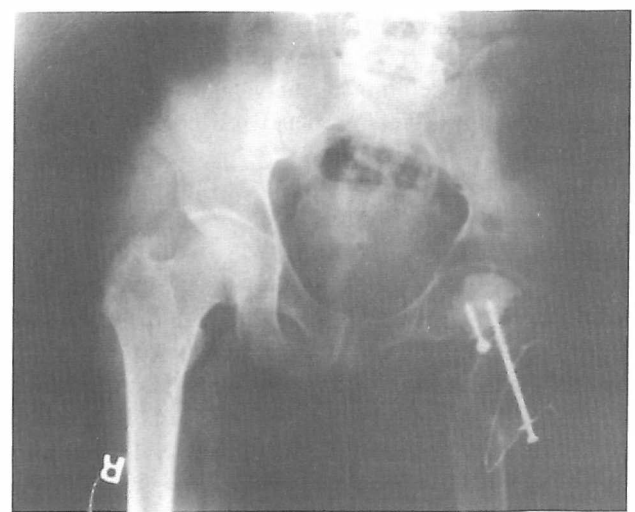

Fig 4, B. Case 12 (2 years 3 months, post op).

Table II. Group II.

Case No.	Sex	Age	Side	Cause	Previous Procedure	Fixation of non-union	Fixation of osteotomy	Duration of non-union		Duration of follow-up		Genu valgum	Shortening (cm)	Necrotic head before osteotomy	Harris hip score	Results
								Yrs + Mo	Yrs+Mo							
12	M	24	L	War injury	Debridement	1 screw	wire	1	2	8	10	20°	2.5	yes	83	united
13	M	28	L	War injury	Hip nailing	2 screws	wire	1	9	6	2	10°	1		99	united
14	M	15	L	War injury	Debridement	2 screws	wire	6	6	6	1	15°			99	united
15	M	16	R	Car accident		3 screws	wire	6	6	6	6				97	united
16	M	52	L	Car accident		3 screws	wire	6	5	2					97	united
17	M	16	L	War injury	Debridement	2 screws	wire	6	5	1		15°			99	united
18	M	17	R	War injury	Debridement	3 screws	wire	6	4	10		15°			100	united
19	M	57	L	Car accident	Hip nailing	2 screws	wire	2	4	4	6		1		100	united
20	M	55	R	Car accident	Hip nailing	2 screws	wire	2	3	5	2				97	united
21	M	24	R	War injury		3 screws	wire	1	10	4	11	10°	1.5	yes	81	united
22	F	24	L	Pathologic		3 screws	wire	1	6	3	10				97	united

to thyroid cancer and 2 were lost to follow-up (Fig. 3a, b).

Group II: Eleven cases (Table II). In this group the non-union was fixed via 2 or 3 A-O lag screws (closely) but the osteotomy was fixed by tension wire bands and a spica cast worn for 8-12 weeks. All cases healed (Fig. 4a, b).

Group III: 16 cases. The non-union was fixed by A-O lag screw and/or Steinman pin but the osteotomy via a buttress T plate (anteriorly). A spica cast was worn for 6-8 weeks (Fig. 5a, b).

The non-union was fixed closely in all groups but two cases needed open reduction supplemented with a muscle pedicle bone graft (cases 12, 23) (Figs. 4a, b, 5a, b).

Avascular necrosis: 7 cases had avascular necrosis prior to osteotomy—6 with partial and one with total involvement (case 12)—but deformity was minimal.

War injury: 7 cases, one with severe soft tissue injury (case 12), three with moderate soft tissue injury and three with closed fractures.

Discrepancy: all patients had limb shortening before surgery. Some underwent full recovery while others did not (Tables I, II, III).

Genu-valgum deformity: genu-valgum developed after valgus osteotomy of the hip; group III had the least deformity (Table III).

RESULTS

32 of 38 cases healed with one osteotomy (84%) while 6 failed—one died, two were lost to follow-up and 3 needed revision (92%). Concerning gait and activity by Harris' criteria, all cases scored 80 to 100 points (Harris' criteria: R.O.M.=5, pain=44, activity=13, transport=1, gait=33, absence of deformity =4, total=100 points).

Group I had a high failure rate. Group II and group III patients all healed but group III with a short casting time and less genu valgum deformity.

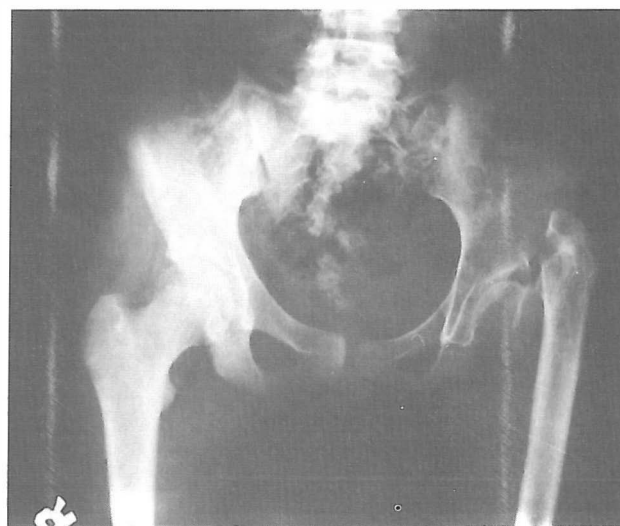

Fig 5, A. Case 23 (pre - op)

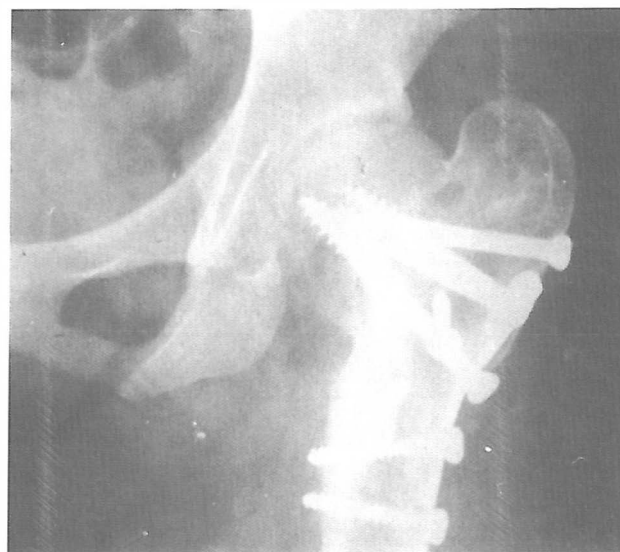


Fig. 5, B. Case 23 (3 years 2 months, post-op)

Table III. Group III.

Case No	Sex	Age	Side	Cause	Previous Procedure	Fixation of non-union	Fixation of osteotomy	Duration of non-union		Duration of follow-up		Genu valgum	Shortening (cm)	Necrotic head before osteotomy	Harris hip score	Results
								Yrs+	Mo	Yrs+	Mo					
23	F	12	L	Falling down	Hip nailing	3 screws	plate	10	3	11	1	15°	2		97	united
24	M	28	L	Falling down		3 screws	plate	3	2	8	2				99	united
25	M	35	L	Falling down	Hip nailing	3 screws	plate		4	4	4				99	united
26	M	30	L	Car accident		S. pins 4	plate	1	4	4	2				100	united
27	F	42	L	Falling down	Hip nailing	S. pins 3	plate	1	5	3	2				100	united
28	F	12	R	Falling down		S. pins 3	plate	3	2	3	3				99	united
29	M	30	L	Car accident		S. pins 3	plate		4	3	1			yes	83	united
30	F	56	R	Falling down		S. pins 3	plate		6	3	1				93	united
31	M	59	L	Falling down		S. pins 3	plate	1	5	3					93	united
32	M	33	R	Falling down		S. pins 3	plate	13	6	3	4	20°	3		82	united
33	M	12	R	Falling down		S. pins 3+	plate		6	2	9				98	united
34	F	38	L	Motorcycle accident		S. pins 3+	plate		8	2	6	10°			85	united
35	M	38	L	Motorcycle accident		S.pins 3+ +screw 1	plate		8	2					90	united
36	M	56	L	Car accident		S.pins 3+	plate		9	2	2	10°			82	united
37	F	38	R	Falling down		S. pins 3+	plate		6	2	8				85	united
38	F	18	L	Falling down		Blade	plate	2	6	2	3		1.5		yes	92

DISCUSSION

Pauwels, the founder of modern biomechanics, proved in 1940 that 1) pure compressive stress of acceptable magnitude, encourages the formation of bony callus, 2) tensile stress retards bone formation, and 3) shearing stress is harmful and prevents the formation of bony callus.^{9,10,11,16,17}

In the normal neck shaft angle, shearing, tensile, and compressive stresses are all exerted on the femoral neck. In varus positions all forces are increased and in valgus positions decreased (Fig. 2a, b, c).^{2,3,4,9,10,16,17}

According to Pauwels' calculation, in coxa-valga with a neck-shaft angle of 150-155 degrees, compressive forces are high but shearing forces are absent or minimal.^{1,9,10,11,16,17} Consequently, the specific role of a basic treatment, such as a valgus osteotomy, is to convert shearing and tensile stresses into pure compressive forces.

Group I had a high failure rate because theoretically the 150 degree angle is obtainable, but is sometimes difficult practically and sometimes impossible; therefore some shearing stress persists. The basic treatment method must eliminate the shearing stress, thus appropriate nailing is the method of choice.^{16,17}

Some authors believe that degenerative changes develop after 3 to 5 years.^{1,6,18} In our study, 29 cases had 3 to 11 years of follow-up and no degenerative changes developed.

Group III had less genu valgus deformity because, as medial displacement of the femoral shaft is the cause of this deformity,^{1,9,10,11} in this group the osteotomy was performed

with some lateral displacement of the distal fragment and fixed with a buttress T plate.

In conclusion, Pauwels' osteotomy is not a standard osteotomy; different non-unions need different osteotomies schematic the schematic drawings designed. This study shows that non-unions must be fixed closely with A-O lag screws and/or pins and the osteotomy fixed anteriorly by a buttress T plate.

REFERENCES

1. Ballmer FT, Ballmer PM: Pauwels' osteotomy for non-unions of femoral neck fractures. *Orthopedic Clinics of North America* 21 (4): 759-767, 1990.
2. Bombelli R: The role of osteotomy as a consequent therapy. In: *Osteoarthritis of the Hip*. 2nd ed., Berlin: Springer-Verlag, pp. 49-119, 1983.
3. Braune W, Fischer O: Attitudes of the Unloaded Body on the Center of Gravity of the Human Body. Berlin: Springer-Verlag, pp. 62-71, 1985.
4. Braune W, Fischer O: Rotations of the hip line: experiments on man, loaded and unloaded. In: *The Human Gait*. Berlin: Springer-Verlag, pp. 94-103, 1987.
5. Catto M: A histological study of avascular necrosis of the femoral head after transcervical fracture. *J Bone Joint Surg (Br)* 47 B : 749-776, 1965.
6. Crenshaw AH: Delayed union and non-union of fractures: femoral neck, In: Crenshaw AH(ed.), *Campbell's Operative Orthopaedics*, 7th ed., Vol 3 , St. Louis : Mosby-Year Book Co., pp. 2053-2121, 1989.

Pauwels' Osteotomy for Non-Union

7. Harris WH: Traumatic arthritis of the hip after dislocation and acetabular fractures treatment by mold arthroplasty. *J Bone Joint Surg (Am)* 51A (4): 737-754, 1959.
8. Hass S: Zur Technik der Lorenzchen Bifurkation: *Zeitschr F Orthop Chir.* Vol. 43, pp. 121-129, 1924.
9. Maquet PG: Foundation and technique. In: *Biomechanics of the Normal and Diseased Hip.* Berlin: Springer-Verlag, pp. 11-159, 1985.
10. Maquet PG: Theoretical Foundation, *Biomechanics of the Knee.* Berlin: Springer-Verlag, pp. 12-98, 1978.
11. Maquet PG: Iatrophysics to Biomechanics. *J Bone Joint Surg (Br)* 74B (3): 335-339, 1992.
12. Marti RK: Intertrochanteric osteotomy for non-union of the femoral neck. *J Bone Joint Surg (Br)* 71B: 782-789, 1989.
13. McMurray TP: Ununited fractures of the neck of the femur. *J Bone Joint Surg (Br)* 18B: 319-329, 1936.
14. McMurray TP: Fracture of the neck of the femur treated by oblique osteotomy. *Br Med J* 3: 330-339, 1938.
15. Meyers MH, Harvey JP: The delayed treatment of displaced subcapital fracture of the neck of the femur with internal fixation and muscle pedicle bone graft. *J Bone Joint Surg (Am)* 56A: 195-208, 1974.
16. Pauwels F: *Biomechanics of the normal and diseased hip: theoretical foundation, technique and results of treatment.* Berlin: Springer-Verlag, pp. 1-126, 1976.
17. Pauwels F: The fractures of the femoral neck; a mechanical problem . In: *Biomechanics of the Locomotor Apparatus.* Berlin: Springer -Verlag, pp. 1-105, 1980.
18. Zabihi T, Kohanim M, Amir-Jahed AK: Modified Girdle-Stone operation in the treatment of complications of fractures of the femoral neck. *J Bone Joint Surg (Am)* 55 A: 129-134, 1973.