

## Transverse myelitis and heroin abuse: a case report

Bahram Haghi-Ashtiani, MD.<sup>1</sup>, Farzad Sina, MD.<sup>2</sup>, Fowzieh Ben Isa, MD.<sup>3</sup>  
Mohammad Rohani, MD.<sup>4</sup>

*Neurology Ward, Baradaran Rezaei Hospital, Damghan, Semnan, Iran.*

### Abstract

The usage of heroin is associated with a variety of neurologic disorders, including acute transverse myelitis. In this study we present a 19 year old man who was suffered from insufflated heroin after several months of abstinence, and admitted to hospital emergency department, unconscious. He responded to fluid therapy and Naloxone, but could not move his legs on examination. He had flaccid paralysis of both legs, acute urinary retention and diminished rectal tone. Deep tendon reflexes were absent with downward plantar reflexes. Analysis of CSF was normal, and the MRI of the spine revealed confluent hyperintensity on T2-weighted images from the C5 to T2 vertebral levels involving the majority of the cord substance. The cord was mildly expanded without any enhancement after Gadolinium injection. Suggested mechanisms of heroin-associated myelopathy include hypotension, a direct toxic effect of heroin, vasculitis, and hypersensitivity reaction. Hypersensitivity was the predominant theory since the initial reports, implied that most patients with developed myelopathy had relapsed into heroin use after a period of abstinence. Treatment with either IV corticosteroids or immunopheresis could blunt the immune response, preventing disability. Efficacy of these methods require more studies in future.

**Keywords:** transverse myelitis, drug abuse, heroin

### Introduction

The neurological complications of heroin use are probably caused by both the drug itself and the method of administration.

Heroin addicts experience illnesses affecting all parts of the neuraxis including brain abscess, transverse myelitis, neuropathy and rhabdomyolysis with myoglobinuria.

In this case report, the myelopathy induced by heroin use and its suggestive mechanisms are discussed. These mechanisms include hypotension, a direct toxic effect of heroin, vasculitis, and hypersensitivity reaction.

### Case report

A 19-year-old man presented to the emergency department of Rasoul Hospital unconscious.

He was a former heroin abuser who had insufflated heroin after several months of abstinence. At the time of admission his blood pressure was 80/40, respiratory rate 8/min, and axillary temperature of 36.8C. No skin abnormality was seen nor bruit heard along his dorsal thorax. His thoracic spinous processes were not tender to percussion.

He responded to fluids treatment and awoken after administration of naloxone, but it was then

1. **Corresponding author**, Neurologist. Baradaran Rezaei Hospital, Damghan, Semnan, Iran. Email: bhaghi2000@yahoo.com

2. Neurologist.

3&4. Assistant Professor of Neurology, Iran University of Medical Sciences, Tehran, Iran.

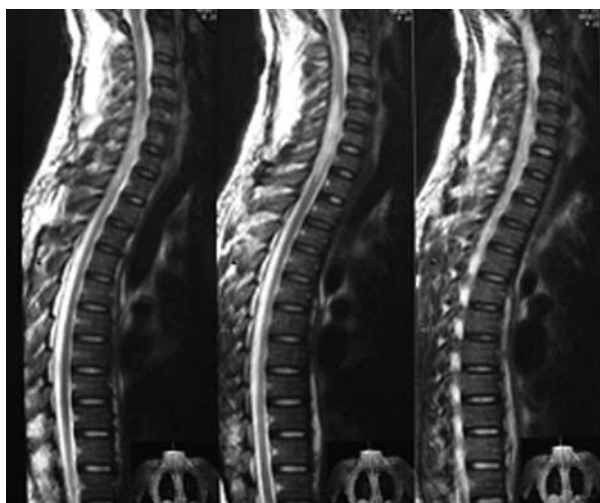


Fig. 1. T2 MRI Image shows hyper-signal cord expansion in C5-T2 segment of spinal cord.

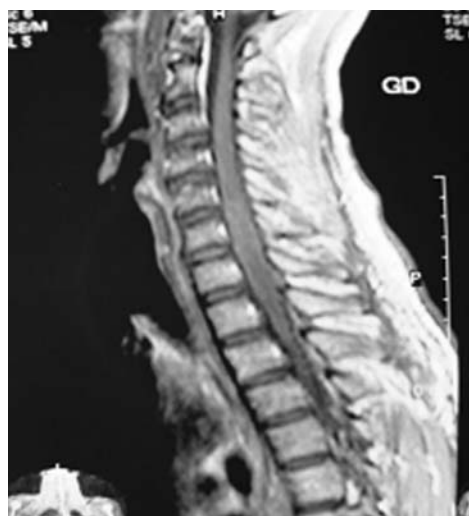

Fig. 2. T1 MRI with contrast shows no enhancing cord expansion in C5-T2 level.

evident that he could not move his legs. The patient had flaccid paralysis of legs, acute urinary retention, and diminished rectal tone.

On neurological examination deep tendon reflexes were absent and plantar reflexes down-warded. He had sensory level at T4, and abdominal reflex was absent. The joint position and vibration sense of lower limbs were impaired.

The MRI of the spine revealed confluent hyper-intensity on T2-weighted images from the C5 to T2 vertebral levels involving the majority of the cord substance (Fig.1). The cord was mildly expanded without enhancement on T1-weighted images from C5 to T2 (Fig.2).

Analyses of CSF for glucose, total protein, and cell count were not remarkable. Additional studies showed normal immunoglobulin G (IgG), albumin, and IgG/albumin ratio, and absence of oligoclonal bands. Moreover the PCR test for HSV1&2 was negative.

During rehabilitation his strength was improved and lower extremity spasticity developed. Transient midthoracic sensory level was appreciated. His tendon reflexes were symmetrically increased and the plantar responses became extensor.

He walked using a walker seven months after his injury.

### Discussion

This case of heroin myelopathy is similar to other reports, except that the other cases employed IV [1-5] instead of intranasal heroin. Similar to other cases, a period of heroin abstinence followed by a single use of heroin leading to paralysis [1,3,4]. Common to the other cases, our patient's deficits included urinary retention, heroin-associated rhabdomyolysis, and onset of paraplegia after awakening from sleep [1-4].

Most reports describe normal CSF findings on routine analysis, although pleocytosis and increased total protein may occur. [1-3,5]. Results of CSF Ig tests were normal for this patient and others [2].

In early reports of cases of heroin-associated myelopathy, imaging was limited to myelography. Most authors have reported normal myelograms [1,3,5] but widening of the cord also occurred [2,3]. Non-contrasted CT has shown patchy hyperdensity and cord edema [4]. The spinal angiography [4] and MRI [5] have been normal. In other studies our MRI findings were consistent with MRI findings for acute transverse myelitis. The T2-weighted images showed cord swelling, with increased signal over several levels involving most of the trans-

verse diameter of cord. Enhancement was variable and patchy. The Gadolinium enhancement occurred acutely, consistent with an acute inflammatory process disrupting the blood-cord barrier [6].

Suggested mechanisms of heroin-associated myelopathy include hypotension, a direct toxic effect of heroin, vasculitis, and hypersensitivity reaction [1-5]. Hypotension is unlikely to be severe enough to damage the spinal cord and spare the more ischemia-sensitive neurons of the brain. Furthermore, although the level of injury varies among reported case, no pattern has yet emerged fitting the vascular "watershed zones" of the spinal cord. Isolated toxicity to the spinal cord with cataclysmic presentation usually follows administration of intrathecal agents. Systemic toxins usually involve the nervous system more diffusely, along with other organs. Generalized vasculitis would be unlikely to first affect the spinal cord with its vast vascular anastomoses.

Hypersensitivity has been the predominant theory since the initial reports, as most patients who developed myelopathy had relapsed into heroin use after a period of abstinence [1,3,4]. As with many drug allergies, sensitization must occur first. Upon re-exposure to the drug, a hypersensitivity reaction ensues. This usually occurs via hypotension of the drug with an in vivo protein. In heroin-associated myelopathy, this may involve a protein specific to spinal cord parenchyma causing acute local inflammation, ischemia, and tissue injury. Treatment with either IV corticosteroids or immunopheresis may blunt the immune response, preventing disability.

Heroin smoking and insufflations have increased dramatically due to fears of HIV infection associated with IV drug use [7]. Additional cases of heroin-associated myelopathy after non-IV use should be expected, especially in former heroin users. Immune-mediated attack on the spinal cord is the likely injurious mechanism. Whether corticosteroids or plasmaphere-

sis would benefit this group of patients remains to be seen.

### Acknowledgments

Thanks to emergency and neurology department of Rasoul Hospital for their aids in managing and data collecting for this patient.

### References

1. Richter RW, Rosenberg RN. Transverse myelitis associated with heroin addiction. *JAMA* 1968; 206:1255-1257.
2. Lee MC, Randa DC, Gold LH. Transverse myelopathy following the use of heroin. *Minn Med* 1976; 59:82-83.
3. Ell JJ, Uttley D, Silver JR. Acute myelopathy in association with heroin addiction. *J Neurol Neurosurg Psychiatry* 1981; 44:448-450.
4. Grassa C, Montanari E, Scaglioni A, Passeri S, Saginario M. Acute heroin myelopathy-case report. *Ital J Neurol Sci* 1984; 5:63-66.
5. Malik MM, Woolsey RM. Acute myelopathy following intravenous heroin: a case report. *J Am Paraplegia Soc* 1991; 14:182-183.
6. Tartaglino LM, Flanders AE, Rapoport RJ. Intramedullary causes of myelopathy. *Semin Ultrasound CT MRI* 1994; 15:158-188.
7. Meng Y, Lichtman AH, Bridgen DT, Martin BR. Inhalation studies with drugs of abuse. In: Rapaka S, Chiang N, Martin BR, eds. *Pharmacokinetics, metabolism, and pharmaceuticals of drugs of abuse*. Bethesda, MD: National Institute on Drug Abuse Res Monograph 1997: 221-224.