

# MODIFIED ONE-FINGER LAPAROSCOPY TECHNIQUE

H. DABIRASHRAFI, M.D., Y. BEHJATNIA, M.D., AND  
N. MOGHDAMI TABRIZI, M.D.

*From the Department of Obstetrics and Gynecology, Mirza Kouchek Khan (Women's) Hospital, Tehran University of  
Medical Sciences, Tehran, Islamic Republic of Iran.*

## ABSTRACT

We used the modified one finger laparoscopy technique on 100 patients, and found it to be successful in 87% of cases. No major complication occurred during or after such operations. However, we think that this technique is accompanied by three important problems:

- 1) The CO<sub>2</sub> gas is lost from the subumbilical incision,
- 2) A secondary fascial layer is present in some patients, and
- 3) There is a higher rate of laparoscopic wound complications.

At the present time (in the second phase of the study), by cutting superficially the secondary fascial layer, our success rate has risen to 98%. We close the fascia and skin in separate layers and believe that a similar approach can be used for the peritoneum.

*MJIRI, Vol.2, No.3, 197-200, 1988*

## INTRODUCTION

Laparoscopy is one of the most common operations performed in gynecology centers. On the whole, complications arising from this operation are fewer than 1%.<sup>1</sup> The two blind steps at the beginning of traditional laparoscopy, the use of verres needle and the sharp trocar, in practice, cause more apprehension in gynecologists than complications for the patients. To solve these difficulties, Hasson<sup>2</sup> (1971) introduced an open laparoscopy technique.

The problem with Hasson's technique is that much tissue dissection is needed, and the technique becomes in fact a small laparotomy. As a solution to this problem, Grundsell<sup>3</sup> (1982) described a "Modified Laparoscopy Using a Finger." He used this technique on 26 patients with total success in all of them. In the present article the authors modified the Grundsell technique and used the method on 100 patients.

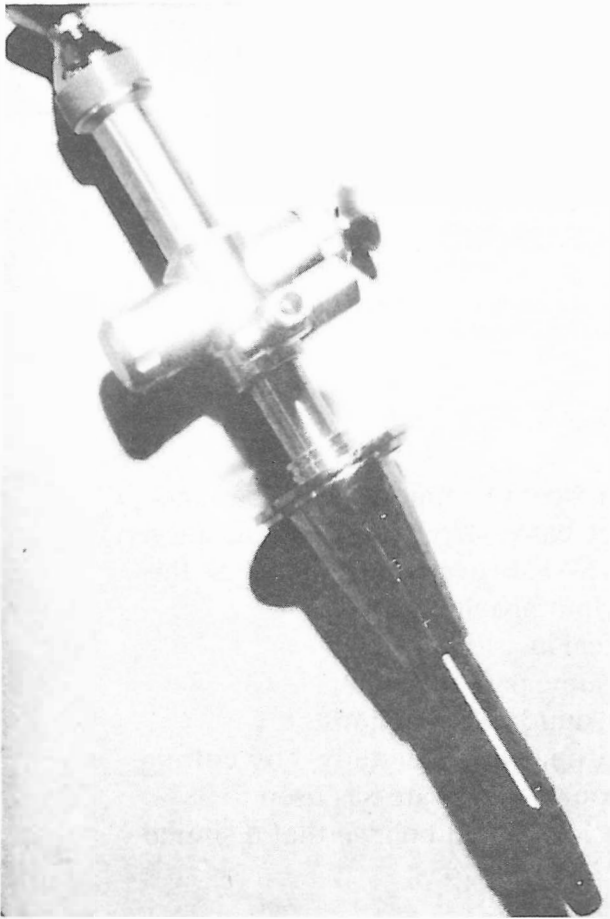
## MATERIALS AND METHODS

One hundred patients under the care of the Department of Gynecology at the Women's Hospital were

operated on using the one finger laparoscopy technique. The patients' ages were between 11 and 52, and their body weight between 32 and 92 kg. We passed through two distinct phases during our study. In the first phase we used the classic Grundsell technique completely and in the second phase we modified this technique to solve the problems we encountered. Like the Grundsell technique we made a semilunar incision in the subumbilical region. With the point of the index finger we carefully dissected subcutaneous fat to the level of the rectus fascia, then incised the fascia longitudinally half a centimeter. With the same finger, we penetrated the fascia and peritoneum and entered the abdominal cavity. After opening the fascia and peritoneum, we introduced the sharp trocar together with its sheath. Insufflation was then begun and finally the laparoscope inserted.

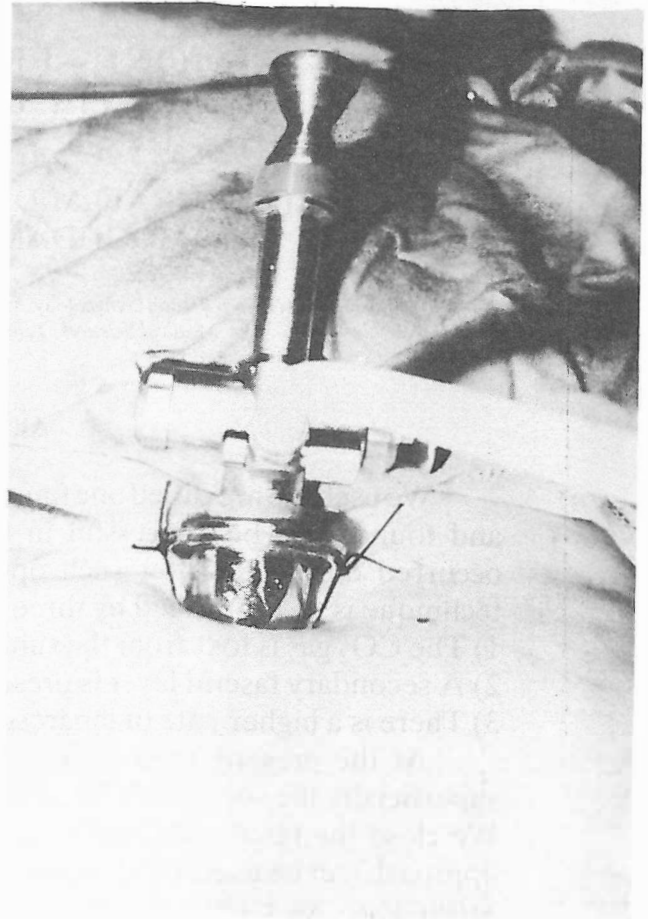
After about 50 laparoscopies with the Grundsell technique we were confronted with two difficulties: 1) the loss of some CO<sub>2</sub> gas from around the sheath of the trocar, and 2) the existence of a secondary fascial layer.

At the beginning of our study we followed Grundsell's advice and used Allis forceps on the lateral margin of the wound to prevent the CO<sub>2</sub> gas from escaping, but soon we observed that this advice did not solve the



**Fig. 1.** The trocar sheath can pass through the cone. In the collar of the cone there is a place for a rubber washer.

problem completely. Also, it restricted the movement of the trocar sheath in a manner that we could not move it to and fro. Thus we decided to use Hasson's trocar and cone to solve this problem. We altered the sharp trocar to a blunt one, and made a special cone so the sheath of the trocar could pass through it (Fig. 1). Hasson said in his article that: "This cone would keep the CO<sub>2</sub> gas in the abdominal cavity, if the surgeon pushed it onto the rectus fascia all the time."<sup>2</sup> We found the following difficulties using the Hasson cone: 1) It was not practical for the surgeon to push the laparoscope against the abdominal wall continuously while he was working. Using Hasson's cone, when we pulled the laparoscope out, we lost some CO<sub>2</sub> gas (the new instruments in open laparoscopy also fix the trocar sheath.<sup>4</sup> 2) To obtain a good view of the pelvic cavity we must move the objective of the laparoscope frequently, and sometimes the sheath of the trocar. In some situations, movement of the trocar sheath can improve our view inside the pelvic cavity, especially when we remember that the distance between the umbilicus and the symphysis pubis is not the same in every patient. so with the aim of keeping the CO<sub>2</sub> gas in the abdomen and



**Fig. 2.** After suturing the cone onto the skin (two other holes will be sutured then).

facilitating movement of the trocar sheath and the objective of the laparoscope, we modified the Hasson cone. In our modified instrument, the trocar sheath passes through a special cone, having a collar for a rubber washer and four holes for suturing it onto the skin of the abdomen (Fig. 2.). After fixing the cone, the trocar sheath can move on it, and at the same time, we can move the laparoscope separately.

In some of our patients, the secondary fascial layer was thick and it was not possible to penetrate it with the finger easily. In 32% of our patients (32 patients) the thickness of this fascia caused difficulty. In the beginning of the study when we were confronted with this problem we changed to the conventional technique of laparoscopy. After some experience, we discovered the fact that the secondary fascial layer was always connected to the rectus fascia at one of its margins (either the right or the left). So, we decided to take both edges of the rectus fascia with Kocher forceps and pull it up, for the purpose of cutting the surface of the secondary fascial layer superficially near its connecting edge with the rectus fascia. It was then possible to complete penetration using the finger. We used this

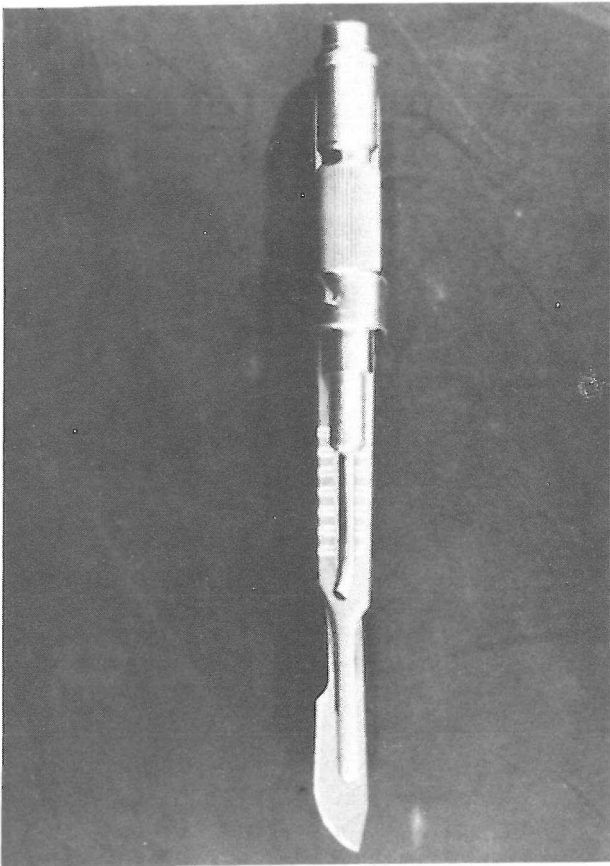


Fig. 3. Modified bistoury with a source of cold light.

method in two patients, and surprisingly, found it very successful. With the use of this technique during the second phase of the study, when we were confronted with this problem we did not change the technique to that of conventional laparoscopy. But, we employed the described modification in total of 10 patients. The use of the scalpel in cutting the secondary fascial layer was found to be both practical and safe. So, now, when we are confronted with the problem of a secondary fascial layer, we use the scalpel for cutting it routinely without hesitation.

For the purpose of obtaining a good view when we are trying to cut the secondary fascial layer in the dark cylindrical space created by the index finger, we have modified the scalpel and attached a source of cold light to its blade (Fig.3).

At the end of the one finger operation we closed the rectus fascia with one suture, then we sutured the subcutaneous fat and skin in separate layers.

## RESULTS

We did not succeed in performing a laparoscopy on one patient with a previous midline scar on the abdo-

men (she had no secondary fascial layer). Under the laparoscopy incision there were adhesions that could be found using the one finger technique. Certainly, if the conventional laparoscopy technique had been used it would have caused injury to this patient. On 13 patients (13%) we did not succeed to perform laparoscopy with the modified one finger technique. In 11 of these patients we could continue the operation with the conventional technique and in two, with open laparoscopy. In 12 of the 13 patients, the cause of failure was the existence of a secondary fascial layer. We solved this problem in the second phase of the study by using the scalpel to cut the secondary fascial layer superficially. In this manner in the second phase of the study, by using the scalpel for incising the rectus fascia and secondary fascial layer, the failure rate of our modified one finger laparoscopy technique is 2%. However, on the whole of the study the failure rate is 13%. The success rate achieved in Grundsell's article is 100%!

The use of the special modified cone has solved the problem of the loss of CO<sub>2</sub> gas in our study.

Thirteen patients (13%) had scars from previous surgery on the abdominal wall. Three of them had adhesions just under the laparoscopy incision.

The heaviest patient in whom the one finger laparoscopy technique was successful weighed 90 kgs.

As we gained more experience, the time required for performing the one finger technique was made considerably shorter. At first, the procedure was rather lengthy, but in the last 13 patients of the study, the average time for performing the technique was reduced to 4 minutes (1-10).

Intraoperative complications utilizing the one finger laparoscopy are very rare. The volume of blood loss from the use of the one finger incision is more than with conventional laparoscopy, but this does not cause any difficulties when viewing the organs in the pelvic cavity.

Postoperation complications are primarily those of laparoscopy wound complications. The incidence of wound infection in our one hundred patients was about (10.7%). From previous experience of the authors in conventional laparoscopy, the complications involving the wound sites in one finger laparoscopy are more than in the conventional technique. The scar tissue of one finger laparoscopy is usually heavier than that of conventional laparoscopy.

## DISCUSSION

Complications due to the use of the verres needle and a sharp trocar are rare but serious. The fear of these complications encourage surgeons to devise new methods to enter the abdomen at the start of laparoscopy. Hasson (1971) introduced the "Open Laparoscopy Technique" as a solution. In a recent article,

Bhiwan Diwala<sup>5</sup> compared conventional laparoscopy with open laparoscopy.

The main problem of open laparoscopy is that much tissue dissection is required. However, the one finger laparoscopy technique has the advantages of open laparoscopy, and, at the same time omits the need for excessive tissue dissection.

The problem of the loss of CO<sub>2</sub> gas in one finger laparoscopy in our experience is much more important than Grundsell has mentioned. We had modified Hasson's cone so that it can be securely sutured to the skin and the laparoscope and the trocar sheath can be moved either together or independently. We believe this modification in the one finger laparoscopy technique has solved the problem of the loss of CO<sub>2</sub> gas.

Another problem of the one finger technique is the existence of a secondary fascial layer in some patients. It is very surprising to us that Grundsell did not mention this problem at all in his article. However, this may be due to inherent differences in the ethnic origins of the women involved in the two studies. Nevertheless, we solved this problem as previously described by incising the secondary fascial layer superficially. In our experience, this modification has proved to be very safe and has not caused any problem.

Closing of the rectus fascia at the end of the operation makes this technique more anatomical than conventional laparoscopy. In our opinion the finger hole in the rectus fascia is too large to be left unsutured. Certainly, by closing the rectus fascia, the possibility of obstructive occlusion<sup>6</sup> or dehiscence following laparoscopy<sup>7</sup> will not exist. We always suture the rectus fascia and the skin separately, in contrast to Grundsell who only closes the skin.

The existence of scar tissue from previous abdominal surgery cause apprehension when we use conventional laparoscopy. In our opinion, when there is a scar on the abdominal surface of the patient, especially when this scar may follow the midline, one finger laparoscopy should be the technique of choice. However, the existence of scar tissue is not the only indicator of adhesion and we now use this technique in all cases when we suspect adhesions (such as patients suspected of having abdominal tuberculosis).

In some medical centers special instruments for laparoscopy in children cannot be found. In this situa-

tion, we suggest the use of one finger laparoscopy technique with adult instruments. The youngest patient in our study of 100 patients was 11 years old. The one finger laparoscopy technique is also preferable in the case of pelvic tumors (or puerperal tubal ligation). When the tumor is quite large and we are worried about piercing it with the sharp trocar or the verres needle, one finger laparoscopy eliminates this risk.

We believe the potential complications due to one finger laparoscopy from the point of subumbilical wound infection are more than with conventional laparoscopy.

Recently, we have begun to close the peritoneum in the modified one finger laparoscopy technique. We believe this to be a practical step, which eliminates the possibility of epiploon adhesion under the wound.

In some of our patients who had laparotomy after one finger laparoscopy technique, we observed these adhesions. Presently, we have no knowledge about the possibility of adhesion formation under the site of one finger laparoscopy, and at the same time we have no knowledge about repeat laparoscopy at the site of a previous one finger scar.

On the whole, we can say that the "Modified One Finger Laparoscopy Technique" eliminates the use of "Open Laparoscopy"<sup>2</sup> in nearly 100% of cases.

### REFERENCES

1. Samuelsson S, Sjovall A: Complications and the prophylaxis against complications in gynecological laparoscopy. *Lakartidningen*. 70:2570, 1973.
2. Hasson HM: Open laparoscopy: a modified instrument and method for laparoscopy. *Am.J.Obstet. Gynecol.* 110:886, 1971.
3. Grundsell H, Larsson G: A modified laparoscopy entry technique using a finger. *Obstet. Gynecol.* 59:509, 1982.
4. Leventhal JM: Laparoscopy in female infertility. *Current problems in Obstetrics, Gynecology and Fertility, Volume IX, No. 4*, page 211, 1986.
5. Bhiwan Diwala PP, Mumford SD, Kennedy KI: Comparison of the safety of open and conventional laparoscopic sterilization. *Obstet. Gynecol.* 66:391, 1985.
6. Schiff I, Naftolin F: Small bowel incarceration after uncomplicated laparoscopy. *Obstet. Gynecol.* 43:674.
7. Bishop HL, Halpin TF: Dehiscence following laparoscopy: report of an unusual complication. *Am.J. Obstet. Gynecol.* 116: 585, 1973.