

# THE SYNDROME OF DIABETES INSIPIDUS, DIABETES MELLITUS, OPTIC ATROPHY, DEAFNESS, AND ATONIA OF THE URINARY TRACT (DIDMOAD SYNDROME). TWO AFFECTED SIBS AND A SHORT REVIEW OF THE LITERATURE

DAVOOD SHARIFI DOLOUI, M.D.\* AND ATAOLLAH BEHROUZ  
AGHDAM, M.D.\*\*

From the Department  
University of Medical Sciences, Mashhad, Islamic Republic of Iran.

of Gastroen

## ABSTRACT

Two brothers with DIDMOAD syndrome are reported. The older brother has diabetes mellitus (type I), diabetes insipidus, optic atrophy, deafness and atonia of the urinary tract with severe symptoms such as diabetic ketoacidosis and frequent urinary tract infections. His younger brother had the same manifestations but with less severity. We report the findings of our two patients and compare them with the frequency of the symptoms in 100 patients from the literature.

*MJIRI, Vol.2, No.2, 149-154, 1988*

## INTRODUCTION

DIDMOAD syndrome (Wolfram syndrome) is a rare syndrome. Until 1982 only 100 cases had been reported all over the world.<sup>10</sup> We report two sibs with DIDMOAD syndrome; a 21 year old male with diabetes mellitus (type I), diabetes insipidus, optic atrophy, inner ear deafness and atonia of the efferent urinary tract; and his 14 year old brother with the same problems but with less severe manifestations. Atonia of the urinary tract is not represented in the acronym and was established in both of our patients. We therefore report here the findings of our two patients and compare them with the frequency of symptoms in 100 patients from the literature.

## CASE REPORT

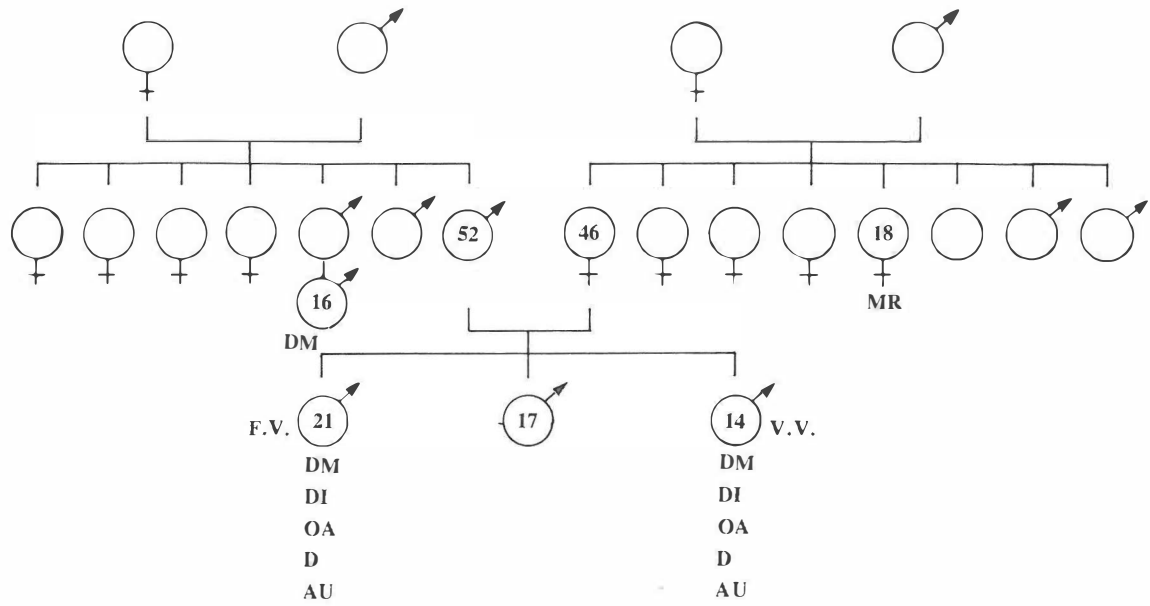
### Case one

A 21 year old male was admitted because of polydipsia and polyuria. He is the product of a normal pregnancy and delivery. The nonconsanguineous parents are healthy. There is no diabetes insipidus, reduction of

visual acuity, deafness and atonia of the urinary tract in the family history, but type I diabetes mellitus exists in one of his paternal cousins, and his youngest maternal aunt is mentally retarded (Fig. 1). When the patient was 3 years old, diabetes mellitus was diagnosed. He was receiving lente insulin (Novo Copenhagen) 40 units daily and had several episodes of diabetic ketoacidosis and coma. Fasting blood glucose ranged between 60 mg/dl (3.33mmol/lit) to 540 mg/dl (30mmol/l) and the mean blood glucose was 190.64 mg/dl (10.59 mmol/l). He had diabetes insipidus since age 14 and had used vasopressin (DDAVP/Desmopressin nose drops). When he receives both insulin and vasopressin he is favorably free of polydipsia and polyuria, and with discontinuation of either insulin or vasopressin, the pertaining symptoms reappear. Visual acuity was markedly diminished in both eyes.

He had colour blindness, indicating primary optic atrophy. Fundoscopy of both eyes revealed bilateral optic atrophy, but no diabetic retinopathy. An audiogram indicated bilateral high tone sensorineural hearing loss (Fig.2). Urinalysis was positive for sugar and in culture of the urine, *E. coli* and *K.pneumoniae* were

## Didmoad Syndrome

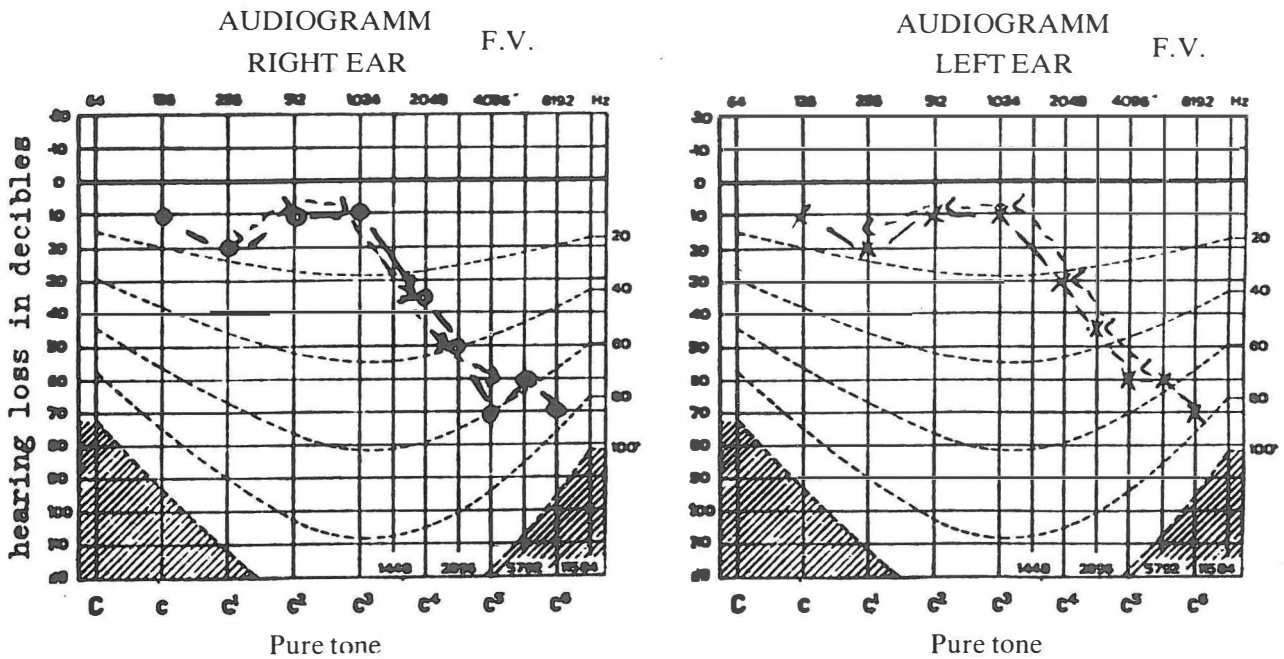


**Figure 1.** Pedigree of the patients.  
 DM= diabetes mellitus. DI= diabetes insipidus. OA = Optic atrophy. D= deafness. AU= atonia of the efferent urinary tract, MR= mental retardation.

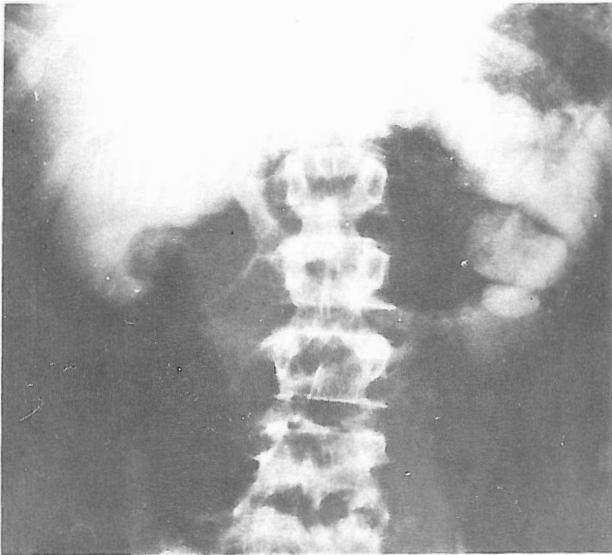
obtained with a colony count of more than 100,000 per mm<sup>3</sup>. He was treated with several antibiotics. During use of vasopressin, urinary specific gravity was normal; in its absence the specific gravity decreased. On intravenous pyelography (Fig.3) the renal pelvices, calyces, as well as the ureters were markedly dilated, and the urinary bladder was enlarged, i.e. severe bilateral hydronephrosis. The patient was dis-

charged with 50 units of lente insulin daily, advised to use vasopressin nose drops and perform urinalyses regularly for detection of urinary tract infection.

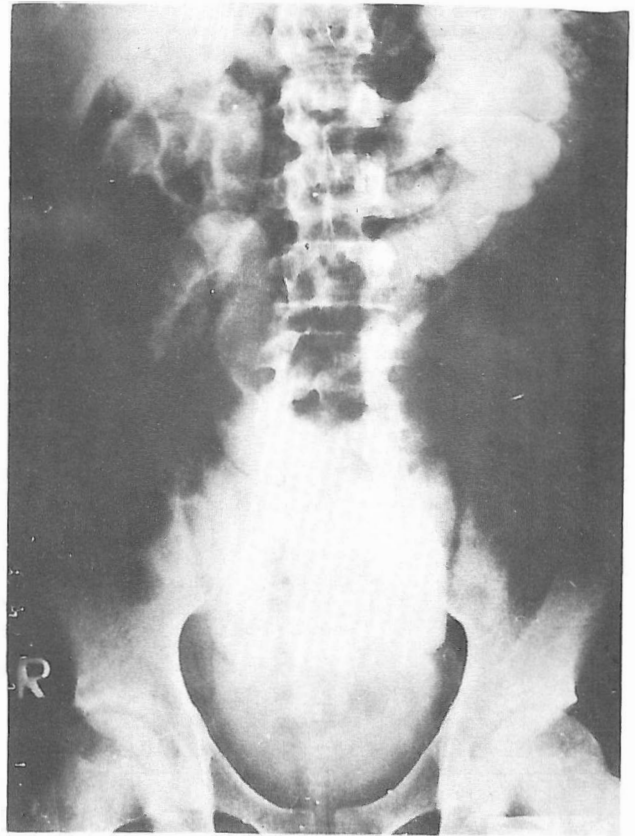
After the first admission the patient was readmitted three times with chills and fever due to urinary tract infection, most recently in Nov., 1987. The visual acuity on the final admission was severely impaired.



**Figure 2.** The audiogram of patient one, indicating sensorineural hearing loss.



A



B

Figure 3. The intravenous pyelogram (IVP) of patient one, showing severe hydronephrosis (A), and bilateral hydroureteronephrosis (B).

**Case two**

A 14 year old boy, the younger brother of case one (Fig. 1), was admitted because of uncontrolled diabetes mellitus and also for investigation of DIDMOAD syndrome. He had diabetes mellitus since the age of 4

and had three episodes of diabetic ketoacidosis. He received 30 units of lente insulin (Novo Copenhagen). His fasting blood glucose ranged between 81 mg/dl (4.50 mmol/l) and 360 mg/dl (20 mmol/l) and the mean blood glucose (MBG) was 241.7 mg/dl (13.42 mmol/l).

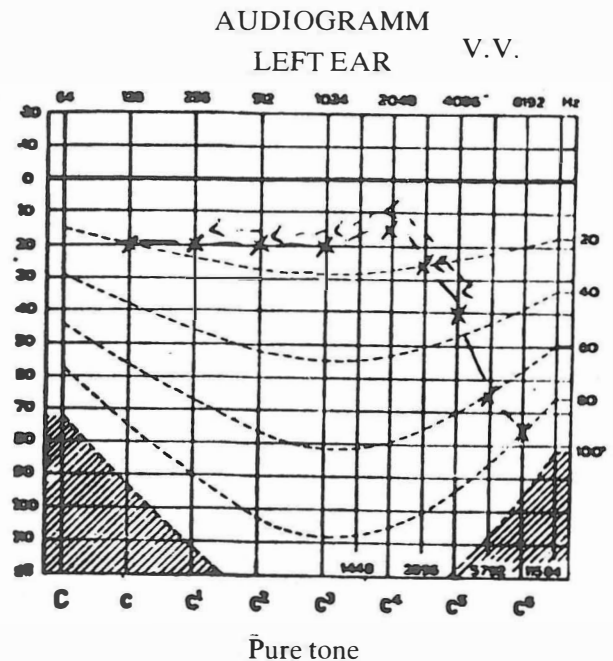
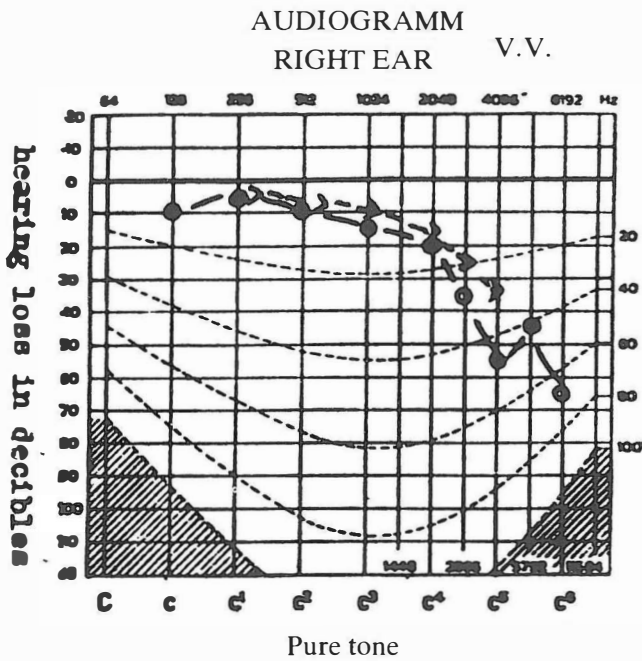


Figure 4. The audiogram of the second patient, indicating sensorineural hearing loss.

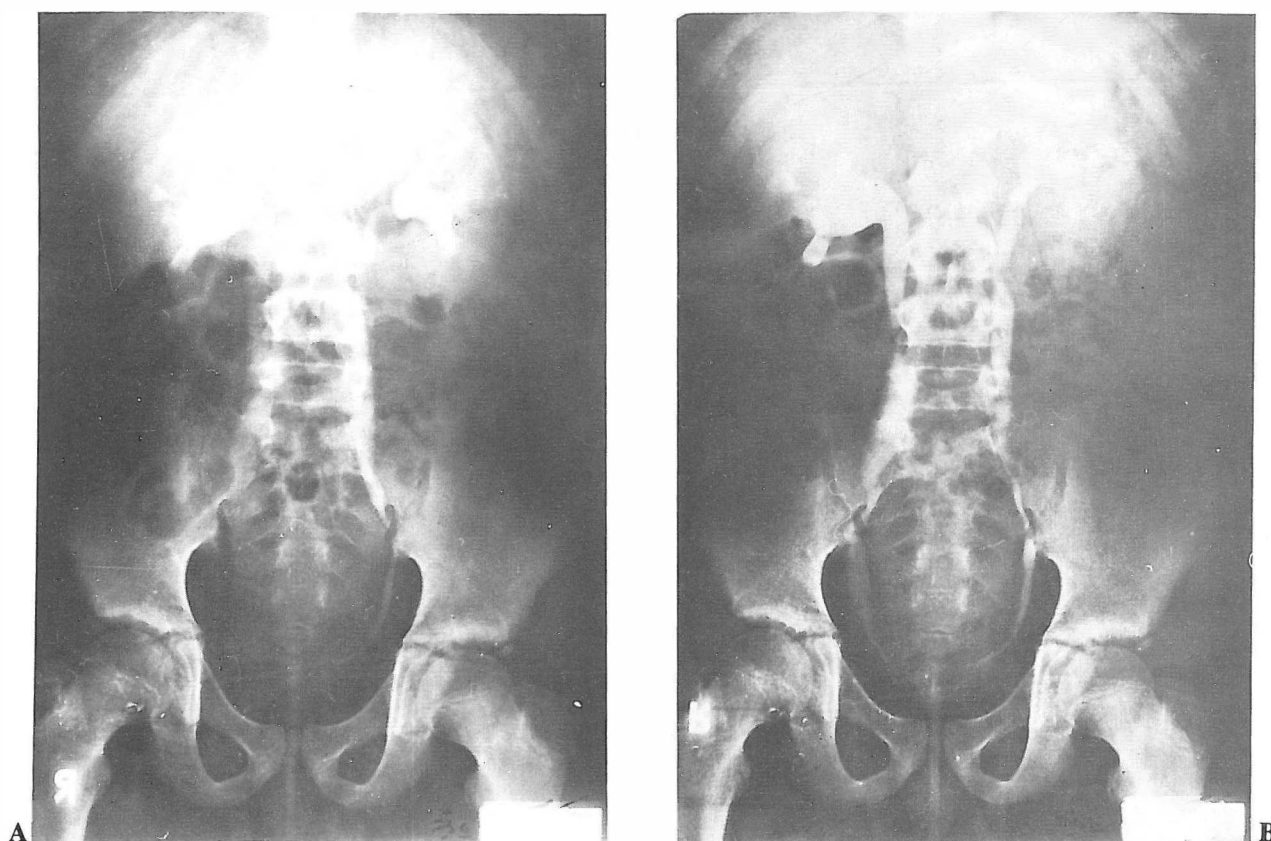


Figure 5. The IVP of the patient, showing mild hydronephrosis (A), and bilateral hydroureteronephrosis (B).

He also had diabetes insipidus. Similar to his brother, when he uses both insulin and vasopressin nose drops, polydipsia and polyuria cease. Vision in both eyes was decreased. He had colour blindness also, again indicating primary optic atrophy.

Fundoscopy of both eyes revealed bilateral optic atrophy but no diabetic retinopathy. Audiogram showed bilateral high tone sensorineural hearing loss (Fig.4). He had glycosuria which was later controlled with lente insulin. Urine culture was negative. On intravenous pyelography (Fig.5), calyces as well as ureters were dilated.

After discharge, the patient had frequent referrals for bouts of urinary tract infection, which were managed favorably. The vision had deteriorated as compared with the first admission.

A third brother, age 17, was admitted and thoroughly investigated. His blood glucose tolerance test, fundoscopy, audiometry, urinalysis and IVP all were within normal limits.

## DISCUSSION

In 1938, Wolfram first described the presence of juvenile diabetes mellitus and slowly progressive atro-

phy of the optic nerve in siblings.<sup>28</sup> In 1950, Cooper, et al, pointed out that this syndrome can be associated with diabetes insipidus, atonia and dilatation of the efferent urinary tract and perceptive hearing loss.<sup>5</sup> These authors emphasized an autosomal recessive mode of inheritance for this syndrome, which later came to be called DIDMOAD syndrome, an acronym for Diabetes Insipidus, Diabetes Mellitus, Optic Atrophy and Deafness.<sup>10</sup> Until 1977, ninety eight cases of the DIDMOAD syndrome were reported.<sup>1-4,6-9,11-19,21-23,25-27</sup> In 1982, two more patients were added to the previous reports by Dreyer, et al, and the total cases reached 100.<sup>10</sup>

The frequency of the major symptoms of DIDMOAD syndrome in these cases are tabulated and compared to findings in our patients (Table I).

The onset of the various features of the syndrome is not constant. Type I diabetes mellitus is the most frequent and commonly the first symptom in patients with DIDMOAD syndrome, the average age of onset being 7 years.<sup>10,22</sup>

Decrease in visual acuity usually remains undetected for sometime and is found in 98% of the patients. It begins in the first two decades of life (mean 11 years) and gradually progresses. Diabetic cataract reported by one author<sup>10</sup> is a rare ocular finding.<sup>24</sup> If optic

**Table 1. Incidence of different symptoms found in 100 reported cases of DIDMOAD Syndrome as compared with our patients F.V. and**

	Incidence reviewed in 100 cases	F.V.	V.V.
Diabetes mellitus	100	+	+
Optic atrophy	98	+	+
Deafness (or abnormal audiogram)	48	+	+
Atonia of the urinary tract	46	+	+
Diabetes insipidus	34	+	+

atrophy is recognized in a diabetic patient, audiometry and intravenous pyelography should be performed. Optic atrophy however may be the presenting feature,<sup>23</sup> but it is not associated with retinitis pigmentosa as is the case in other hereditary syndromes e.g. Laurence-Moon-Biedl syndrome. The optic atrophy is of the primary type, early cases showing only loss of blue appreciation while more advanced cases have complete color blindness with severe loss of visual acuity.<sup>22</sup> Diabetes insipidus develops in the first three decades of life (mean age 14 years), and is reported to be vasopressin-sensitive. As vasopressin is elaborated by the cells of the supraoptic hypothalamic nuclei, the diabetes insipidus must represent a progressive degeneration of these hypothalamic cells or of the supraoptico-hypophyseal tract.<sup>22</sup>

In 48% of the patients, inner ear hearing loss, mainly of high frequencies was detected often without subjective complaints. This symptom starts in the first three decades of life (mean 16 years) and progresses but only a few patients become completely deaf. Atonia of the efferent urinary tract is more frequent than diabetes insipidus.<sup>10</sup> Many of the reported cases have had urinary tract abnormalities ranging from atonic bladder to hydronephrosis and hydroureter.<sup>16</sup>

It seems difficult to relate the symptoms of this autosomal recessively inherited syndrome to a single pathogenic mechanism. However a progressive degeneration of basal ganglia could be a common denominator.<sup>10</sup> An interesting hypothesis on the relation between central nervous system disturbances and diabetes emphasizing the role of enkephalins was proposed by Pyke.<sup>20</sup> This points to the DIDMOAD syndrome as a most interesting, genetic model of a pathogenic principle in diabetes which awaits further clarification.<sup>20</sup>

The long term prognosis of a patient with DIDMOAD syndrome is determined by complications of diabetes mellitus and renal failure in consequence of atonia of the efferent urinary tract associated with repeated urinary infections.<sup>8</sup> For this reason, the urinary tract should be kept carefully under observation in patients with diabetes mellitus and optic atrophy. Like others,<sup>10</sup> we also believe under clinical and genetic

aspects that this syndrome of diabetes insipidus (DI), diabetes mellitus (DM), optic atrophy (OA), deafness (D) and atonia of the efferent urinary tract (AU), is not adequately designated by enumerating only four symptoms (DIDMOAD) instead of five (DIDMOADAU).

## REFERENCES

- 1- Anoussakis C, et al: Juvenile diabetes mellitus with optic atrophy. *Delt Paediat Klin Panep Athin*, 19: 263, 1972.
- 2- Barjon P, Lestraddet H, Labauge R: Atrophie optique primitive et surdit  neurog ne dans le diab te juv nile. (A Propos de trois observations) *Presse Med* 72; 983-6, 1964.
- 3- Bonnet M, et al: Atrophie optique et surdit  de perception chez l'enfant diab tique. *Bull Soc Ophthalmol Soci t  Lyon*. 82: 836, 1969.
- 4- Bretz GW, Baghdassarian A, Graber JS, et al: Coexistence of diabetes mellitus and insipidus and optic atrophy in two male sibs. *Studies and review of literature. Amer J Med* 48: 398-403, 1970.
- 5- Cooper IS, Rynearson EH, Bailey AA, and MacCarty CS: The relation of spinal cord diseases to gynecomastia and testicular atrophy. *Proc. Staff Meet., Mayo Clin* 25: 320-6, 1950.
- 6- Cordier J, et al: Atrophie optique familiale et diab te juv nile. *Rev Otoneuroophthal* 42: 269, 1970.
- 7- Gouzl L: Atrophie optique primitive et surdit  de perception chez un enfant diab tique. *Bull Soc Ophthalmol Soci t  Lyon*, 82: 840, 1967.
- 8- Cremers CWRJ, Wijdereld PGAB, Oinckers AJL: Juvenile diabetes mellitus, optic atrophy, hearing loss, diabetes insipidus, atonia of the urinary tract and bladder, and other abnormalities (Wolfram syndrome). A review of 88 cases from the literature with personal observations on 3 new patients. *Acta Paediatr Scand (Suppl)* 264: 1-16, 1977.
- 9- Demailly P, Derot M, Rougerie J: Atrophie optic primitive chez l'enfant diab tique. A propos de deux observation. *Bull Soc Ophthalmol Fr* 82:29, 1969.
- 10- Dreyer M, R diger HW, Bujara K, et al: The syndrome of diabetes insipidus, diabetes mellitus, optic atrophy, deafness, and other abnormalities (DIDMOAD-Syndrome). Two affected sibs and a short review of the literature (98 cases). *Klin Wochenschr* 3:60 (9): 471-5, 1982.
- 11- Goddon R, Longin B, Mamelle JC, Jilly R, et al: Association de diab te sucr , polyurodipsis et troubles sensoriels. *Pediatrie* 28: 429-45, 1973.
- 12- Gunn T, Bortolussi R, Little JM, et al: Juvenile diabetes mellitus, optic atrophy, sensory nerve deafness, and diabetes insipidus-a syndrome. *J Pediatr* 89 (4): 565-70, 1976.
- 13- Ikkos DG, Fraser GR, Matsouki-Gavra E, et al: Association of juvenile diabetes mellitus, primary optic atrophy and perceptive hearing loss in three sibs, with additional idiopathic diabetes mellitus insipidus in one case. *Acta Endocr (kopenhagen)* 65: 95-100, 1970.
- 14- Jean R, et al: Association diab te sucr , trouble sensoriel, diab te insipide chez deuz enfant d'une m me fratrie. *Rev Pediatr* 6: 293, 1970.
- 15- Laffay G, Lestradet H: Diab te juv nile et atrophie optique primitive. *Sem Hop Paris*, 50: 127-41, 1974.
- 16- Moore JR, MacGregor ME: Juvenile diabetes mellitus, diabetes insipidus and neurological abnormalities. *Proc R Soc Med* 64: 730, 1971.
- 17- Najjar SS, Mahmud J: Diabetes insipidus and diabetes mellitus in a six-year-old girl. *J Pediatr* 73: 251-3, 1968.
- 18- Niemeyer G, Marquardt JL: Retinal function in a unique syndrome of optic atrophy, juvenile diabetes mellitus, diabetes insipidus, neurosensory hearing loss, autonomic dysfunction and

## Didmoad Syndrome

- hyperalanineuria. *Invest Ophthalmol* 11: 617-24, 1972.
- 19- Page MM, Smith RB, Watkin PJ: Recessive inheritance of diabetes: the syndrome of diabetes insipidus, diabetes mellitus, optic atrophy, and deafness. *Q J Med* 96 (179): 505-20, 1976.
  - 20- Pyke DA: Diabetes: The genetic connections. *Diabetologia* 17: 333-43, 1979.
  - 21- Raiti S, Plotkin S, News GH: Diabetes mellitus and insipidus in two sisters. *Br Med J*, 2: 1625-9, 1963.
  - 22- Richardson JE, Hamilton W: Diabetes insipidus, diabetes mellitus, optic atrophy, and deafness. 3 cases of «DIDMOAD» syndrome. *Arch Dis Child* 52: 796-8, 1977.
  - 23- Rorsman G: Optic atrophy and juvenile diabetes mellitus with familial occurrence. *Acta Med Scand* 182: 419, 1967.
  - 24- Shaw DA, Duncan JP: Optic atrophy and nerve deafness in diabetes mellitus. *J Neurol Neurosurg Psychiat* 21 (1): 47-9, 1958.
  - 25- Stevens PR, MacFadyen WAL: Familial incidence of juvenile diabetes mellitus, progressive optic atrophy, and neurogenic deafness. *Brit J Ophthalm* 56: 496-500, 1972.
  - 26- Stoppoloni G, Pierantoni G, Pacelli V: Two children with diabetes insipidus and diabetes mellitus. [letter] *Lancet* 2: 1425, 1969.
  - 27- Sunder JH, et al: Pedigree with diabetes insipidus, diabetes mellitus and optic atrophy. *J Med Genet* 9: 408, 1972.
  - 28- Wolfram DJ: Diabetes mellitus and simple optic atrophy among siblings: report of four cases. *Mayo Clin Proc*, 13: 715, 1938.