

AMNION GRAFT TECHNIQUE IN A PATIENT WITH CONGENITAL ABSENCE OF VAGINA WITH REGULAR MENSES THROUGH A FISTULA

HORMOZ DABIRASHRAFI, M.D., SEYYEDEH SHAHRBANOU
JANANI, M.D., HASSAN VAHAB AGHAI, M.D., AND NASRIN
MOGHDAMI TABRIZI, M.D.

*From the Department of Obstetrics and Gynecology, Mirza Kouchek Khan (Zanan) Hospital, Tehran University of
Medical Sciences, Tehran, Islamic Republic of Iran.*

ABSTRACT

An interesting case of atresia of the vagina and cleft palate is described, with menstruation occurring through a fistula. Normal saline was used for distension of the upper vagina, without any successful results. Therefore, the McIndoe operative technique with amnion graft was utilized. Eight months after the operation, the patient has a normal menstrual cycle, a good caliber neovagina and normal coitus. She hopes for a future pregnancy.

MJIRI, Vol.2, No.2, 155-158, 1988

INTRODUCTION

Vaginal agenesis from birth to two years old is estimated to occur in one out of every 4000 to 10,500 female infants.^{1,2} Of these infants afflicted, seven to eight percent have a functioning uterus that undergoes cyclic growth and degeneration of the endometrium.^{3,4} Although vaginal agenesis is a relatively common disorder, vaginal agenesis with a functioning uterus is rarely encountered in clinical practice. Rarer still is vaginal agenesis with a functioning uterus, in which menstrual flow egresses from a fistulous tract to the introitus.

One such patient has been reported by Rulin, et al.⁵ He described a technique that greatly simplified reaching a successful solution to the patient's problem. His work suggests that considering the innate distensibility of the vagina, 100 ml of normal saline can be used to distend the entire space between the rectum and bladder down to the introitus. We used this technique on our patient and the following is the result of experience.

CASE REPORT

A 24 year old female, G=0, P=0, Ab=0, presented to the Zanan Hospital in Tehran, complaining of

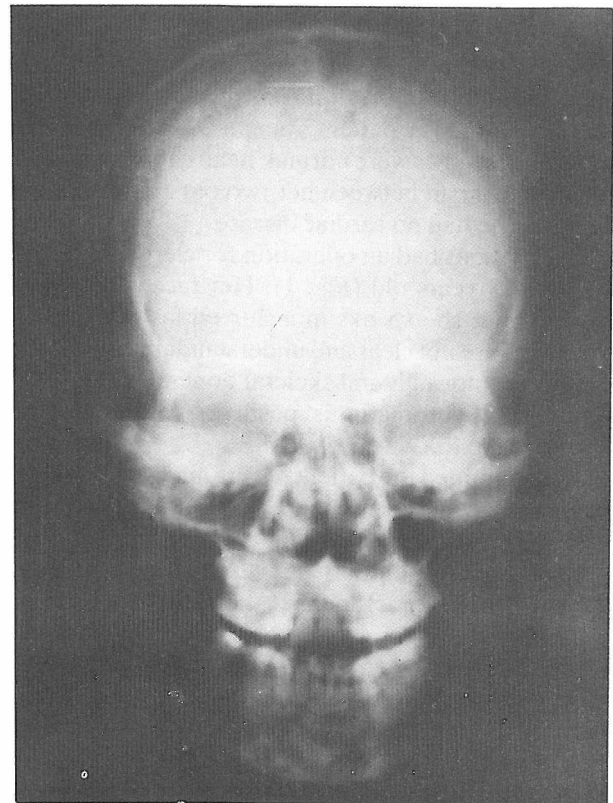


Figure 1. The skull X-ray of the patient, eleven years after operation for cleft palate.

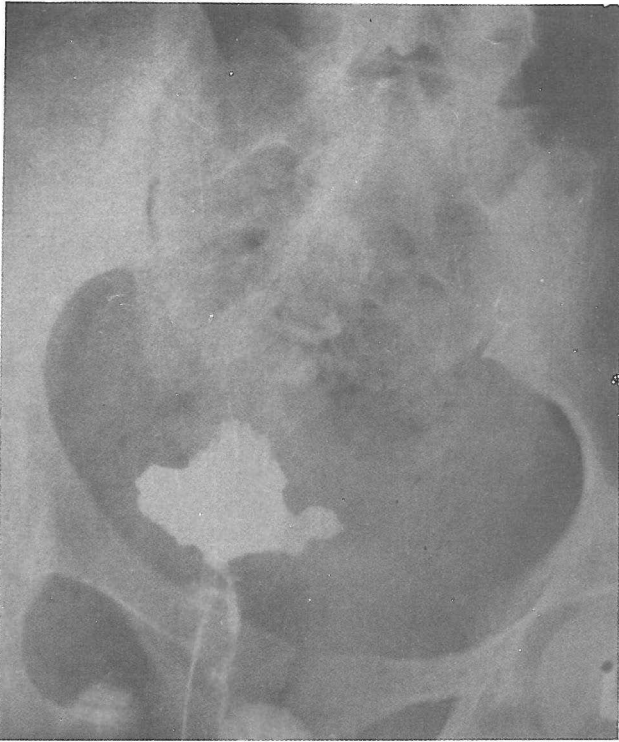

Figure 2. The narrow fistulous tract and open upper vagina after vaginography.

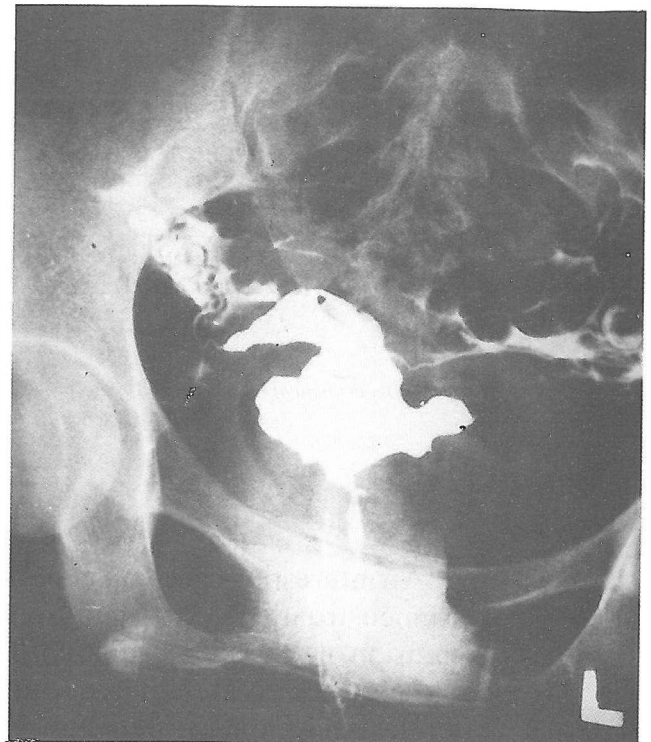


Figure 3. With injection of radiopaque solution, the uterus and both tubes were visualized.

difficulty in coitus and infertility. She had married five years previously. Eight years ago, after a simple operation (with diagnosis of hematocolpos), menarche occurred and from that time on, she had normal cyclic menstruation. The patient's height was 152 cm, weight was 45 kg, breasts were normal, head circumference 54 cm and the span between her two outstretched hands 148 cm. She had no cardiac disease.

The patient had an operation for cleft palate when she was 13 years old (Fig. 1). Her face is somewhat asymmetric, she speaks in a slurred fashion and her sentences are not clear and understandable. Excretory urogram is normal, and skeletal bones are normal on X-ray. Sex chromatin is positive (35%), and her karyotype is 46XX.

We examined the patient during menstruation. The blood came from an opening at the right and below the urethral meatus. By using renographin, we performed a vaginohysterography (Figs. 2-3). Firstly, a cavity filled with dye (Fig. 2) and then the uterus and the tubes were visualized (Fig. 3).

For instillation of normal saline, we chose the blunt inside of the Veres needle, used for CO₂ injection purposes in laparoscopy. The needle was checked to determine whether or not it was inside the vaginal cavity. Roentgenography was used for this purpose. (Fig. 4).

Under general anesthesia, we inserted the blunt

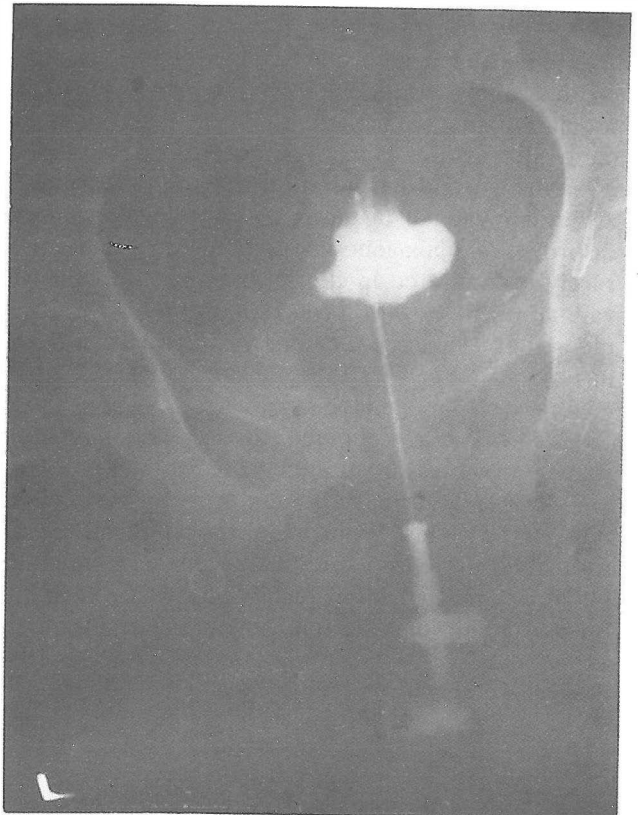


Figure 4. The top of the blunt inside of the Veres needle is in the open upper portion of the vagina.

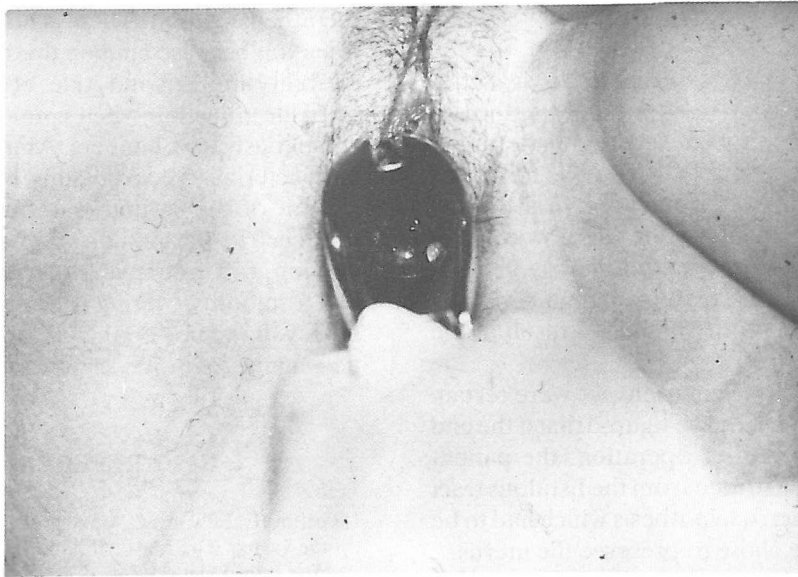


Figure 5. Examination of the patient at the time of menstruation, after operation.

inside of the Veres needle into the fistulous tract onto the collapsed vagina, which was then injected with saline solution tinged with methylene blue. After injection of 60 ml of fluid, a mass formed in the upper vagina that was easily palpable on rectal examination. Surprisingly, contrary to the case of Rulin, et al, when we increased the volume of injected normal saline, the fluid began to escape from around the needle. We used a purse string suture around the needle in the introitus, but no significant improvement was seen and the fluid continued to leak out with the increasing pressure in the vaginal cavity. It is interesting to note that when we applied pressure to the tissue of the fistulous tract by finger and then injected the fluid, it did not leak out of the fistulous opening into the introitus, but at the same time, the upper vaginal mass did not feel larger than the cavity with 60 ml of normal saline. Therefore, the cavity was not in normal anatomical contact with the introitus. As a result, we ended the operation and decided to reoperate at a later date.

Seven days later, we decided to perform a perineoabdominal operation to connect the uterus to the vagina. We made a canal between the bladder and rectum (the fistulous tract remained intact), then we opened the abdomen to guide the uterus to the vagina. When we opened the abdomen, we saw what resembled a very recent intraabdominal infection. The intestines were adhered to each other and to the uterus. In our opinion, we felt the infection was due to the injection of solution. But which solution, renographin or normal saline?

We found remnants of blood in the fallopian tube (hematosa

had not previously completely discharged because of the narrow fistulous tract, and it is known that in this situation, patients are susceptible to infection. After releasing the adhesions, we again inserted the Veres needle into the fistulous tract and injected normal saline with methylene blue. It was very interesting to see that when the fluid pressure rose, the solution emptied from the uterus via the tube into the abdomen. It was then we realized why the vaginal mass did not come to open into the introitus. With the insertion of a no. 5 Hegar dilator into the uterus from above and guided inferiorly from the cervix, we located the position of the vagina, and the vagina was opened in that area. A special cone (similar to Bate's cone)⁶ covered with amnion (amnion covered the cone and its narrow tip) was then inserted into the neovagina with the tip in the upper vaginal remnant.

Seven days later, we removed the cone and a rubber cone was inserted with a condom sheath covering. The amnion was not rejected. The patient used this cone continuously for 18 days, except for defecation. During the 25 days after the operation, she menstruated from the neovagina. We took a smear on the 20th day postoperatively and performed a biopsy on the 30th day to see the results. The epithelium of the neovagina was stratified squamous. The patient now menstruates regularly and we look forward to her future pregnancy (Fig. 5). She was reexamined at a later date after the operation. Her vagina was quite satisfactory with 8 cm length and 4 cm width. She said coitus is now without difficulty. Interestingly enough, she menstruates from the neovagina and the fistulous tract simultaneously.

DISCUSSION

Several cases of vaginal agenesis with cervical atresia have been published.^{7,8} In these reports, the authors made an attempt to conserve the uterus by creating an opening in the atretic cervix and forming a vagina by a modified McIndoe procedure. In all but one report, the patient who underwent these procedures had a series of complications that ultimately necessitated a hysterectomy. One patient in the series by Niver, et al.⁹ died from septic shock as a result of the operation.

In our patient, after hystero-graphy we were certain that she had a cervix. Besides, we figured that if the end of the neovagina closed after operation, the patient could probably still menstruate from the fistulous tract that had remained intact; a hypothesis which had to be proven later. Thus, we chose to preserve the uterus.

Rulin⁵ has described a patient similar to our case. He emphasizes the innate distensibility of the vagina and points out that when the upper vagina is distended, surgical correction becomes very simple. We tried his technique but did not succeed in the operation. When the pressure was increased in the upper cavity, the fluid poured out from the fistulous tract or leaked from the fallopian tubes into the abdomen. Thus we think that the success of Rulin's technique depends on the severity of vaginal atresia.

After laparotomy and seeing the bowel adhesions, we no longer recommend hystero-graphy or normal saline injection. We believe these patients have a partial hematometra and increased susceptibility to infection. When we failed to succeed with Rulin's technique, we remembered Musset's advice: "The surgical procedure must be tailored to fit the individual situation and no standard operative procedure can be developed to satisfy all clinical situations."¹⁰

Human amnion is a readily available cost-free protective biologic dressing and is thought to promote

reepithelialization. There is no problem with immune rejection because amnion does not express histocompatibility antigens and Akle, et al.¹¹ found no evidence of tissue rejection when amnion was implanted subcutaneously in volunteers. Amnion appears to have an antibacterial effect, possibly by achieving cover and closure of the wound. Enzymes, such as lysozyme, produced by the amnion may be bactericidal. We used amniograft in our patient successfully. The neovagina had a smooth covering with good caliber. Smear and biopsy show good epithelialization of the surface of the neovagina.

REFERENCES

- 1) Griffin JE, Edwards C, Madden JD, et al: Congenital absence of the vagina. The Mayer-Rokitansky-Kuster-Hauser Syndrome. *Ann Intern Med* 85:224, 1976.
- 2) Evans TN, Poland ML, Boving RL: Vaginal malformation. *Am J Obstet Gynecol* 141:910, 1981.
- 3) Salvatore CA, Lodovici O: Vaginal agenesis: an analysis of ninety cases. *Acta Obstet Gynecol Scand* 57:89, 1978.
- 4) Solomons E: Conception and delivery following construction of an artificial vagina: report of a case. *Obstet Gynecol* 7:329, 1956.
- 5) Rulin MC, Yoder DA, Hayashi TT: Congenital atresia of the lower vagina with regular menses through a fistula: a therapeutic approach. *Obstet Gynecol* 65:885, 1985.
- 6) Bates GW, Wiser WL: A technique for uterine conservation in adolescents with vaginal agenesis and a functional uterus. *Obstet Gynecol* 66:290, 1985.
- 7) Williams B: Congenital cervical and vaginal atresia. *J Obstet Gynecol Br Common W* 70:301, 1963.
- 8) Maciulla CJ, Heine MW, Christian CD: Functional endometrial tissue with vaginal agenesis. *J Reprod Med* 2:373, 1978.
- 9) Niver DH, Barrette G, Jewelewicz R: Congenital atresia of the uterine cervix and vagina: three cases. *Fertil Steril* 33:25, 1980.
- 10) Musset R, Poitout P, Truc JB, et al: Aplasie vaginale avec uterus fonctionell, Resultats operationes et commentaries: a propos de 10 observations. *J Gynecol Obstet Biol Reprod* 7:316, 1978.
- 11) Akle CA, Adinolfi M, Welsh KI, et al: Immunogenicity of human amniotic epithelial cells after transplantation into volunteers. *Lancet* II: 1003, 1981.