

SUPRAVESICAL DIVERSION AND LATER UNDIVERSION IN SEVERE WAR INJURIES OF THE BLADDER

M. SEDEHI, R. ASGHARIEH, Y. HOSEINI AND
R. KHORASANIZADEH

*From the Department of Urology, Shahid Modarress Hospital, Shahid Beheshti University of Medical Sciences,
Tehran, Islamic Republic of Iran*

ABSTRACT

From 20 patients with bladder injury due to war trauma, three patients were in critical condition because of extensive bladder injury associated with rectosigmoid injury and septicemia. In these three patients, early supravescical diversion was undertaken using ileal conduit. After stabilization of the patients' condition, undiversion was performed successfully, bringing the patients back to their normal voiding condition.

MJIRI, Vol.2, No.1, 19-23, 1988

INTRODUCTION

The accepted method in management of bladder injuries is primary repair with drainage.¹ There are however some cases of lower genitourinary trauma in which primary repair is impossible either due to the patient's general condition or due to extensive injury associated with rectosigmoid damage. Furthermore, in some cases in which primary repair has failed, a second attempt for direct repair does not seem logical, especially in the presence of infected urine and feces in the pelvis. In conditions such as these, by performing supravescical diversion, we can bring the patient out of critical condition and at a later date when the patient's condition is more stable, undiversion with or without augmentation will bring the urinary system's anatomy and physiology close to normal status.

The portal of entry of the missile fragment or bullet was abdominal in 6 cases (30%) and from the buttocks or perineum in the remainder (70%). In five patients, the injury was limited to the bladder, while in the remaining 15 cases, the bladder injury was associated with other organ injuries. (Table I).

Since the primary repair was performed in front line hospitals, the patients were kept on cystostomy drainage under conservative management. 14 of 20 patients recovered without further surgical intervention after an average of 16 days of drainage after primary repair at the front line hospitals. In nine of these 14 patients, there was associated rectosigmoid injury. Colostomy together with bladder repair and cystostomy was performed which resulted in full recovery, even in three

PATIENTS, METHODS AND RESULTS

From 1984 to 1986, 20 war injured patients with bladder injury were admitted to the Shahid Modarress Hospital. The diagnosis of bladder injury was made at front line hospital during exploratory laparotomy in all cases, and primary repair was performed at that time. After admission to our center, routine examinations, IVP and retrograde cystography were performed in all patients. Other studies were performed as indicated.

The average age of the patients was 20.8 years old.

Table I. Associated injuries in 20 war injured patients.

INJURY	NO.	PERCENT
alimentary tract injuries	15	75%
pelvic bone fracture	4	20%
iliac vessel injury with pelvic hematoma	6	30%
urethral and penile injuries	4	20%
deep infected perineal wound	8	40%
sciatic injury	3	15%
scrotal and testicular injury	3	15%
ureteral injury	3	15%
hemopneumothorax	1	5%

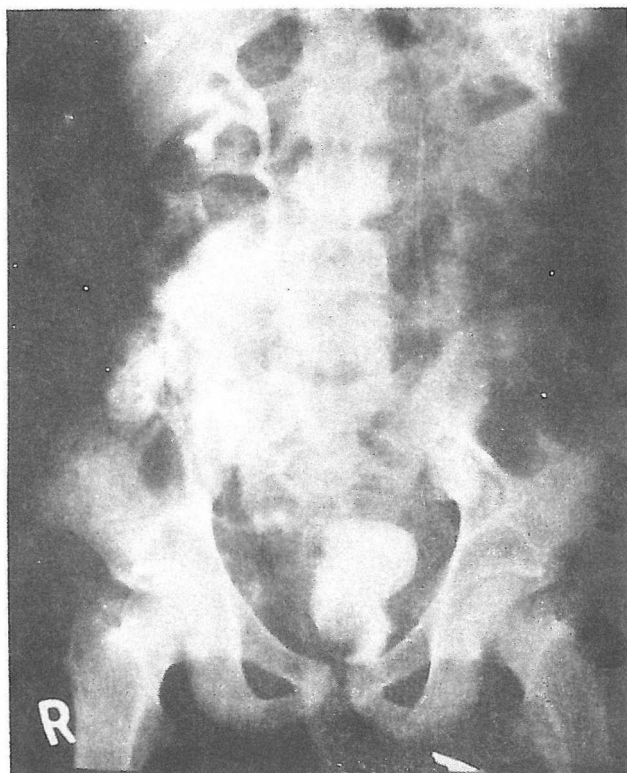


Fig 1: Intravenous urography of a war casualty with bladder injury. Compression and distortion of the bladder due to pelvic hematoma and urinoma is seen.

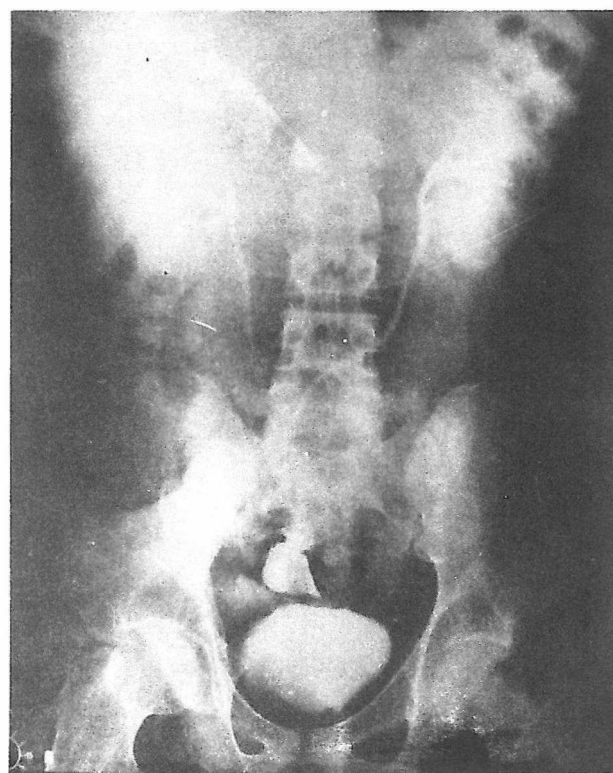


Fig 3: IVU of war injured patient shown in Fig 1 is seen following undiversion. Ileal loop is used as a patch to anastomose it to the bladder. Bladder shape is back to normal. Transuretero-ureterostomy together with normal upper tract is visualized.

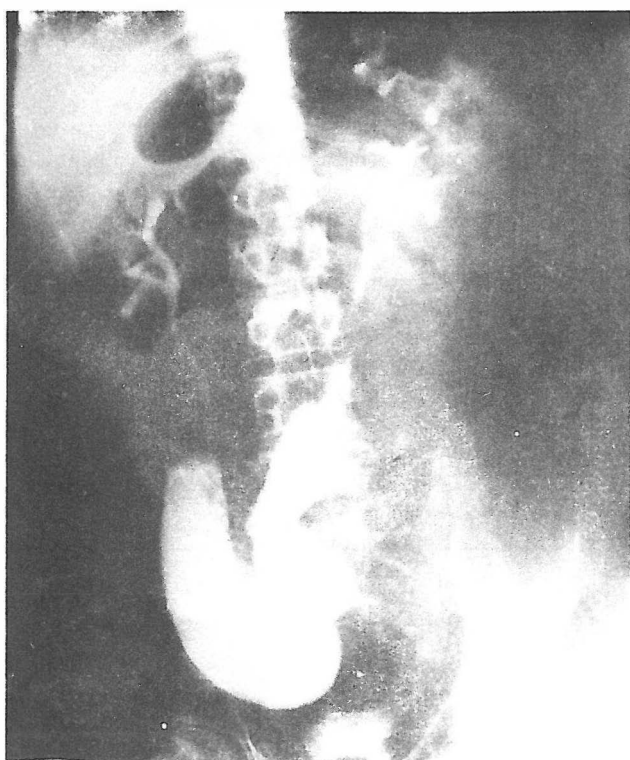

Fig 2: IVU of patient in Fig 1 following ileal conduit diversion is seen.

cases of vesicorectal fistula. In these patients, the general condition was good and there was no ureteral injury in many of them.

Three of the 20 patients were reoperated upon on emergency basis due to peritonitis in two patients and intestinal obstruction in one. Secondary bladder repair was performed in two cases and ureteral reimplantation in one. Since these reconstructive procedures were performed on an emergency basis in a contaminated pelvis, results were not satisfactory, ending with a nonfunctioning kidney in one case, ureteral stenosis in the second and vesicoileal fistula and bladder stone in the third case.

In the last group of the 20 patients with bladder injury which is the main subject of this report, there were three patients with extensive injury who developed septicemia. These patients had blast injuries with extensive bladder involvement and associated injuries of other organs.

The first case had bladder injury and associated rectal perforation, the second case had bladder injury with lower ureteral and colon injury, and case three had bladder injury with vesicorectal fistula. All three patients had received primary vesical repair and colostomy in front line hospitals. Since the patients developed septicemia and had extensive pelvic injuries, it

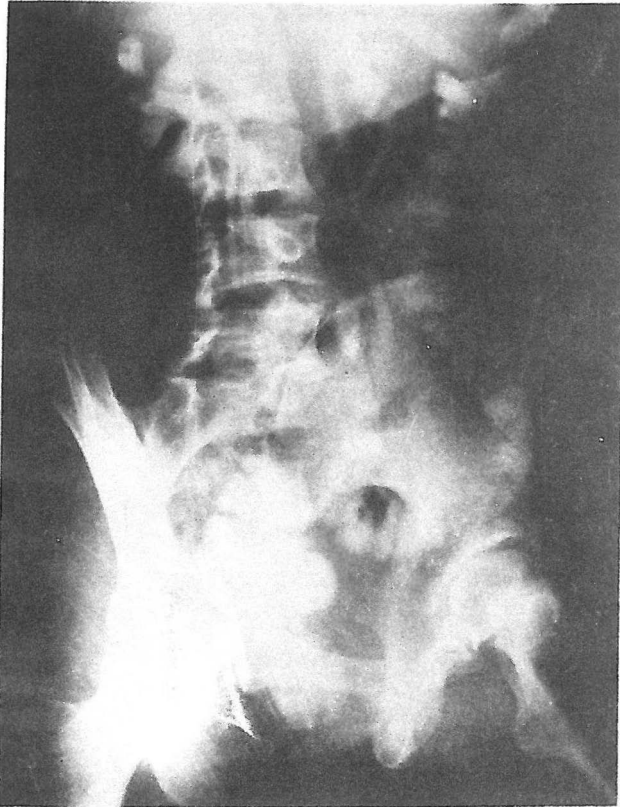


Fig 4: Pre . operative IVU in a patient with bladder injury. Contrast material is seen in colon due to bladder injury (Vesico-colonic fistula associated with bladder injury).

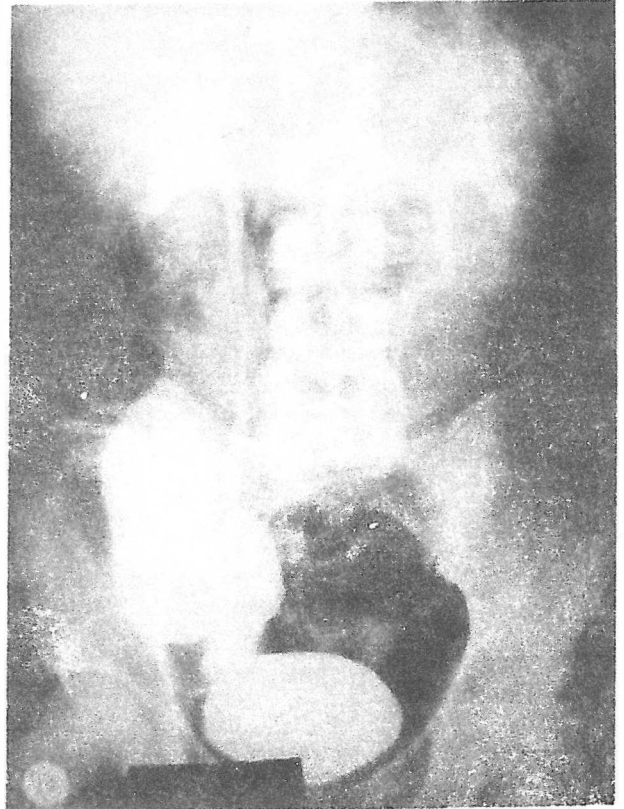


Fig 5: Post diversion IVU (Ileal conduit) in patient seen in Fig 4.

was decided to perform supravescical diversion by ileal conduit diversion. This resulted in recovery and regaining good general condition in all three cases.

In case one, eight months following supravescical diversion, lower tract study revealed the healing of the vesical injury. In this patient, undiversion was performed by anastomosing the ileal conduit to the bladder (Figs. 1-3). Post-diversion IVP reveals a normal collecting system.

In case two, one year following supravescical diversion, undiversion was undertaken by performing transureteroureterostomy and Boary flap anastomosis to the bladder with a satisfactory result (Figs. 4-6).

In case three, a thorough study revealed complete healing of the vesicorectal fistula following supravescical diversion. The patient underwent undiversion by separating the ureters from the ileal loop and anastomosing the distal ends of the ureters (Figs. 7-10).

DISCUSSION

Blast injuries of the bladder during war-injuries are usually associated with other organ injuries. Primary repair in many of these cases is subject to fail since the repair is performed in an infected pelvis.³ If general condition of the patient is good, colostomy is per-

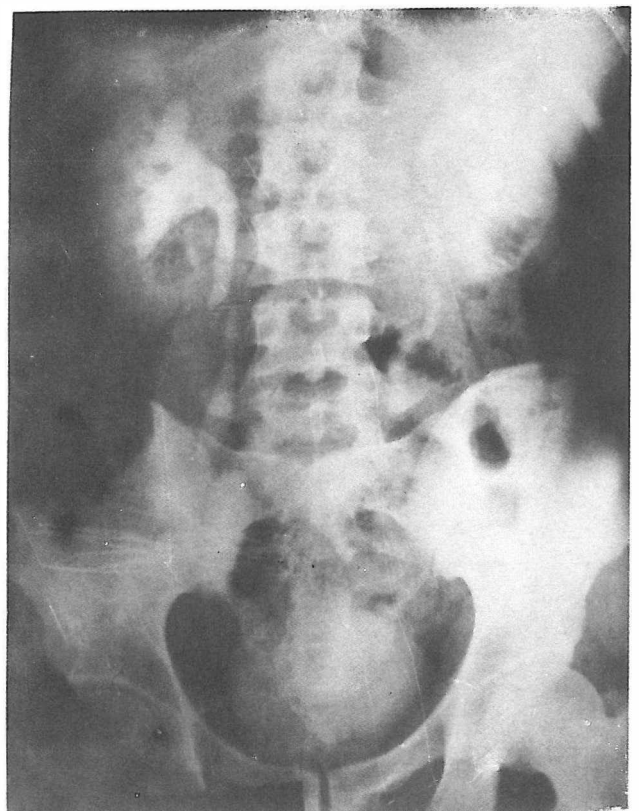


Fig 6: Urography post undiversion in patient in Fig1. Transureteroureterostomy and Boary flap of bladder made undiversion feasible.

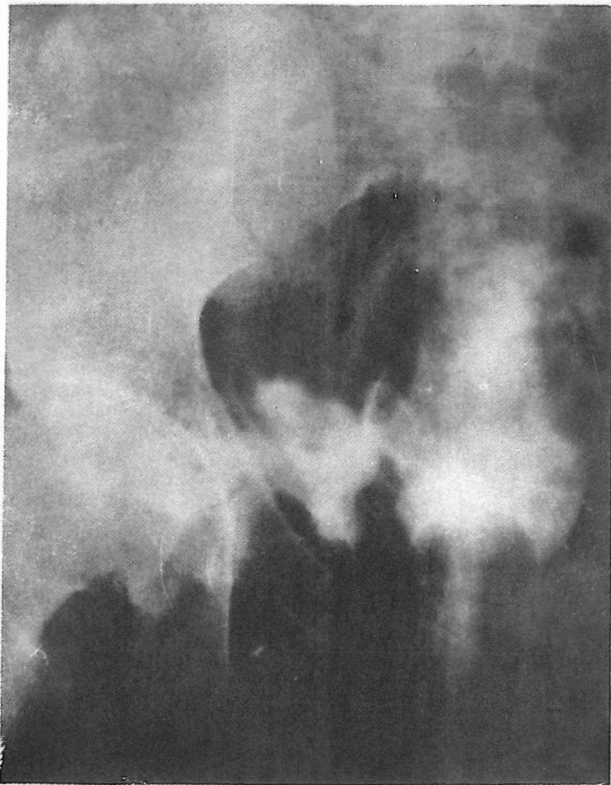


Fig 7: Cystogram in a war injured patient. Contrast material is seen outside the bladder.

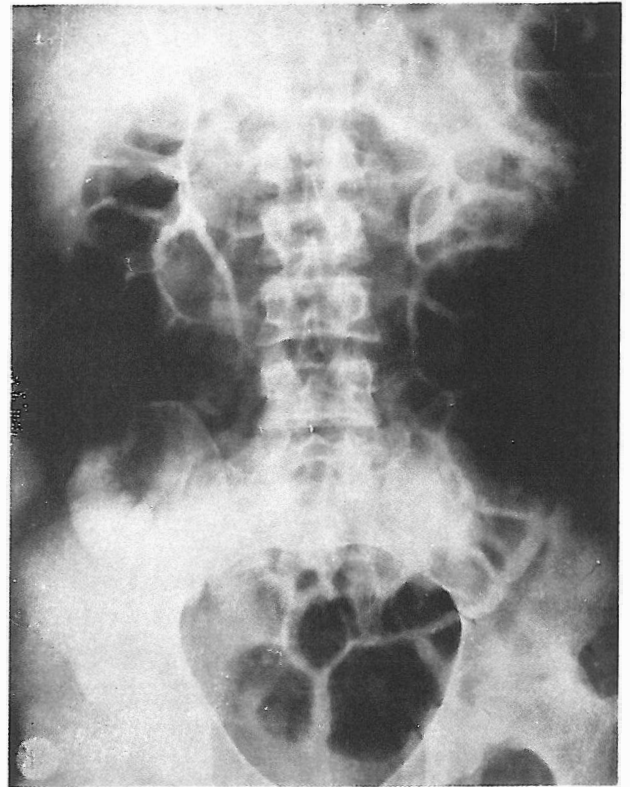


Fig 8: IVU of patient in Fig 7 following ileal loop diversion. Normal upper tract is seen. Patient's general condition improved

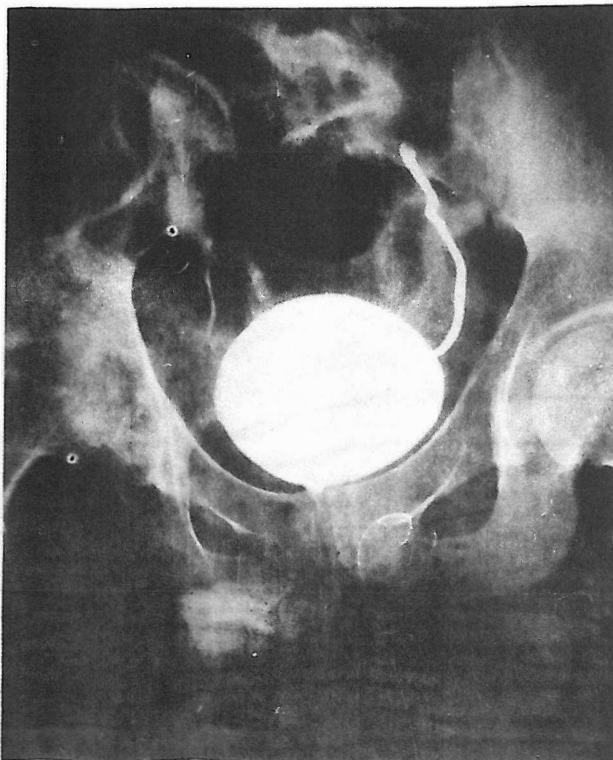


Fig 9: Cystogram of injured patient shown on Fig 7. No contrast material is seen outside the bladder any more. (mild left ureteral reflux is seen).

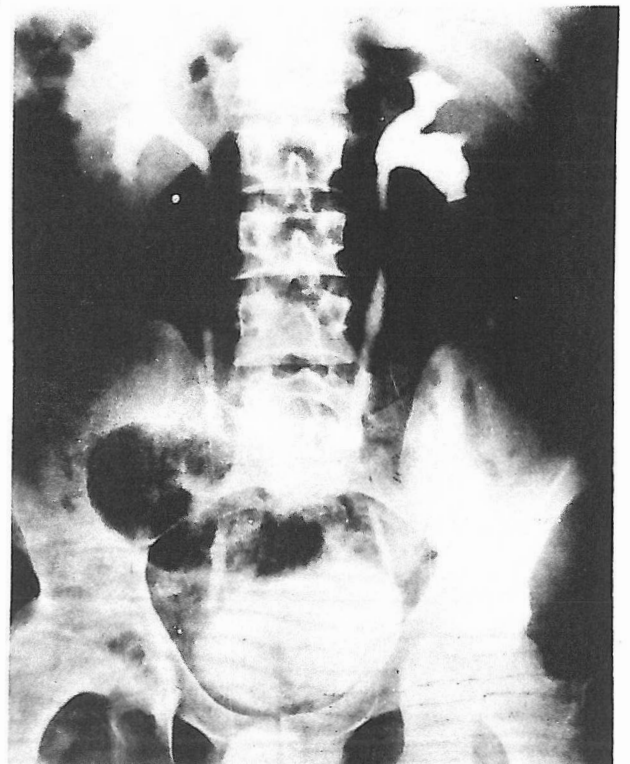


Fig 10: IVU of warinjured patient with bladder injury shown on Fig 7 after undiversion. Ureters were separated from ileal loop and reanastomosed to the distal portion of ipsilateral ureter bringing the patient back to his normal condition.

formed in ~~the~~ may heal with bladder catheter drainage alone. We have noted spontaneous closure of three cases of vesicorectal fistulae following colostomy and bladder drainage alone.⁵

In three cases in whom primary bladder repair was performed in front line hospitals and who were in critical condition, we had to perform emergency exploration due to surgical complications (intestinal obstruction or peritonitis). Bladder repair and ureteral reimplantation in these patients was associated with considerable morbidity.¹ This was due to the fact that the area in which the repair was performed was contaminated (with feces and urine) and potentially infected.

On the other hand, in three other cases in critical septic condition, after primary repair, supravescical diversion in these cases whose bladder lesions were associated with colon injury brought the patients out of critical condition. With later undiversion, these pa-

tients were returned to near normal condition. Therefore, we recommend the use of diversion and undiversion² in selected cases of bladder injury in which there exists associated injuries (colon, ureter) and sepsis, in order to save the patient and lessen the morbidity of reconstructive procedures.

REFERENCES

1. Peters PC, Sagalowsky AI: Genitourinary trauma. In: Walsh PC, Gittes RF, Perlmutter AD, Stamey TA, eds. *Campbell's Urology*. Philadelphia, W.B. Saunders Company, 1192-1246, 1986.
2. Goldwasser B., Webster GD: Augmentation and substitution enterocystoplasty *J Urol* 135: 215-224, 1986.
3. McAninch JW: Vesical trauma. In: Glenn JF, ed, *Urologic Surgery*. Philadelphia: JB Lippincott Company, 627-45, 1983.
4. Carroll PR, McAninch JW: Major bladder trauma: the accuracy of cystography. *J Urol* 130: 887-888, 1983.
5. Carroll PR, McAninch JW: Major bladder trauma: mechanisms of injury and a unified method of diagnosis and repair. *J Urol* 132: 254-257, 1984.

