

## VESTIBULAR BULB HYPERTROPHY

H. DABIRASHRAFI, M.H. KARIMINEJAD, Y. BEHJATNIA, AND  
N. MOGHDAMI TABRIZI

*From the Department of Obstetrics and Gynecology, Mirza Koucheh Khan (Zanan) Hospital, Tehran University of  
Medical Sciences, Tehran, Islamic Republic of Iran*

### ABSTRACT

In this case report, a 36 year old female at 40 weeks' gestation is presented in whom large bilateral vestibular bulb masses were found on pelvic examination. The size of the masses was such as to cause concern that they may pose an impediment to normal parturition. Our pathological findings, management and results are presented.

*MJIRI, Vol.2, No.1, 71-73, 1988*

### INTRODUCTION

Although cysts of the vagina and vulva are seen rather frequently, only on exceptional occasions does one encounter them in pregnant women and of a sufficient size to interfere with delivery.

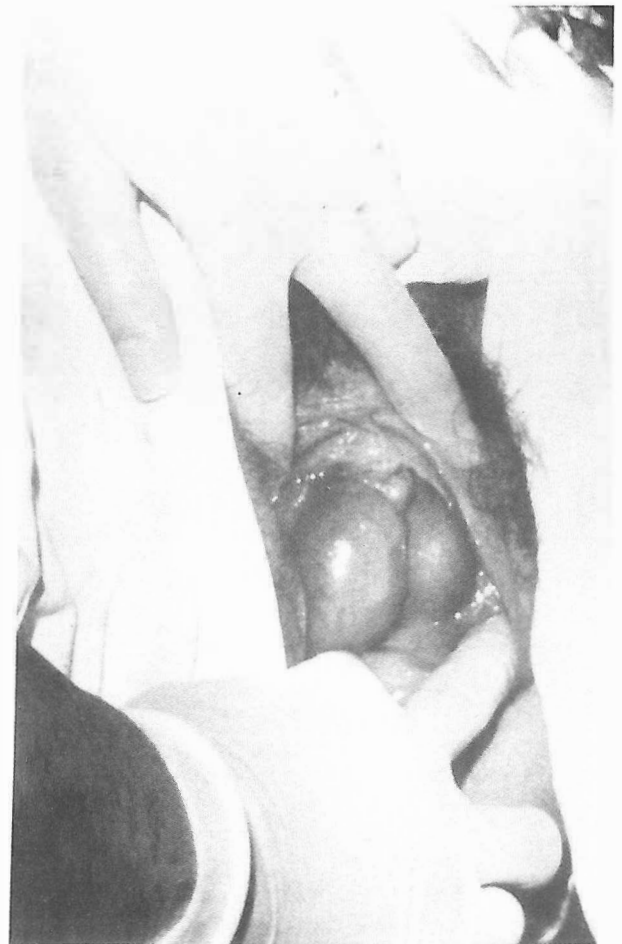
Spitzer<sup>1</sup> reported a very interesting and unusual case in which a cyst of Gartner's duct caused a face presentation. A more common condition is an abscess of the Bartholin gland.<sup>1</sup> Venereal warts (condylomata) may reach a large size in pregnancy, but seldom to the extent of causing an obstruction.<sup>2</sup> We report a case of vestibular bulb tumors that raised concern in that they may obstruct delivery.

### CASE REPORT

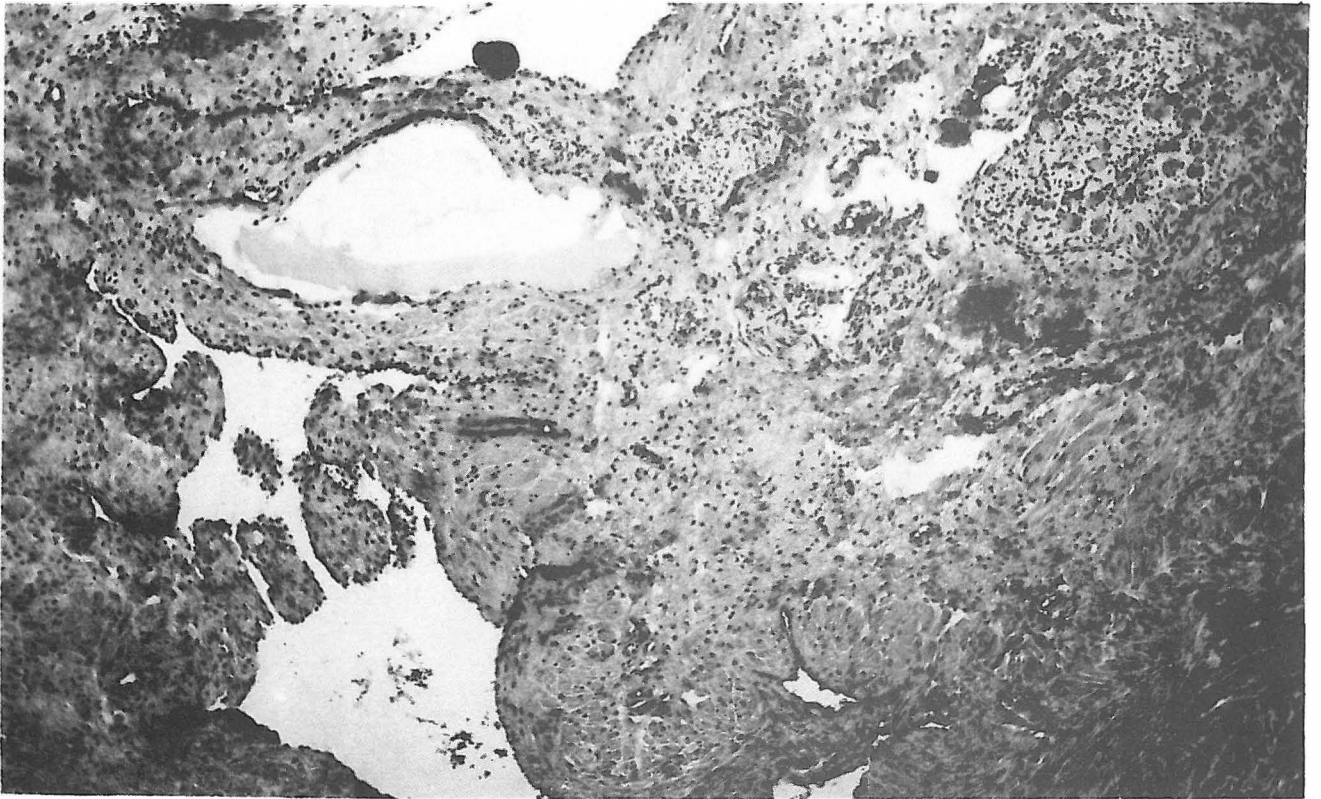
A 36 year old white woman, G = 7, P = 6, Ab = 0 was admitted to the hospital in active true labor at 40 weeks of gestation. Her past history was unremarkable. Vaginal examination and a glance at the vestibular area revealed two large tumoral cystic masses on either side of the introitus.

These two tumors became enlarged during bearing down, closing the entrance of the vaginal canal, and they decreased in size after cessation of uterine contraction. The tumors were located bilaterally near the labia minora in the vestibular area at the beginning of the lateral walls of the vagina. The dimensions of the tumors were 7x4x3 cm on the right and 5x4x3 cm on the left (Fig. 1).

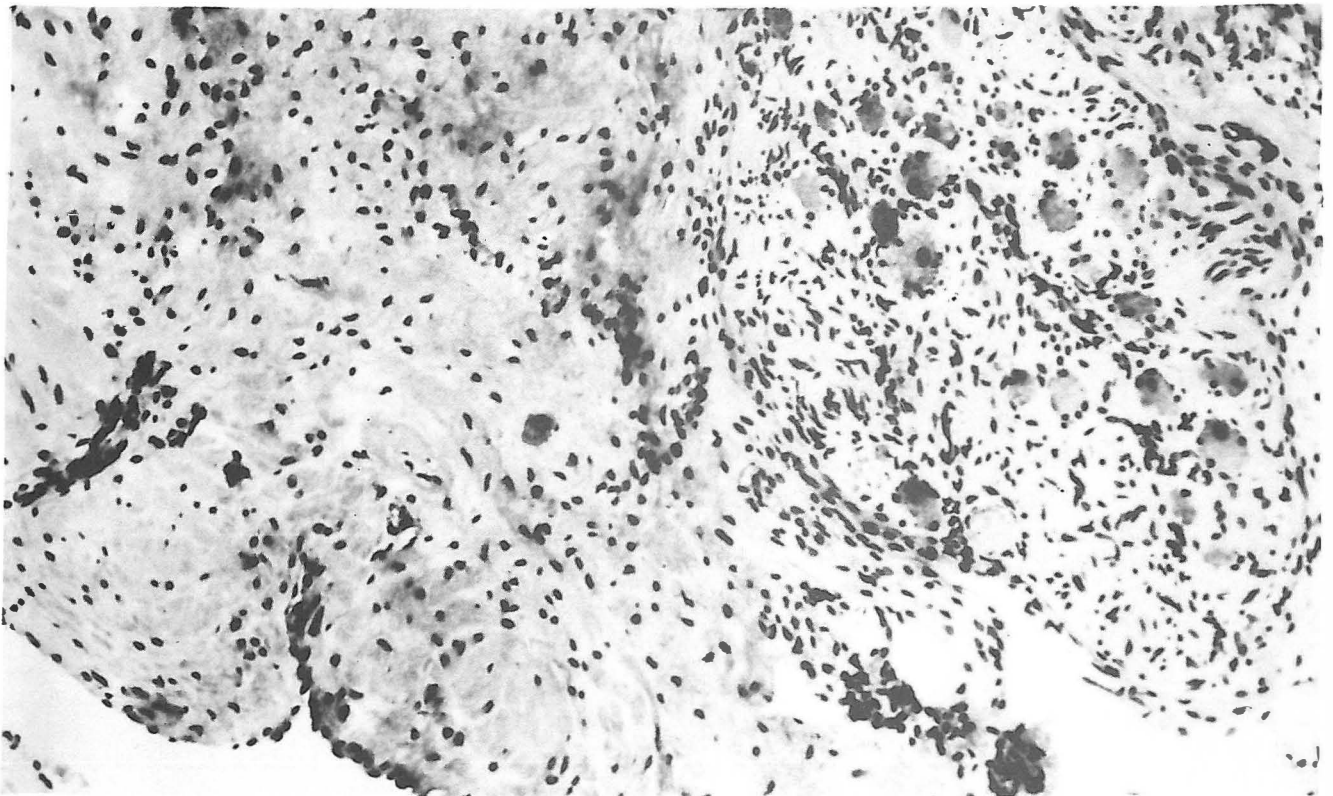
With due caution, delivery was performed without complication, although a major concern was that the



**Figure 1.** Two ovoid masses bulging bilaterally into the vestibular area of the vagina.



**Figure 2.** Thick-walled vessels are prominent. Note the ganglion cells in the upper right corner (H & E, original magnification X45).



**Figure 3.** Muscle bundles of vascular wall and adjacent clustered ganglion cells are evident. (H & E, original magnification X100).

tumors might obstruct the delivery or be crushed by the passage of the fetal head. After delivery 10 IU of oxytocin was injected intramuscularly.

7 days after delivery, when the tumors became smaller (5x3x2 cm, on the right and 4x2x2 cm, on the left), they were removed under general anaesthesia. Two days postoperatively, the patient was discharged from the hospital in good health. Since that time, the patient has been examined on several occasions and has no complaints.

### Pathology

The histological sections of right and left-side specimens reveal a very thick-walled vascular channel lined by a layer of endothelial cells. The vascular wall consists of smooth muscle bundles, arranged longitudinally along the vascular axis. Elastic fibers surround the muscle bundles and form thick bands in some areas. Nerve fibers and ganglion cells are scattered throughout. The histological features are similar to corpus spongiosum of male external genitalia (Figs. 2-3).

### DISCUSSION

The vestibule may be defined as the portion of the vulva which begins at the hymenal ring and extends outward to blend with the more keratinized skin of the minor labia, upward to the frenulum of the clitoris, and downward to include the posterior fourchette. On either side of the vestibule there are two structures that are called "vestibular bulbs". These organs consist of

two ovoid masses of erectile tissue, much thicker posteriorly. The masses are situated in the bulb of the penis in the male and comprise of a rich plexus of veins.

The microscopic characteristics and bilaterality of the tumors in our patient indicate that in reality, these tumors were vestibular bulb aberrations that increased in size and changed location (Fig. 1). At the time of delivery, our concern was that the tumors seemed to be rich in blood vessels and might be crushed, producing a hematoma. But fortunately, delivery was completed successfully without complications. Seven days after delivery the masses became smaller but still were of abnormal size. Excision of the tumors revealed the microscopic appearance of erectile tissue compatible with vestibular bulb structures. To the authors' knowledge, this is the first report of vestibular bulb hypertrophy during pregnancy that raised concern as to their obstruction of delivery.

### REFERENCES

1. Myerscough PR: Munro Kerr's Operative Obstetrics. London, Balliere Tindall, 183-4, 1982.
2. Pritchard JA, MacDonald PC, Gant NF: Dystocia from other abnormalities of the reproductive tract. In: Pritchard JA, MacDonald PC, Gant NF, eds. Williams' Obstetrics. Norwalk, Appleton-Century Crofts, 687-695, 1985.
3. Woodruff JD, Friedrich EG Jr: The vestibule. Clin Obstet Gynecol 28 (1): 134-41, 1985.
4. Robboy SJ, Foss JS, Prat J, Keh PC, Welch WR: Urogenital sinus origin of mucinous and ciliated cysts of the vulva. Obstet Gynecol 51 (3): 347-51, 1978.

