

MICROSURGICAL TREATMENT OF LONG BONE DEFECTS USING FREE VASCULARIZED FIBULAR TRANSFER

MOHAMMAD ASHAYERI, FERAYDON ESLAMPOUR

From the Department of Reconstructive Surgery, Shahid-Motahhari Hospital, Iranian University of Medical Sciences, Tehran, Islamic Republic of Iran.

ABSTRACT

Management of long bone defects occurring in accidents or war injuries is a difficult problem. From 1978 to 1986, 11 patients were treated for long bone defects of the humerus (10 cases) and radius (one case), using free vascularized fibular transfer by microsurgical technique. The patients were followed for 4 months and in all of them, selective angiography and scanning revealed excellent graft union. We consider free vascularized fibular bone transfer a suitable alternative in management of long bone defects especially those complicated by other reconstructive methods.

INTRODUCTION

The successful management of long bone defects continues to be a difficult problem. Since the Iraq-imposed war on the Islamic Republic of Iran there have been many cases of long bone defects due to blast injuries or other causes. Car accidents are also a leading factor. In selected cases a free vascularized fibular graft offers significant advantages over conventional methods of treatment,¹ since a long segment of bone, along with its accompanying nutrient vessels can be detached from its donor site and transferred to a distant recipient site with preservation of the nutrient blood supply by microvascular anastomosis to recipient vessels.¹ With the nutrient blood supply preserved, osteocytes and osteoblasts in the graft can survive and healing of the graft to the recipient bone will be facilitated.²

PATIENTS AND METHODS

From 1978 to 1986, 11 male patients in age ranging from 18 to 33 were treated for long bone defects of the humerus (10 cases), and radius (one case), by free vascularized fibular transfer. In one of these cases, the humerus bone was involved with tumor. The tumor was excised *en bloc*, and the size of the defect was then determined. The size of the fibular bone graft in these cases was from 10 to 22 cm.

Surgical Procedure

Under general anesthesia, the patient is positioned prone, because this position affords the best exposure for the fibular dissection.² A pneumatic tourniquet is used to achieve a bloodless field. The operation at the recipient site is begun by one surgical team where the vessels are identified and isolated and the size of the defect is determined. If non-union exists, the bone ends are resected and prepared proximally and distally to receive the fibular graft. At the same time another surgical team begins dissection of the fibular bone and its nutrient vessels. Henry's approach is used to expose the fibula, starting proximal to the insertion of the biceps femoris, thereby permitting identification of the common peroneal nerve. Once the common peroneal nerve is isolated and protected, the surgeon proceeds to identify the popliteal artery and vein and posterior tibial nerve in the popliteal fossa. The origins of the anterior tibial artery, the posterior tibial artery and the peroneal artery are isolated carefully, as are their accompanying venae comitantes. The dissection is continued distally and posteriorly, with preservation of a 1 cm thick muscle cuff circumferentially around the fibula, thereby preserving the nutrient artery and periosteal vessels. This muscle cuff consists of the soleus proximally and the peroneus longus anterolaterally. If a longer segment of fibula is needed, a similar sleeve of flexor hallucis muscle is preserved

medially, with the peroneus brevis being preserved laterally. Following completion of the proximal and distal dissection, the anterolateral aspect of the fibula is isolated, taking care to protect the anterior tibial artery and the deep and superficial peroneal nerve. On completion of the dissection, the fibula is isolated on its vascular pedicle which consists of the peroneal artery and its venae comitantes. A segment of fibula 6 cm longer than the measured bone defect is then transected with a Gigli saw, because fixation of the fibular graft is to be introduced into the medullary canal of the proximal and distal bone segments.

A segment of distal fibula proximal to the anterior and posterior syndesmoses must be left intact to prevent ankle instability and possible valgus deformity. After the fibula has been sectioned, the interosseous membrane is cut in a distal-to-proximal direction, with severance of the peroneal vessels being the final step. Using this procedure, grafts as long as 24 cm have survived completely. The transferred bone must be rigidly in the recipient site before microvascular anastomoses are begun.

We have used intramedullary fixation, because of the inherent destruction of the medullary blood supply to the bone graft. End-to-end anastomosis was performed between the appropriate recipient vein and the vein of the pedicle of the transferred fibula using eight interrupted sutures (10-0 nylon) and magnification ($\times 20$). A second anastomosis is performed between the appropriate recipient artery and the peroneal artery. Before the vascular clamp is removed from the peroneal artery, 5000 I.U. heparin is infused into the patient's circulation.

Success of the anastomoses is evidenced by bright, red bleeding from the preserved muscle sleeve and good venous return.

On completion of the anastomoses a corrugated drain is inserted and the skin closed. Anticoagulant therapy with aspirin, dipyridamole and dextran is initiated and continued for 5 days after operation. The recipient extremity is immobilized using an appropriate splint. The operation usually lasts from four to six hours.

RESULTS

11 patients, age ranging from 18 to 33, were treated for long bone defects of humerus (10 cases) and radius (one case) by free vascularized fibular transfer. All of the patients were followed up for four months after surgery. Bone scanning revealed satisfactory union of the proximal and distal site of the transferred fibula to the recipient bone (Fig 5). Selective angiography was performed in all of the cases, which showed well vascularized transferred fibular bone graft (Fig 6). In one of the cases, the humerus bone was involved with a benign tumor. The tumor was removed *en bloc* and a

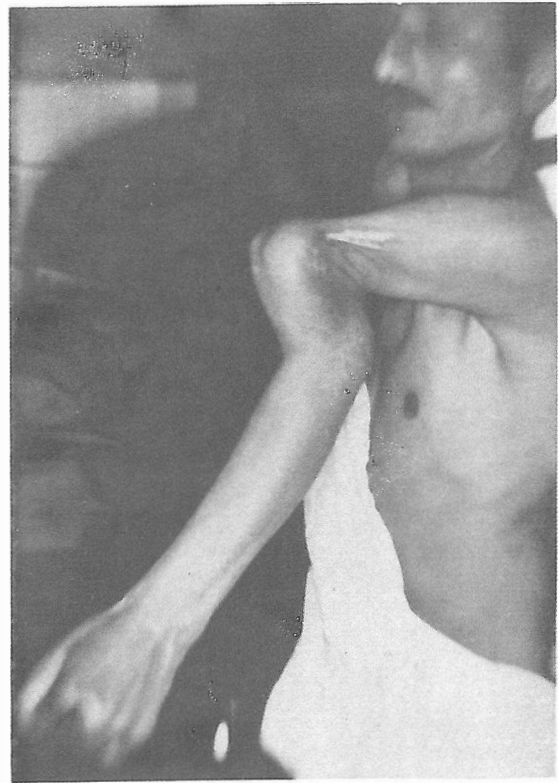


Fig 1: A 30 year old male with a 13cm bony defect in the humerus bone. This patient had been operated by different methods twice, without a successful result.

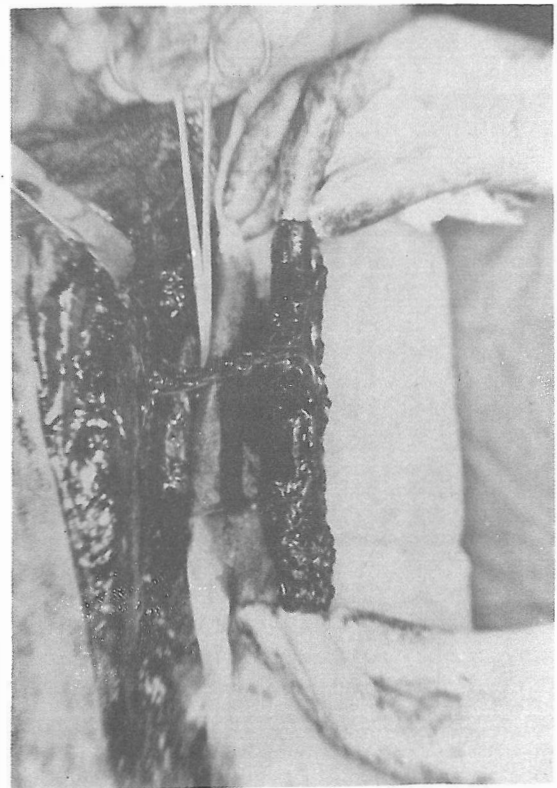


Fig 2: Fibula being removed with its accompanying peroneal vessels.

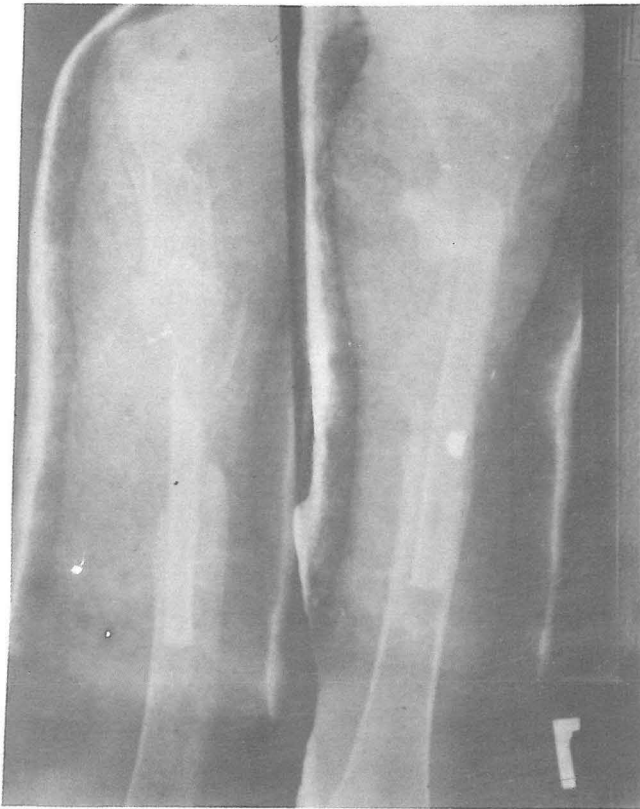

Fig 3: X-ray of the patient's arm following fibular transfer for reconstructing the 13cm bone defect.

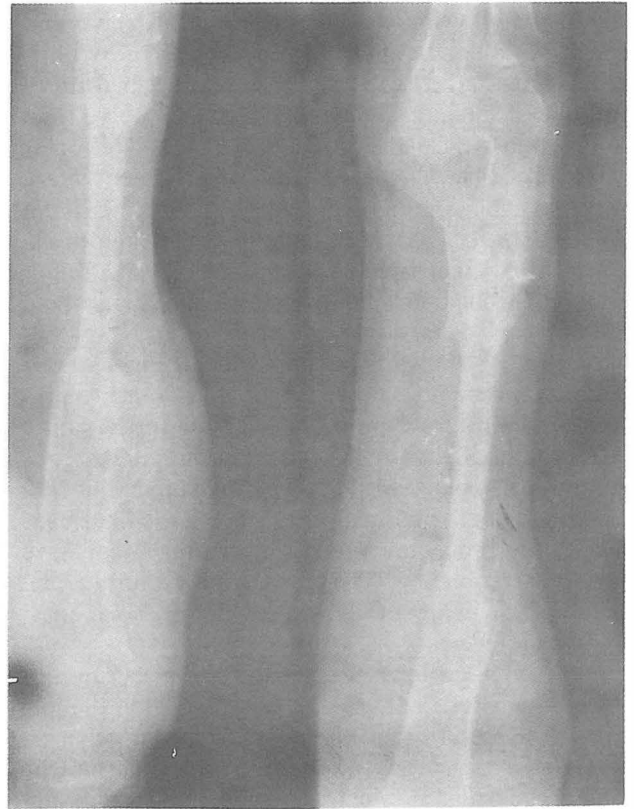


Fig 4: X-ray of the arm of the same patient (Fig 3) four months postoperatively.

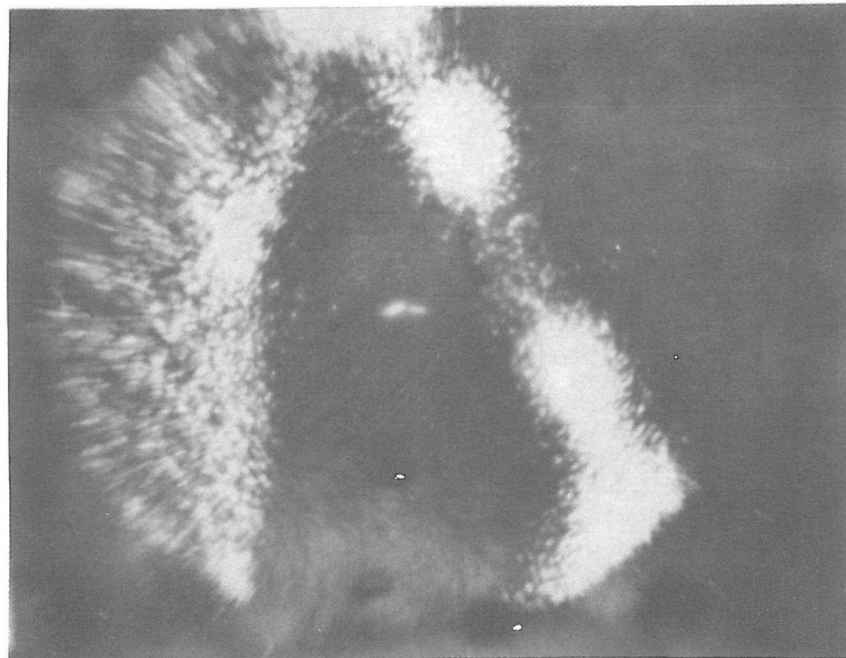


Fig 5: Bone scan from the fibular bone transferred to the humerus bone defect by microvascular technique. This picture reveals a good healing process in the junction between transferred fibula and the humerus bone.

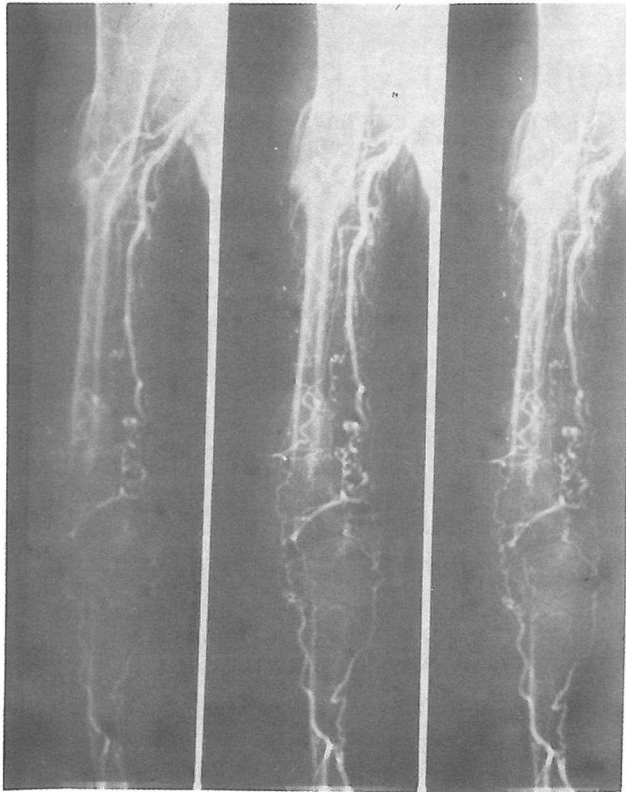


Fig 6: Angiography of the arm vessels demonstrating patency of anastomosis between peroneal vessels and vessels of the arm.

free vascularized fibular graft replaced the bony defect. In all of the 11 cases operated by microscopic vascular anastomosis, successful results brought back near normal function to the involved extremity (Fig 1-6).

DISCUSSION

Parallel to the development, of microvascular surgery, reconstruction of long bone defects using free vascularized fibular transfer was developed.^{1,3,4}

Since surviving cells in autogenous grafts are entirely dependent on nourishment from the surrounding vascular bed immediately after transfer, the superiority of autogenous cancellous bone grafts is direct relation to their adjacent structures which facilitates diffusion of nutrient substances necessary for osteocyte and osteoblast survival is readily appreciated.³ Dense cortical bone acts as a barrier to diffusion, thereby inhibiting cell survival.³ Unimpaired microcirculation is indispensable for the continued life and function of all bone cells. Obviously, this can only be achieved by preservation or immediate reconstruction of the primary blood supply to the bone graft.³ For these reasons, vascularized fibular transfer is satisfactory for reconstruction of long bone defects secondary to trauma or following tumor resection.

REFERENCES

1. Taylor GI: Microvascular free bone transfer; clinical technique. *Orth Clin N Am* 8 (2): 425-447, 1977.
2. Duthie RB, Bently G: Autografts. In: *Mercer's Orthopedic Surgery*, London, Edwin Arnold. 79-80. 1983.
3. Weiland A J, Daniel RK: Vascularized Bone Grafts. In: *Operative Hand Surgery*, Green DP (ed.) 877-94. 1982.
4. O'Brien B: *Microvascular Reconstructive Surgery*. Edinburgh, Churchill Livingstone, 267-284, 1977.
5. Harrison, DH: The osteocutaneous free fibular graft. *J Bone Joint surg*, 68 (5): 804-807, 1986.