

CUTANEOUS FASCIOLIASIS

Y. DOWLATI, A. DOWLATI AND B. V. SEYYEDI

From the Taleghani Medical School, Shahid Beheshti university of Medical Sciences, and the Tehran University of Medical Sciences, Tehran Islamic Republic of Iran

ABSTRACT

A patient who had a migratory cutaneous nodule and tumor removed for the second time was diagnosed as having the liver fluke, *Fasciola hepatica*. In this article, we present a case report of this peculiar manifestation of fascioliasis, as well as a general overview of the disease.

INTRODUCTION

Fascioliasis is a common liver disease caused by *Fasciola hepatica* among sheep and cattle in many parts of the world. It can infect man as an accidental host. Human infection has been reported in Venezuela, Uruguay, Argentina, Chile, Colombia, Mexico, Puerto Rico, Cuba, Costa Rica, Syria, Turkey, Japan, China, the Soviet Union, Iran, Poland, Madeira, England, France, Italy, Corsica, Spain, Hungary, Romania, Salonika, the Dardanells, Egypt, Algeria, Somalia and the United States (including Hawaii). The life cycle of the parasite is demonstrated in figure 1.

The adult fluke lives in the liver bile ducts, and immature eggs are passed into the feces after an incubation of approximately 15 days. The miracidia

escape from the operculated eggs and invade snails, mainly species of *Lymnea*, including *Lymnea truncatula*. In the snail the miracidium develops into a sporocyst and then into rediae and cercariae. The cercariae leave the snail and encyst on aquatic plants in the form of metacercariae which are ingested by herbivorous animals or accidentally by man via consuming raw watercress, etc. The metacercariae excyst in the duodenum, migrate through the intestinal wall into the peritoneal cavity, penetrate Glisson's capsule of the liver and traverse the liver parenchyma to reach the biliary passages, thus producing many hemorrhagic and necrotic tunnels in the liver. The incubation period between infection and the development of the adult stage is approximately three to four months. Sheep and cattle are the natural hosts of this parasite.

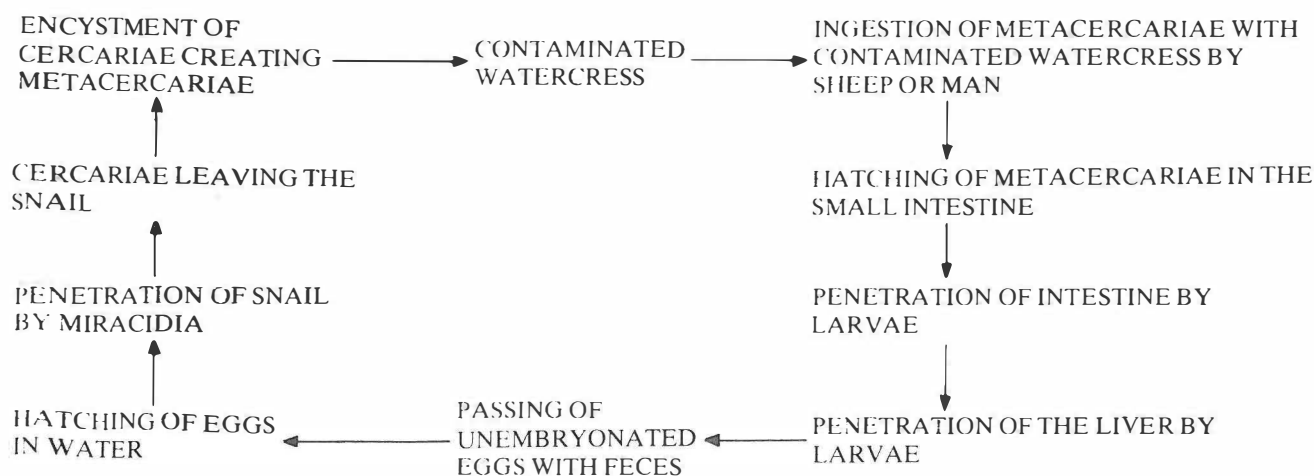


Figure 1. The life cycle of *Fasciola hepatica*.

With regard to symptomatology in man, after a short incubation period, mild and transient dyspepsia is often the first symptom. Subsequently, mild to moderate or even high fever, cramp-like epigastric pain aggravated with coughing, diarrhea, jaundice, urticaria, pruritus and arthralgia may occur. The hallmark of laboratory findings is leukocytosis accompanied with marked eosinophilia of up to 60%. A history of living in or having visited an endemic area and eating raw watercress or drinking contaminated water is helpful. Finding large operculated eggs in the feces (which is not always possible) confirms the diagnosis. Skin tests and indirect immunofluorescence of the patient's serum are available.

Ectopic locations due to unusual passage of larva have occasionally been recorded in infestation with *F. hepatica*. These locations could be blood vessels, lungs, subcutaneous tissue, ventricles of the brain and the orbit. Infestation of subcutaneous tissue is usually associated with hepatic fascioliasis. Reddish-brown oval or round nodules appear on the abdominal wall which migrate and are pruritic and painful. Biopsy shows eosinophilic infiltration and tunnels with necrotic walls in which the parasite may or may not be present.

CASE REPORT

A 36 year old white male oil industry worker referred to the National Iranian Oil Company Hospital with acute abdominal pain approximately 18 months before his visit to us. Since the pain was mostly in the right upper quadrant and localized to one part of the liver, gallbladder disease or hydatid cyst was suspected. Gallbladder series, liver scan and barium meals did not reveal any abnormality. The white cell count ranged from 10,200 to 19,200 with eosinophils ranging between 37% and 59% on several occasions in the differential. The sedimentation rate was 19 and 70 mm for the first and second hours respectively. No anemia or red cell abnormality was seen, and the chest roentgenogram was normal. Lymphadenopathy was not present. The remainder of the physical examination showed no other abnormality.

Migrating nodules appeared over the left side of the chest ten months later. The nodules were painful and accompanied with fever. Each nodular episode lasted about 7-14 days before remission. On two occasions, spontaneous rupture of the nodule occurred, which produced a dark and bloody discharge. One nodule with an indurated base and erythematous top was excised for biopsy study six weeks after the appearance of nodules. The histopathological examination demon-

strated subcutaneous infiltration of lymphocytes, plasma cells and eosinophils. It was interpreted as angiolymphoid hyperplasia with eosinophilia, placing eosinophilic abscess and granuloma pyogenicum in the differential diagnosis. Another nodule which appeared on the left side of the chest took the shape of a crescent. The consultant hematologist suspected cutaneous larva migrans.

The nodules continued to reappear and resolve despite anti-larva migrans treatment (Figs. 2 and 3). Finally, we completely excised the nodules and in histopathological examination, a transverse section of a metazoan parasite was observed.

The final diagnosis of *F. hepatica* was made in the Department of Parasitology, School of Public Health, Tehran University of Medical Sciences (Figs. 4 and 5). Stool examination failed to reveal fasciola eggs; instead, the stool examination of this patient demonstrated *Trichuris trichiura* ova and *Giardia lamblia*

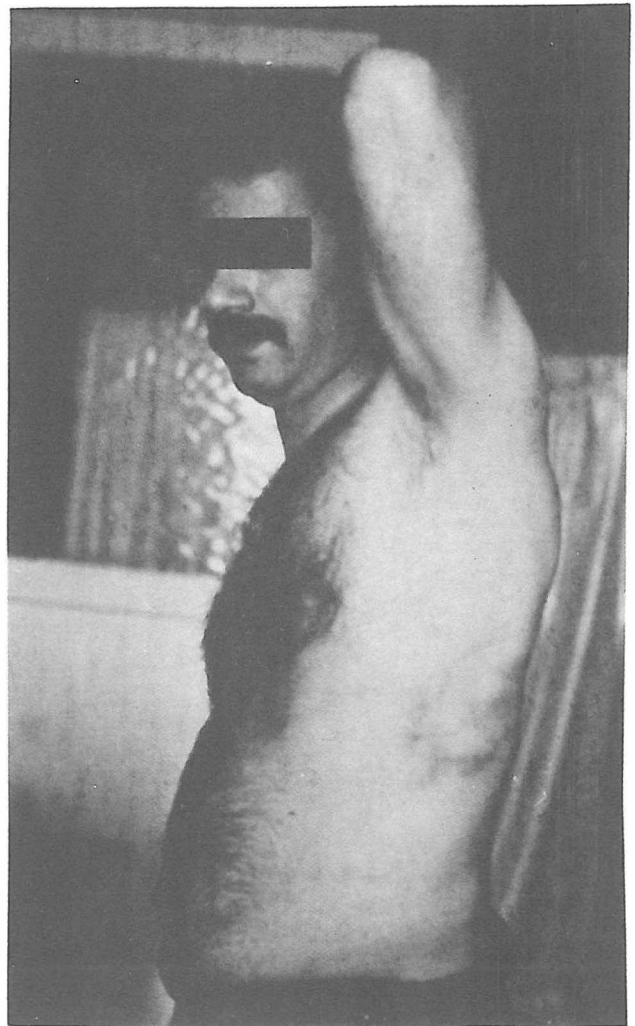


Figure 2. Migratory cutaneous nodules on the left side of the patient

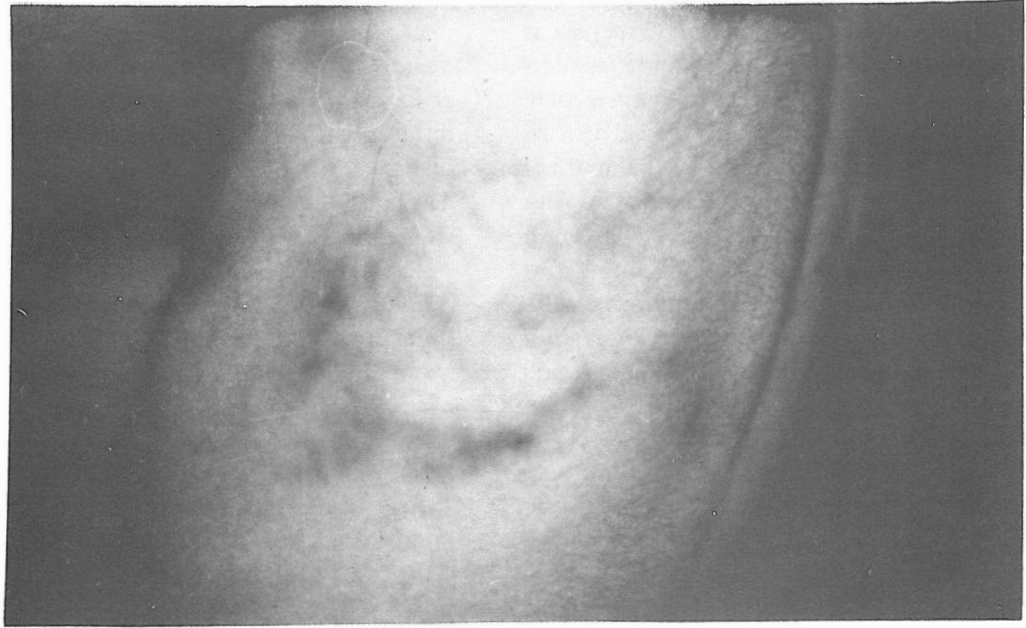


Figure 3. Close-up view of cutaneous nodules.

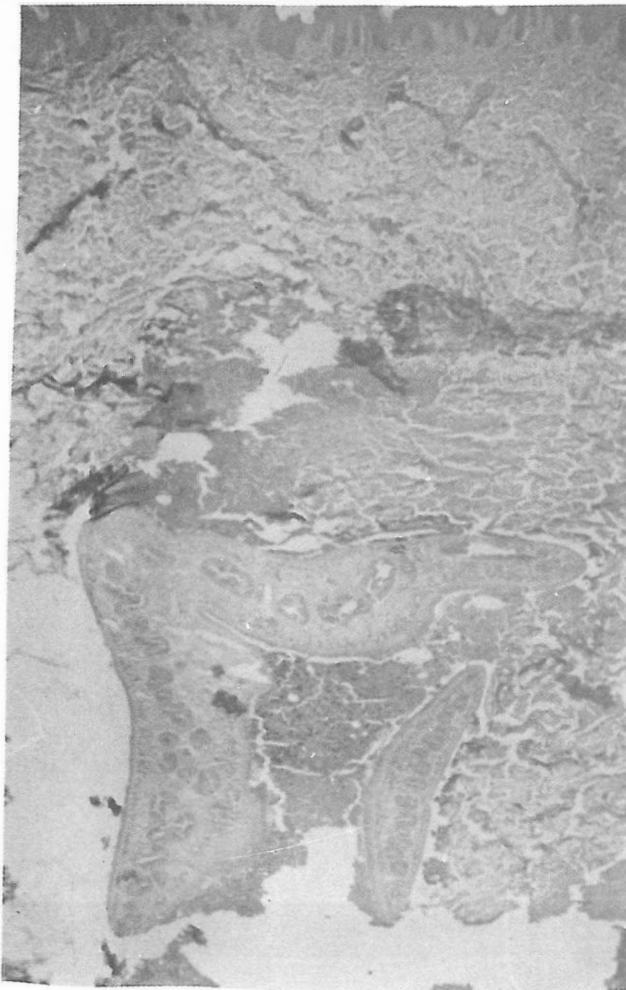


Figure 4. Histologic view showing cross section of parasite.

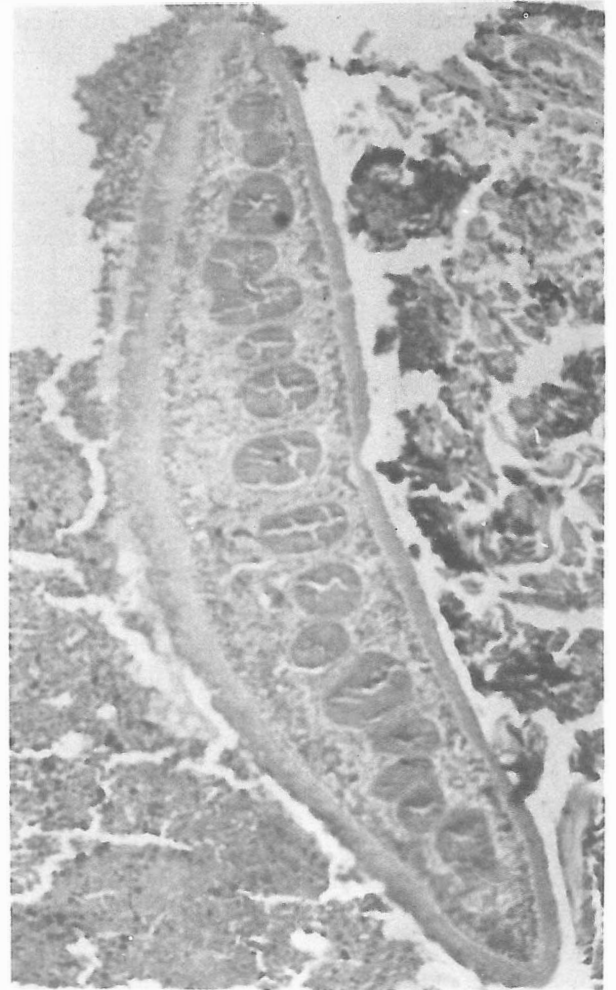


Figure 5. Higher magnification of cross section of parasite.

cysts, both of which are very prevalent in this country.

Since the removal of the parasite, no new lesion has appeared. Our last control to this date showed normal eosinophil count, chest roentgenogram, stool examination and liver function tests. Indirect immunofluorescence for fasciola was negative.

DISCUSSION

Cutaneous fascioliasis, as an ectopic infestation of *F. hepatica* has not been mentioned in the dermatological literature. Our comments in this respect are as follows:

1) Any migratory nodule or tumor on the abdominal or chest wall must be removed large enough to include the body of the parasite. The failure of previous surgery was probably due to incomplete removal of the tumor and leaving the parasite behind.

2) When a moving nodule with eosinophilic abscess and high peripheral blood eosinophilia are observed, the complete removal of the nodule and performing serial section for histopathological examination is necessary.

ACKNOWLEDGEMENTS

We would like to thank Dr. J. Massoud, Dept. of Parasitology, School of Public Health, Tehran University of Medical Sciences for histopathological diagnosis of the parasite.

REFERENCES

1. Chester P Jung RC, Cupp EW: Clinical Parasitology, 14th edition, Philadelphia, Lea & Febiger, 451-455, 1985.

