

URACHAL DIVERTICULUM WITH ALTERNATING SINUS

NASSER SIMFOROOSH

From the Department of Urology, Shahid Labbafi-Nejad Medical Center, Shahid Beheshti University of Medical Sciences, Tehran, Islamic Republic of Iran

ABSTRACT

Urachal anomalies are exceptionally rare. They can present in different ways in childhood as well as in adults. We present an interesting case of vesico-urachal diverticulum with alternating sinus. The interesting finding in this patient was the inversion and disappearance of the umbilicus at the termination of voiding.

CASE REPORT

A 16 year old male was referred to us due to occasional egress of urine from his umbilicus.

He would also complain of an inward pulling sensation and disappearance of his umbilicus at the end of urination. No other urinary symptom was present. The patient stated that he had been passing urine often through his umbilicus during his infancy and childhood. Routine physical examination revealed no significant findings. We observed the patient passing urine *per urethra* and noticed the umbilicus disappearing and assuming a pin-hole appearance. He seemed to have a normal urinary stream. The intravenous urogram was normal. A voiding cystourethrogram was done. After filling the bladder to its highest capacity with contrast material we were able to demonstrate a diverticular out-pouching at the dome of the bladder extending toward the umbilicus (Fig. 1). No distal obstruction was seen (Fig. 2). We were unable to reveal the connection between this urachal diverticulum and the outside through the umbilicus, which clinically has existed since the patient's birth. Cystoscopy revealed a normal urethra and bladder neck. The bladder was not trabeculated. A urachal diverticular opening was noticeable at the anterior portion of the bladder dome in the midline. The patient underwent surgery. The urachal diverticulum was removed completely from the dome of the bladder up to the umbilicus via a lower abdominal midline incision. The bladder wall at the urachal diverticular site was repaired in two layers. The post-operative course was uneventful. The umbilical inversion sign noticed during the terminal phase of voiding preoperatively disappeared after surgery.

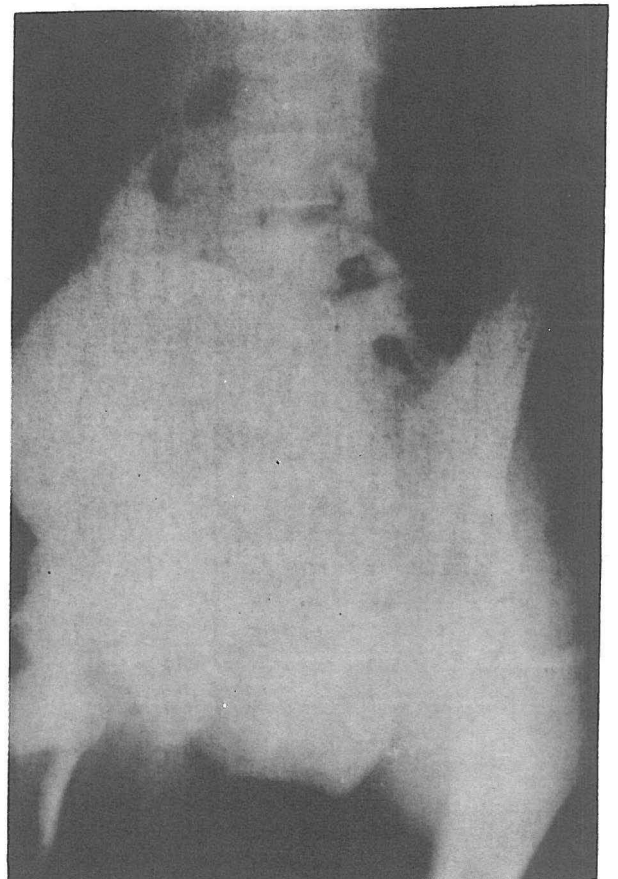

Fig. 1. A vesicourachal diverticulum demonstrated in a cystogram of a young male.

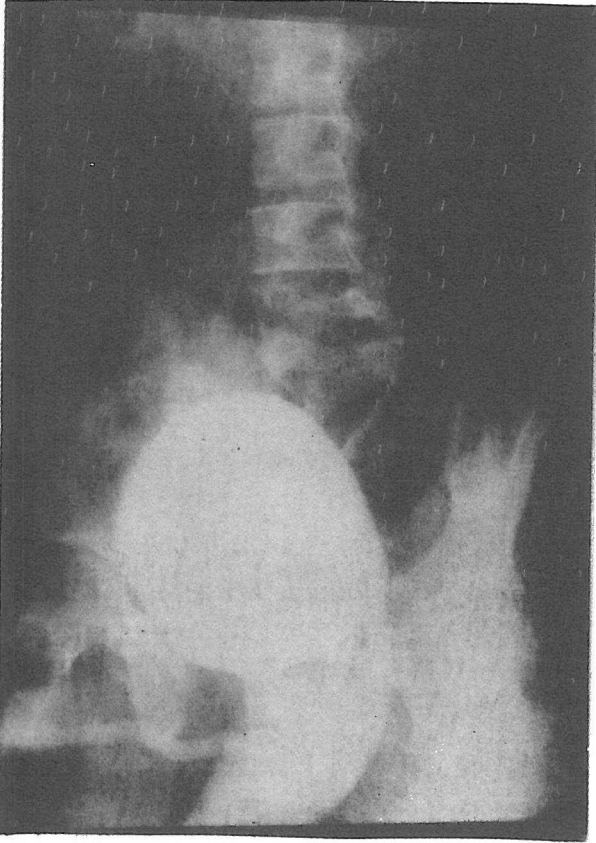


Fig. 2. Voiding cystourethrogram in a patient with a urachal diverticulum and alternating sinus. No obstruction is seen in the bladder neck or urethra, and the bladder does not seem trabeculated.

DISCUSSION

Urachal anomalies are exceptionally rare occurrences that may manifest themselves in later life as

well as in childhood.¹ Blichert-Toft and Nielson² were only able to collect 315 cases of patent urachus in the literature (1971) and only three cases were seen in more than one million admissions at the Charity Hospital in New Orleans (Nix, et al).³ The urachus is a tubular three-layered structure that courses upward between peritoneum and transversalis fascia from the anterior dome of the bladder toward the umbilicus. Failure of the urachal lumen to close will result in one of the several presentations of urachal anomalies. Our patient had a vesico-urachal diverticulum with an alternating sinus draining intermittently via the umbilical route. Clinically these patients may present in different ways. Patent urachus usually presents soon after birth but not until the cord separates from the umbilicus. A distal obstruction may be present which can be visualized or ruled out by voiding cystourethrography.

Some patients may present with lower abdominal mass in the midline (urachal cyst) and others as omphalitis. Chronic urinary tract infection and stone formation may be the presenting symptoms in long-standing cases of large urachal diverticuli. In many cases there are no symptoms and the anomaly may be found incidentally during unrelated studies. The interesting finding in our patient was the inversion and complete disappearance of the umbilicus in the final stages of voiding. In fact, detrusor muscle contraction pulled the umbilicus inward through the urachal attachment.

REFERENCES

1. King LR, Kelalis PP: Clinical Pediatric Urology. Philadelphia, WB Saunders, 1985.
2. Blichert-Toft M, Nielsen OV: Congenital Patent urachus and acquired variants. *Acta Chir Scand.* 137:807-814, 1971.
3. Nix JT, Menville JG, Albert M, et al: Congenital patent urachus. *J Urology*, 79:264-273. 1958.