

Progressive visual and hearing loss as looming manifestations of spinal meningeal melanocytoma

Bahram Haghi-Ashtiani¹, MD, Farzad Sina², MD, Fowzieh Ben-Isa³, MD
Mohammad Rohani⁴, MD.

Dept. of Neurology, Rasoul Akram Hospital, Iran University of Medical Sciences, Tehran, Iran.

Abstract

Meningeal melanocytoma is a rare tumor of nervous system, which originates from leptomeningeal melanocytes. The locations of melanocytoma in the nervous system are most frequently in the posterior fossa or along the spinal cord, and usually appear as an extra-axial mass. The manifestations of tumor are most often due to its compressing effect on adjacent nervous structures that causes various neurological signs and symptoms depending on its locations. It may also cause superficial siderosis of the central nervous system [1]. In this case we describe another manifestation of this tumor which raised intracranial pressure and developed its neurological signs and symptoms. The patient was a 33-year old man with a two-year history of headache and tinnitus, transient diplopia, and had also a three-month history of progressive bilateral visual and hearing loss. The medical investigations of the patient reveal raised intracranial pressure (RICP) with a high concentration of protein in the cerebrospinal fluid, and an extra-axial mass at the T11-12 level in magnetic resonance imaging of the spinal cord. The patient underwent surgical removal of the tumor, in which the pathological study characterized the tumor as a meningeal melanocytoma. After surgery the CSF pressure returned to normal state, and its protein level decreased. The patient's hearing loss improved significantly but the visual defect did not change.

Base on various causes of the RICP, especially when there is abnormality in CSF protein without any known cause, we must consider melanocytoma as a treatable cause, and thus in such patients, performing spinal cord magnetic resonance imaging (MRI) is a valuable technique for diagnosis as well as investigation.

Keywords: melanocytoma, spinal tumor, raised intracranial pressure.

Introduction

The term "meningeal melanocytoma" was first used by Limas and Tio in 1972 to describe a benign tumor of melanocytic origin arising from the leptomeninges [2]. In the World Health Organization classification of brain tumor, meningeal melanocytoma represents a subgroup of primary melanocytic lesion, which most frequently originates from the lep-

tomeninges of posterior fossa or along the spinal cord [3]. The melanocytic lesion of the CNS may also be a primary or metastatic malignant melanoma, and it is important to differentiate melanocytoma from these malignant tumors [2,4]. There are also other differential diagnoses for melanocytoma such as melanotic meningioma or melanotic schwannoma [5].

Meningeal melanocytoma usually produces a slowly progressive mass effect on adjacent neural structures [4]. Coincident superficial

1. **Corresponding author**, Neurology Ward, Rasoul Akram Hospital, Iran University of Medical Sciences, Tehran, Iran. Tel:+9821 66515000. E-Mail:bhaghi2000@yahoo.co

2-4. Neurologist.

siderosis of the CNS has been reported [1]. The presentation of tumors with raised intracranial pressure (RICP) is unusual and, in our case, tumor manifests itself by the signs and symptoms of the RICP. These tumors are generally benign and can be cured by complete surgical resection, although local recurrences have been observed [6-9]. Therefore close follow-up study of patients is needed.

In the magnetic resonance imaging (MRI) studies of meningeal melanocytoma most of the tumors produce iso to high signal intensity in T1-weighted and iso to low signal intensity in T2-weighted images [10].

In pathological study the differential diagnosis of this lesion with uniform proliferation of spindle or epithelioid cells was meningioma or schwannoma. The meningioma is reactive for EMA and not for markers such as HMB-45 which is vice versa in our case. Absence of some unmistakable features of conventional schwannoma, presence of plump, polygonal cells organized in nests with open chromatin were against the diagnosis of melanocytic schwannoma. Lack of conspicuous pleomorphism, mitosis, necrosis and prominent nucleoli could excluded melanoma from differential diagnoses.

Case report

A 33-year old man was admitted to Rasoul hospital because of progressive bilateral visual and hearing loss starting three-month earlier. He also had a two-year history of headache and tinnitus, which he did not noticed before. In one-year earlier he had a history of diplopia when underwent lumbar puncture and taking Acetazolamide, and thereafter his diplopia improved after 10 days, but he did not follow his medications. At the time of admission, his neurological exams revealed bilateral optic disc swelling and visual acuity about hand motion perception. Hearing perception was decreased and an audiogram showed bilateral sensory neural hearing loss of about 70%, especially in

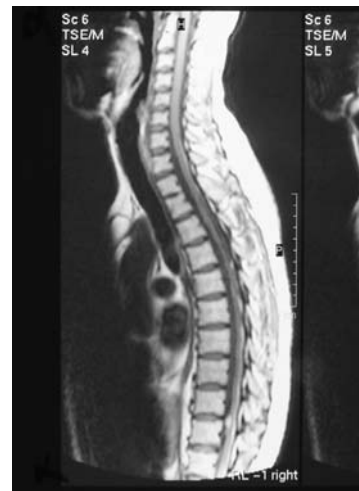


Fig. 1. Hyper signal lesion in T1-MRI sequence at T11-12 level.

high tone frequencies. Other cranial nerves were intact. Motor and sensory examinations were normal. Both plantar reflexes were downward.

The Magnetic resonance imaging (MRI) scans of the brain were normal. The first lumbar puncture revealed an opening pressure of 280 mm water. Analysis of the cerebrospinal fluid demonstrated an elevated protein of 98 mg/dl (normal <46 mg/dl), without any cells. The CSF formula was otherwise normal, as were urinalysis and baseline serologic studies. The CSF cytologic study was normal. His lumbar puncture was repeated several times during hospitalization and showed a rising CSF protein level of up to 500 mg/dl. In order to exclude systemic sarcoidosis and vasculitis, several investigations such as chest computed tomography and plasma and CSF Angiotensin Converting Enzyme (ACE) level were performed. All were normal.

The rising CSF protein and high opening pressure of LP encouraged us to perform a magnetic resonance imaging along the entire spinal axis that revealed an ovoid extra-axial mass at T11-12 level of spinal cord. The lesion appeared as a high-intensity mass in the T1-weighted, and a low-intensity mass in the T2-weighted MRI (Fig.1).

The patient underwent surgical removal of the tumor, and his spinal mass was resected entirely. The pathological study revealed microscopically the tumor composed of uniform spindle cells arrayed in fascicles and compactly whorled nests with cytoplasmic melanization which particularly was advanced at the periphery of whorled nest (which were bordered by cluster of macrophages, melanophages). Tumor cell nuclei showed spindle to ovoid vesicular nuclei with small centrally positioned eosinophilic nucleoli. No evidence of conspicuous nuclear atypia, pleomorphism, mitosis or necrosis could be found (Fig2a).

The tumor cells showed diffuse and strong immunoreactivity for S-100 protein and HMB-45 (Fig2b). Immunoreactivity for the EMA was negative (Fig2c).

After surgical removal of the tumor, we examined his CSF several times, which showed us an opening pressure about 160 mm water and a decreased protein level to 110 about two weeks later. During hospitalization and after several CSF drainages, and especially after surgery, the patient's hearing loss improved significantly, and his audiogram revealed about a 50% improvement in hearing. When the patient was discharged he was recommended for a follow-up investigation and doctor visits every one month.

Discussion

In our study melanocytoma of the thoracic spinal cord caused the RICP. The spinal tumors are an uncommon but well-documented cause of RICP. In most cases, spinal cord tumors have manifested localizing clinical signs, including back pain, weakness, and sensory loss, to suggest pathologic changes in the spine [11-16]. In the review of cases reported by Matzkin et al. in 1992 [11], spinal tumors often present with lumbar pain (65 to 70% cases), yet those associated with papilledema are more likely to present with headache, nausea, vomiting, and vision loss. Oikawa et al. [12] reported a case,

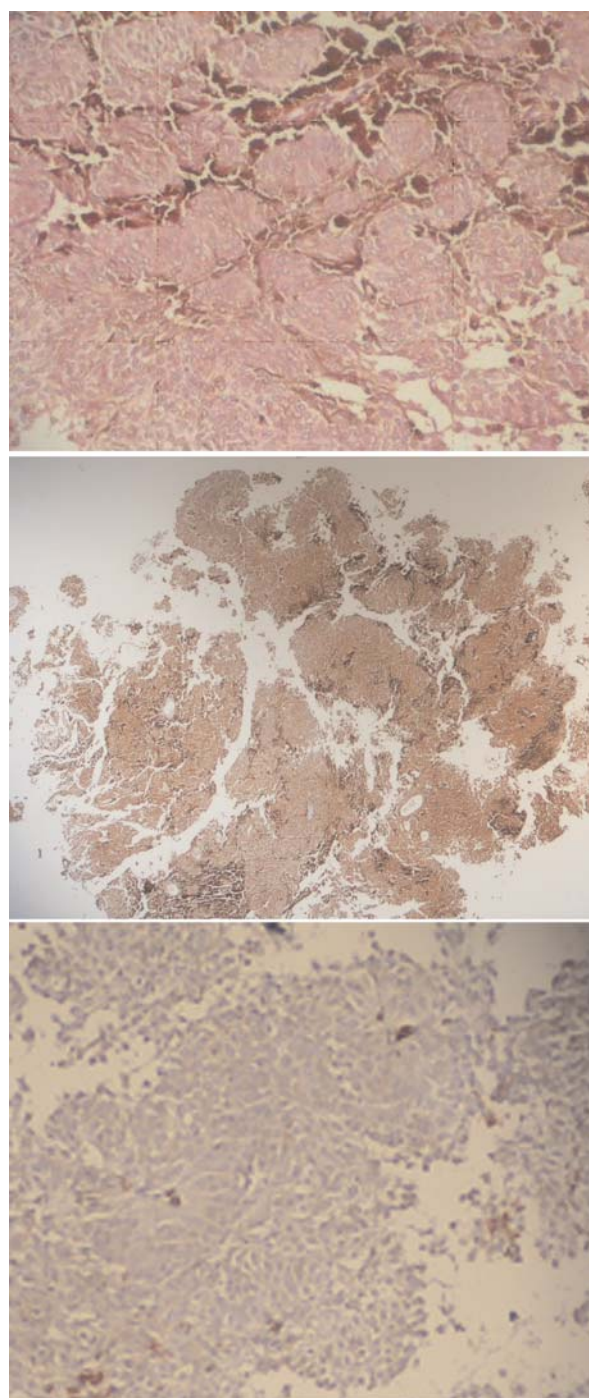


Fig.2, a,b,c: Pathologic finding of biopsy, discussed in the paper.

similar to ours, of progressive vision loss and papilledema in a patient with multiple spinal neurinomas, in whom there were no spinal symptoms. In that review [12], 6 of 34 patients had a visual disturbance as their presenting manifestation of spinal cord tumor. Of these 6,

neurologic examination disclosed that 4 had signs or symptoms of spinal dysfunction, one received a diagnosis with a spinal tumor three months later with pain in the right leg and back, and 1 patient had no spinal symptoms or signs. Most tumors have been located in lower spinal levels, usually in the thoracolumbar or lumbosacral regions [11, 13, 14, 15, 17].

Several mechanisms have been proposed to explain how such spinal tumors may increase intracranial pressure. In cervical cord lesions, raised intracranial pressure has been ascribed to rostral extension and CSF flow obstruction at the level of the medullary exit foramina [11]. This mechanism is not plausible in cases of papilledema resulting from lower spinal lesions, which represent the majority of cases. Why do these patients have increased intracranial pressure? At present, there are no compelling answers to this.

In some cases, the CSF protein levels are sufficiently high to lead to sledging at the level of the arachnoids' villi, but not all reports of hydrocephalus or the pseudo tumor cerebri syndrome in patients with spinal cord tumors are associated with high levels of protein. Most cases show only modest increases. The most likely explanation for elevated intracranial pressure in those cases may relate to the release of a tumor-generated chemical into the CSF that leads to failure of CSF absorption. Removal of the tumor will then lead to the normalization of intracranial pressure. Several potential chemical markers have been suggested. One is fibrinogen, which is converted to fibrin in the CSF. If fibrin creates a blockage at the level of the basal cisterns, it would cause hydrocephalus. If it creates a blockage at the level of the arachnoids' villi, it could lead to the pseudo tumor cerebri syndrome [16]. Another interesting candidate is the inflammatory cytokine TGF [beta]. Found in a variety of primarily vascular structures such as the choroid plexus, TGF [beta] is present in high concentrations in platelets and has been shown to result in the

proliferation of leptomeningeal cells and the creation of scarring both at the base of the brain and in the area of the arachnoids' villi [18]. The final explanation for increased intracranial pressure in the presence of spinal cord tumors will have to await further delineation of the chemical composition of the CSF in these patients.

In summary, the finding of papilledema with normal cranial imaging and raised CSF protein may herald a spinal tumor, and appropriate spinal imaging is necessary to secure the diagnosis.

References

1. Matsumoto Sh., et al. Spinal meningeal melanocytoma presenting with superficial siderosis of the central nervous system. *Journal of neurosurgery* 1998;88 :890-894.
2. Limas C, Tio FO. Meningeal melanocytoma ("melanotic menin-gioma"): its melanocytic origin as revealed by electron microcopy. *Cancer* 1972 ;30:1286-1294.
3. Klehhues P, Burger PC, Scheithauer BW: Thw new WHO classification of brain tumours. *Brain Pathol* 1993; 3:255-268.
4. Maiuri F, Iaconetta G, Benvenuti D, et al: Intracranial meningeal melanocytoma: case report. *Surg Neyrol* 1995;44:556-561.
5. Hirose T, Horiguchi H, Kaneko F, et al: Melanocytoma of the foramen magnum. Case report. *Pathol Int* 1997;47:155-160.
6. Botticelli AR et al: Meningeal melanocytoma of Meckel's cave associated with ipsilateral Ota's nevus. Case report. *Cancer* 1983;51:2304-2310.
7. Jelliger K, et al: Meningeal melanocytoma. Report of a case and review of the literature. *Acta Neurochir* 1988;94:78-87.
8. Steinberg JM, et al: Meningeal melanocytoma with invasion of the thoracic spinal cord. case report. *J Neurosurg* 1978;48:818-824.
9. Winston KR, et al: meningeal melanocytoma. Case report and review of the clinical and histological features. *J Neurosurg* 1987;66: 50-57.
10. Edward J, et al: MR of spinal meningeal melanocytoma. *AJNR* 1997;18:180-182.
11. Matzkin DC, Slamovits TL, Genis I, et al. Disc

swelling: a tall tail? *Surv Ophthalmol* 1992 ; 37:130-6.

12. Oikawa S, Kyoshima K, Takemae T, et al. Multiple spinal neurinomas presenting visual disturbance as the initial symptom: case report. *Surg Neurol* 1992; 38:309-14.

13. Tanaka K, Waga S, Shimosaka S. Papilledema and spinal cord tumors. *Surg Neurol* 1988; 29 :462-6.

14. Raynor RB. Papilledema associated with tumors of the spinal cord. *Neurology* 1969 ; 19:700-4.

15. Farmilo RW, McAuley DL, Osborne DR. Papilloedema and spinal cord tumours. *N Z Med J* 1974; 80:100-4.

16. Ammerman B, Smith DR. Papilledema and spinal cord tumors. *Surg Neurol* 1975; 3:55-7

17. Glasauer FE. Thoracic and lumbar intraspinal tumours associated with increased intracranial pressure. *J Neurol Neurosurg Psychiatry* 1964; 27:451-8.

18. . Motohashi O, Suzuki M, Yanai N, et al. Thrombin and TGF-beta promote human leptomeningeal cell proliferation in vitro. *Neurosci Lett* 1995; 190: 105-8.