

Bizarre parosteal osteochondromatous proliferation of the ring finger: a case report and review of the literature

Dawood Jafari, MD.¹, Hamid Taheri, MD.², Hooman Shariatzadeh, MD.³
Khodamorad Jamshidi, MD⁴., Alireza Pahlevansabagh, MD⁵

Department of Hand Surgery, Shafa Yahyaian Hospital, Iran University of Medical Sciences, Tehran, Iran.

Abstract

Bizarre parosteal osteochondromatous proliferation (BPOP), also known as Nora's lesion is a rare osteocartilaginous lesion composed of a disorganized mixture of cartilage, bone, and fibrous tissue. In this article we report a case of BPOP arising on the proximal and middle phalanx of ring finger in a 31 year-old woman. The clinical, radiographic, MR imaging and histopathologic findings of it are described. The symptoms regressed spontaneously in 2 month after incisional biopsy.

Keywords: benign tumor, phalanges, bizarre parosteal osteochondromatous proliferation, Nora's lesion.

Introduction

In 1983, Nora et al. [1] described a rare tumor in the hand and foot and called it bizarre parosteal osteochondromatous proliferation (BPOP). BPOP is a rare osteocartilaginous lesion of bone composed of a disorganized mixture of cartilage, bone, and fibrous tissue [2]. It arises most commonly in the small bones of the hands and feet but also has been reported in other bones, including the long bones of the upper and lower limb [1, 3]. BPOP is thought to be a reactive lesion, closely related to florid reactive periostitis, subungual exostosis, and turret exostosis [4]. In the literature this disorder has been referred to by a confusing variety of names: pseudomalignant osseous tumor of the digits [5], extraosseus localized non-neoplastic bone, cartilage formation or myositis ossificans. Careful histologic examination is usually

necessary to distinguish this benign lesion from other disorders, due to the fact that this disorder has specific pathological characteristics. Clinical course is typically benign and local resection is the definitive treatment. However, recurrences have been reported that required more aggressive management. This report is unique because of spontaneous regression of BPOP affecting the ring finger after incisional biopsy of the lesion over the time.

Case report

A healthy 31-years old right-handed housewife presented with a 3-months history of a progressive growing painful mass on the proximal and middle phalanx of her left ring finger. Her past history was notable for superficial second degree burning injury of this finger 6 months ago. The pain worsened gradually during this 3 month. Physical examination revealed a mass adjacent to the proximal and middle phalanx

1&2&4. Associate Professor of Orthopaedic Surgery, Iran University of Medical Sciences, Tehran, Iran

3. Assistant Professor of Orthopaedic Surgery, Iran University of Medical Sciences.

5. **Corresponding author**, Hand Surgery Fellow, Shafa Yahyaian Hospital, Baharestan Sq. Tehran, Iran. Tel: +9821 33542022.

E Mail: pahlevansabagh@yahoo.com

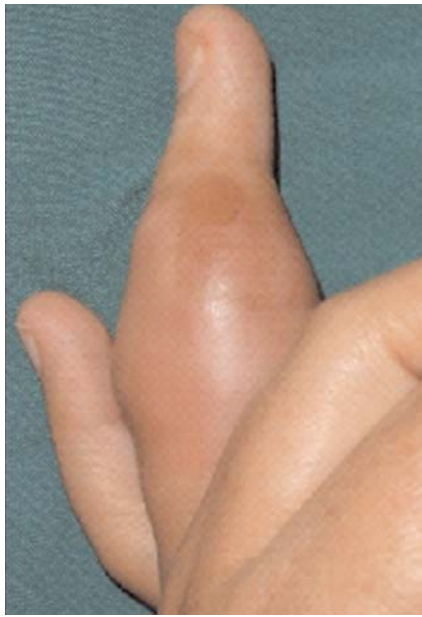

Fig. 1. Photography of left ring finger showed erythema and soft tissue swelling.

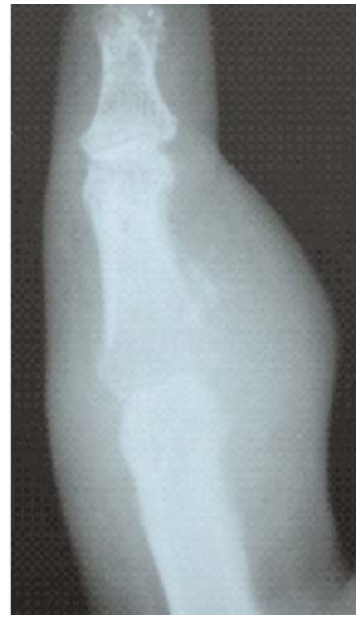

Fig. 2. Radiograph of left ring finger.

with subcutaneous swelling (Fig. 1). The tumor was remarkably hard and seemed to be fixed to the skeleton of the finger. The overlying skin was pink and the tumor was severely tender. The PIP joint range of motion was limited compared to the right ring, whilst motion of the

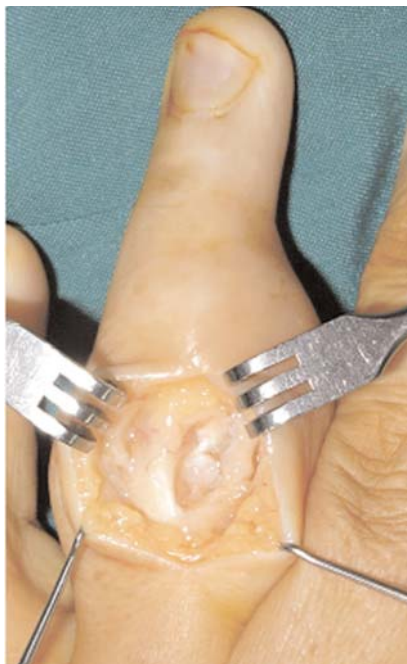

Fig. 3. An incisional biopsy was performed.

metacarpophalangeal joint was unaffected. The sensibility and vascularity was normal. During the patient's first visit to our hospital, diffuse swelling, heat, erythema and tenderness around the ring all indicated a local inflammation. Signs of infection, such as fever, cellulitis or lymphadenopathy, were absent. Laboratory study results, including C-reactive protein, complete blood count, erythrocyte sedimentation rate and serum levels of calcium, phosphorus, alkaline phosphatase and uric acid were within normal range. The radiographs (Fig. 2) revealed increased soft tissue density surrounding the proximal and middle phalanx; the cortex was intact and fine periosteal reaction was obvious. Magnetic resonance imaging (MRI) indicated a mass surrounding the proximal and middle phalanx. This mass was iso-intense on T1-weighted images, high-intense on T2-weighted images. Soft tissue around the lesion also showed high intensity on T2 images, indicating edema. The clinical and radiological symptoms were interpreted as "malignant tumor." The finger was explored and an incisional biopsy was performed. The tumor was adhering to the bone and extensor tendon (Fig. 3).

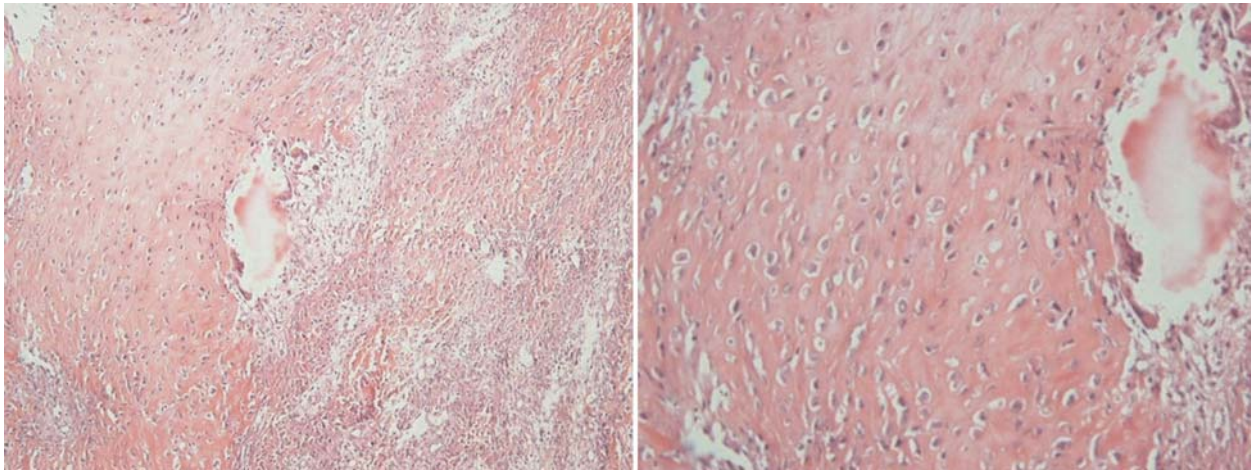


Fig. 4. Photomicrographs of this case.

Macroscopically the mass appeared to be soft and creamy in color. Specimen for light microscopy were fixed in 6% formalin and imbedded in paraffin. The 5 μ m sections were stained with hematoxylin and eosin. The lesion consisted of a mixture of cartilage, bone and fibrous tissue. The cartilaginous fragments were of moderate cellularity. The chondrocytes showed mild nuclear atypia. No mitotic figures were found. The immature bone trabeculae were unevenly calcified and lined by prominent but cytologically benign osteoblasts. The intermixed fibrous tissue showed no abnormalities (Fig. 4). The histology was described as a BPOP. Aerobic and anaerobic cultures were negative. After incisional biopsy and under careful observation of the clinical and radiological features, the pain disappeared in 2 month without any administration of medicine and the mass spontaneously decreased in size as seen on photography (Fig. 5). Three months after the first MRI, another MRI study was performed for re-evaluation. The mass surrounding the phalangeal bone was markedly reduced in size, both T1- and T2-weighted images showed low intensity indicating hardening of the lesion, and few inflammatory signs were seen in the soft tissue around the bone. Twenty months after onset, no more clinical and radiological symptoms were

observed and the patient had regained full range of interphalangeal motion. To evaluate any recurrence, clinical examinations and X-rays will be performed every 3 months.

Discussion

In 1981 Spjut and Dorfman [6] reported cas-

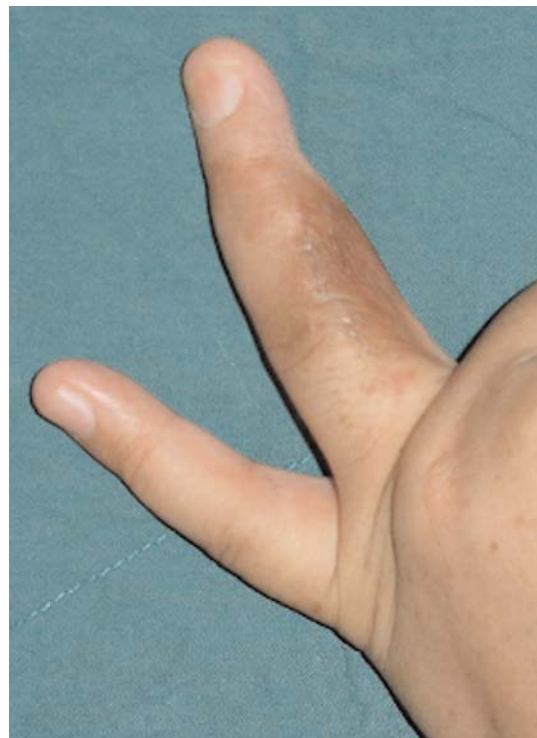

Fig. 5. Photograph two month after incisional biopsy.

es of reactive florid periostitis in hand and feet phalanges. All their cases showed abundant osteoid production from a proliferative fibrous stroma. Because periosteum was involved in all cases, these investigators coined the term "florid reactive periostitis (FRP)" to more accurately describe the pathogenesis of the lesion. Florid reactive periostitis is more frequent in the second and third decades of life [7]. There are more women than men suffering from florid reactive periostitis [8]. These tumors are usually found in hand phalanges. Brien et al [9] describe a case of a florid reactive periostitis of the tibia as an atypical case of tubular bones.

In 1983 Nora et al [1] described cases of bizarre parosteal osteochondromatous proliferations. Although the lesions they described showed some histological similarities to those reported by Spjut and Dorfman [6], there was a pronounced tendency to local recurrence, approximately 50% of cases, and they considered this to be a distinct process from the one described by Spjut and Dorfman [6]. Male and females were equally affected and the age range was very broad [10]. BPOP usually arises in the small tubular bones of the hands and feet but has very rarely been reported in other bones, including the humerus, radius, ulna and clavicle [2,3,11]. So far many synonyms such as myositis ossificans, parosteal fasciitis, pseudosarcomatous fibromatosis, and fasciitis ossificans have been used to describe FRP and BPOP [1,6,12,13]. FRP is a typical tumor of soft tissue of the hand with a membranous type of ossification: direct ossification of fibrous tissue without the cartilaginous stage. Enchondromal ossification can be seen in BPOP [10].

Yuen et al. observed considerable overlap between lesions identified as FRP and BPOP and also suggested that FRP could progress to BPOP. They therefore proposed the term "proliferative periosteal process of phalanges" for such non-neoplastic reactive changes accompanied by bone formation (D20).

Typical clinical findings are soft tissue tu-

mors, differing degrees of pain and swelling, and a skin erythema of several month evolutions.

When a soft tissue swelling occurring in a small tubular bone of the hand as in our case is encountered, infection, tumor, fracture or inflammation must be considered as possible local causes and secondary pulmonary hyperostosis as a systemic cause. Fracture is a well-known and frequently encountered problem in the hand and its presence or absence can be determined by examining the patient's history. Two other causes of soft tissue swelling, infection and inflammation, may be excluded by physical examination, laboratory studies and radiological findings. Tumor, parosteal and periosteal osteosarcoma, which are rare in small tubular bones, also must be included in a differential diagnosis.

Histologically and radiologically there is an overlap between BPOP, florid periostitis, parosteal osteosarcoma and osteochondroma [4]. In BPOP there is a disorganized proliferation of fibrous tissue, cartilage and bone. Contrary to osteosarcoma, no atypical fibrous spindle cells are present. The chondrocytes are bizarre, enlarged and sometimes binucleated. Ossification is unlike osteochondroma or a subungual exostosis, very irregular and has an appearance similar to callus tissue. In addition, direct metaplasia from fibroblast to osteoblast (membranous ossification) can be observed, similar to florid periostitis. In the latter, however, cartilage is absent. In contrast to florid periostitis, periosteal reaction is absent in BPOP [4,14]. The most common differential diagnosis is osteochondroma. BPOP is distinguished histologically by the absence of organized cartilage and endochondral ossification, as well as the presence of areas of fibroblast proliferation and fibrocartilaginous and fibroosseous metaplasia [1,2]. Radiologically there is no continuity with the cortex of the medullary canal in BPOP. In osteochondroma the cortex flares out and there is communication with the medullary

canal [10]. Our case did not present any evidence of cortical bone erosion. The authors think that resonance magnetic scans do not yield more data than clinical and radiographic evaluation, although they may allow us to define better tumor location and infiltration of neurovascular bundles. It may also be of help in assessing recurrence after surgical excision.

Due to painful swelling and bone formations with the radiological appearance of tumorous lesions, some surgical treatment including marginal resection and ray amputation is often selected for these lesions [7]. BPOP, however, is known to recur frequently, in over 50% of cases [15]; this feature, in addition to the finding of a number of cytogenetic abnormalities, including at (1;17)(q32;q21) translocation, has led to the suggestion that BPOP represents a neoplastic rather than a reactive lesion [16]. Malignant transformation, except in 1 case of fibrosarcoma arising in association with BPOP [17], has not been reported and is not considered typical of this lesion.

In our case, after incisional biopsy the pain disappeared in 1 month and the mass spontaneously decreased in size and after twenty months no recurrence was observed. Therefore in view of the possibility of this disease becoming spontaneously regressive, careful follow-up may be preferable to immediate surgery.

Due to high rate of recurrence, clinical examinations and X-rays were performed every 3 months. The association with scar of burning was not reported. We could not find any relationship between the two pathologies.

References

1. Nora F, Dahlin D, Beabout J. Bizarre parosteal osteochondromatous proliferation of the hands and feet. *American Journal of Surgical Pathology* 1983; 7: 245-50.
2. Abramovici L, Steiner GC. Bizarre parosteal osteochondromatous proliferation (Nora's lesion): a retrospective study of 12 cases, 2 arising in long bones. *Hum*

Pathol 2002;33:1205-10.

3. Bush JB, Reith JD, Meyer MS. Bizarre parosteal osteochondromatous proliferation of the proximal humerus: case report. *Skeletal Radiol* 2007;36:535-40.

4. Yuen M, Friedman L, Orr W, Cockshott WP. Proliferative periosteal processes of phalanges: a unitary hypothesis. *Skeletal Radiol* 1992;21:301-3.

5. Bulstrode C, Helal B, Revell P. Pseudo-malignant osseous tumour of the soft tissue. *J Hand Surg* 1984;9B:345-6.

6. Spjut HJ, Dorfman HD. Florid reactive periostitis of the tubular bones of the hands and feet: a benign lesion, which may simulate osteosarcoma. *Am J Surg Pathol* 1981;5:423-33.

7. Rogers GF, Mark A, Brzezienski MD, Chattanooga TN. Florid reactive periostitis of the middle phalanx: a case report and review of the literature. *J Hand Surg* 1999;24A:1014-8.

8. Riaz M, McCluggage WG, Bharucha H, Small JO. Florid reactive periostitis of the thumb. *J Hand Surg* 1996;21B:276-9.

9. Brien EW, Zahiri CA, Mirra JM. Florid reactive periostitis ossificans of the proximal aspect of the tibia: a lesion that must be distinguished from osteosarcoma. *J Bone Jt Surg* 1999;81A:1002-7.

10. De Smet L, Lambert I, Sciort R. Bizarre parosteal osteochondromatous proliferation of the hand: report of two cases. *Chirurgie de la Main* 2001;20: 247-50

11. Smith NC, Ellis AM, McCarthy S, McNaught P. Bizarre parosteal osteochondromatous proliferation: a review of seven cases. *Aust N Z J Surg* 1996;66:694-7.

12. Dupree W B, Enzinger F M. Fibro-osseous pseudotumor of the digits. *Cancer* 1986;58: 2103-2109

13. Tang J B, Gu Y Q, Xia R G. Fibro-osseous pseudotumor that may be mistaken for a malignant tumor in the hand: a case report and review of the literature. *J Hand Surg* 1996;21-A: 714-716

14. De Lange E, Pope T, Fechner R, Keats T. Bizarre parosteal osteochondromatous proliferation versus benign florid reactive periostitis. *American Journal of Radiology* 1987; 148: 650.

15. Meneses MF, Unni KK, Swee RG. Bizarre parosteal osteochondromatous proliferation of bone (Nora's lesion). *Am J Surg Pathol* 1993;17:691-7.

16. Endo M, Hasegawa T, Tashiro T, Yamaguchi U, Morimoto Y, Nakatani F, et al. Bizarre parosteal osteochondromatous proliferation with a t(1;17) translocation. *Virchows Arch* 2005;447:99-102.

17. Choi JH, Gu MJ, Kim MJ, Choi WH, Shin DS, Cho KH. Fibrosarcoma in bizarre parosteal osteochondromatous proliferation. *Skeletal Radiol* 2001;30:44-7.