

INSULINOMA NEW CONCEPTS IN MANAGEMENT

MOHAMMADREZA KALANTAR MOTAMEDI, M.D., FACS
AND MOHAMMADHASAN KALANTAR MOTAMEDI, M.D

*From the Department of General and Vascular Surgery and Traumatology,
Shohada Medical Center, Shahid Beheshti University of Medical Sciences,
Tehran, Islamic Republic of Iran.*

ABSTRACT

In this report, nine patients with insulinoma who were operated on between 1985 and 1993 at the Shohada Medical Center affiliated to the Shahid Beheshti University of Medical Sciences in Tehran are presented. There were three males and six females (male to female ratio 1:2) and the patients' age ranged from 23 to 60 years old (mean age 37.6 years old). Duration of symptoms was from three months to three years (average 18.2 months) and consisted of weakness, fainting, cold sweats, tremor, syncope, seizures and coma.

Preoperative localization procedures consisting of sonography, CT scan and selective angiography were performed for all patients and at least one of them was positive in five patients (55%), with CT scan being the most helpful.

At surgery, 11 tumors were found in seven patients, (78% positive surgical findings), of which two were in the head, four in the body and five in the tail of the pancreas. Of the two patients in whom no tumor was found at surgery, one patient who underwent 95% pancreatectomy with preservation of the spleen was cured and normoglycemic postoperatively, but the second patient, despite a distal pancreatectomy up to the level of the superior mesenteric vein, remained symptomatic. Thus our overall success rate is 88.9%. The surgical procedures performed consisted of distal pancreatectomy with splenectomy in three patients, enucleation alone in three patients, distal pancreatectomy preserving the spleen in two patients and distal pancreatectomy with enucleation in one patient.

Insulinoma is a surgically correctable disease, but requires a high index of suspicion if diagnosis is not to be delayed and severe neurological sequelae prevented. Tumor enucleation when possible or distal subtotal pancreatectomy preserving the spleen as described in detail are recommended by the authors as the procedures of choice, and with careful technique, excellent results are possible. In this paper, we present nine patients treated at our center and compare our results with that reported in the literature.

MJIRI, Vol. 9, No. 2, 91-95, 1995.

INTRODUCTION

Insulinoma is the most common endocrine tumor of the pancreas. In up to 90% of cases, it is caused by a solitary benign pancreatic beta-cell adenoma amenable to surgical treatment. Malignant insulinoma is present in 10-15% of patients.^{1,12,13}

Clinical symptoms are characteristic and may be either mainly due to release of catecholamines induced by hypoglycemia (tremor, palpitation, tachycardia, hunger, sweating) or inadequate glucose for metabolism by the brain (headache, confusion, obtundation, seizures, coma), depending on the rate of fall in blood sugar.

Insulinoma is generally stated to occur equally in both sexes with most patients presenting in the 4th-7th decades.² Diagnosis is based on documentation of insulin levels inappropriately elevated with respect to blood glucose levels, or onset of hypoglycemic symptoms during a 72-hr fast.¹

The only permanent cure for organic hyperinsulinism is surgical removal of the offending lesion. Preoperative localization studies consisting of ultrasound, CT scan, selective pancreatic arteriography and percutaneous transhepatic portal venous sampling are recommended prior to surgery, and a combination of these studies are positive in up to 80% of patients. Even if all are negative however, exploratory surgery is indicated.^{1,5-7}

In this article, nine patients with biochemically-documented hyperinsulinism who were treated at the Shohada Medical Center in Tehran between 1985 and 1993 are presented and the relative clinical features and recommended surgical technique for management are discussed.

MATERIAL AND METHODS

Patients

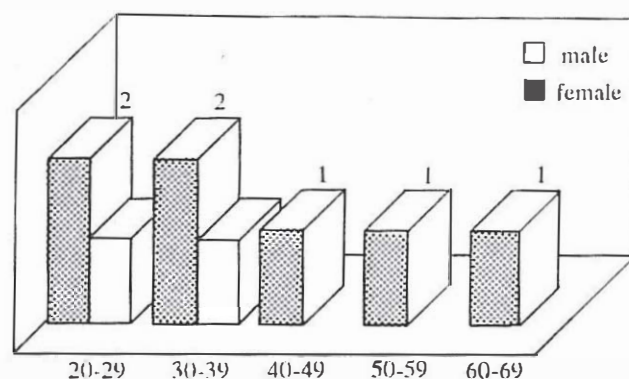
Nine patients, six female and three male (male to female ratio, 1:2) with age ranging from 23 to 60 years old (mean age, 37.6 years old) who presented with symptoms and signs suggestive of hyperinsulinism to the Shohada Medical Center from 1985-1993 were evaluated. The main symptoms were weakness, fainting, tremor, sweating, syncope, seizures, and coma. Duration of symptoms was from three months to three years (average 18.2 months). Weakness and diaphoresis ("cold sweats") were the most common symptoms, present in 66.7% of patients, followed by convulsions (55.5%), syncope (44.4%), coma (44.4%), tremor (22.2%), blurred vision (22.2%), and history of treatment for presumed epilepsy (22.2%) (Tables I, II).

Diagnosis

Aside from meeting the criteria of Whipple's triad (see

Table I. Characteristics of 9 patients with insulinoma

Patient	Age	Sex	Major symptoms
1	23	F	syncope, sweats, blurred vision, coma
2	24	F	tremor, sweats, convulsions
3	24	M	weakness, syncope
4	34	F	weakness, syncope
5	35	M	weakness, syncope, blurred vision, sweats
6	36	F	coma, convulsions, brain damage
7	49	F	weakness, syncope, sweats, MEN-I
8	54	M	weakness, convulsions, brain damage
9	60	F	convulsions, coma



Shohada Medical Center, 1985-1993

Table II. Age and sex distribution of the patients

Discussion), diagnosis of organic hyperinsulinism was made by simultaneous measurement of serum insulin and glucose levels, and demonstration of inappropriately elevated insulin levels with respect to serum glucose in all patients. The lowest recorded blood sugar level of the patients ranged from 1mg/dl to 27 mg/dl (average lowest blood sugar level 15.8 mg/dl). Serum insulin levels ranged from 44 μ U/ml to 84 μ U/ml (max. normal, 25 μ U/ml). Performing a 72-hr fast was not required in any of our patients for diagnosis.

Preoperative localization

All of our patients underwent at least one preoperative localization study based on availability. These consisted of sonography, CT scan, and selective visceral arteriography. At least one of these studies was positive in five of nine patients (55% sensitivity), with CT scan being the most helpful (55% sensitivity). Sonography was performed in seven patients, and was positive in only one patient (14.3% sensitivity). Angiography was performed in two patients and was negative in both. These figures are consistent with the current literature which cite sensitivities of 26-61% for sonography,^{3,4} 17-73% for CT scan,^{3,4,11} and 35-66% for angiography.^{3,4,10,11} Transhepatic portal venous sampling, a new technique for localization of insulinomas, is claimed to be the most ac-

Table III. Tumor data and surgical procedure

Patient	Tumor size, place	Surgical procedure	Result
1	3×3 cm, body	distal pancreatectomy + splenectomy	cured
2	2×1.5 cm, tail	distal pancreatectomy + splenectomy	cured
3	.5×.5 cm, tail	enucleation	cured
4	not found	95% pancreatectomy saving spleen	cured
5	2×1.5 cm, tail	enucleation	cured
6	1 head, 2 body, 1 tail	distal pancreatectomy + splenectomy	cured
7	2.5×2cm tail, 1×1 cm body	distal pancreatectomy + splenectomy	cured
8	not found	distal pancreatectomy saving spleen	not cured
9	1.5×1.5cm, head	enucleation	cured

Shohada Medical Center, 1985-1993

Table IV. Classification of pancreatic endocrine tumors

Name	Hormone	Cell	Syndrome	Malignancy
insulinoma	insulin	beta	hypoglycemia	< 15%
gastrinoma	gastrin	non-beta	peptic ulcer, diarrhea	50 - 60%
vipoma	VIP	non-beta	WDHA	majority
glucagonoma	glucagon	alpha	hyperglycemia, dermatitis	majority
somatostatinoma	somatostatin	delta	hyperglycemia, steatorrhea	majority

curate localization study with sensitivity of 75-100% being reported,^{3,5,6,9-11} but was not available to us.

Surgical technique

Patients were prepared for surgery by giving an infusion of 10% dextrose in water solution and three patients also required diazoxide to prevent hypoglycemia. The bilateral subcostal (chevron) incision was used most often and in our opinion provides the best exposure to the pancreas. After initial exploration of the abdominal cavity and palpation of the liver for metastases, a wide Kocher maneuver is performed and the head of the pancreas is carefully palpated for tumor. The body and tail of the pancreas are explored by dividing the gastrocolic ligament close to the transverse colon and entering the lesser sac. It cannot be overemphasized that the entire pancreas must be carefully explored and palpated. Common extrapancreatic sites for tumor such as the duodenum, small bowel mesentery and lymph nodes should also be examined.

For small benign adenomas not in proximity to the pancreatic duct and located superficially anywhere in the gland, simple enucleation of the tumor is sufficient. For

larger lesions located more deeply in the body and tail, distal pancreatectomy with splenectomy is traditionally performed. For lesions in the head and uncinat process not amenable to enucleation, a pancreaticoduodenectomy may be required.

Our preferred procedure for resection is a 95% distal pancreatectomy with preservation of the spleen. This is a technically demanding procedure and requires great skill in carefully dividing and ligating the many fine branches of the splenic artery which supply the body and tail of the pancreas, but the benefit of splenic preservation with its concomitant lower morbidity makes this procedure definitely worthwhile.

RESULTS

In this series of nine patients with biochemically-documented organic hyperinsulinism who underwent exploratory laparotomy, 11 tumors were found in seven patients (78% positive exploration). Two patients had multiple tumors (22.2%). The size of the tumor was from 0.5cm to 3cm in diameter and two were in the head

(18%), four in the body (36%), and five in the tail of the pancreas (45%). All tumors were confirmed by intraoperative frozen-section biopsy to be islet-cell tumor. Enucleation alone was done in three patients, distal pancreatectomy with splenectomy in three patients, distal pancreatectomy with preservation of the spleen in two patients and distal pancreatectomy plus enucleation was done in one patient (Table III).

In two patients, no tumor was found at surgery despite detailed exploration. In such a situation, intraoperative real-time sonography has been helpful in finding an adenoma,^{1,3,7} and in one study, detected a tumor in seven patients in whom the tumors were non-palpable at surgery.³ If this is not available or non-informative, a blind distal pancreatic resection to the level of the superior mesenteric vein has been recommended in the hope of excising a previously undetected adenoma.^{1,2}

One of the patients in this series in whom no tumor was found at surgery underwent 95% distal pancreatectomy with preservation of the spleen and was completely cured although pathological examination failed to find an islet-cell tumor or diffuse islet-cell hyperplasia, but the second patient who had a distal pancreatectomy to the level of the superior mesenteric vein continued to have attacks of hypoglycemia and received diazoxide therapy. Neither of these patients developed diabetes postoperatively, but were prescribed pancreatic extract for minor symptoms of indigestion.

Overall, our success rate was 88.9%. The pathology report was islet cell tumor in all seven patients in whom the tumor was found at surgery, and was negative in the two patients in whom no tumor was found. One of our patients had Werner's syndrome (MEN-I), with a pituitary adenoma and hyperparathyroidism. This patient had two adenomas at operation, one in the body and the second in the tail of the pancreas, and was treated by distal pancreatectomy and cured.

DISCUSSION

Endocrine tumors of the pancreas are rare, with an annual incidence of 5 per 1 million population. However, their prevalence in unselected autopsies approximates 1 per 100.¹

Functional endocrine tumors of the pancreas are classified according to the major hormone produced by the tumor, and consist of insulinoma, gastrinoma (Zollinger-Ellison syndrome), vipoma (Verner-Morrison syndrome), glucagonoma, somatostatinoma and others (Table IV).

Insulinoma is the most common endocrine tumor of the pancreas,¹ and the first recognition of the insulinoma syndrome is accredited to Whipple and associates.⁸ Insulinoma is associated with Whipple's triad, which con-

sists of 1) attacks of hypoglycemia precipitated by fasting or exertion, 2) blood sugar levels less than 50 mg/dl, and 3) relief of symptoms following oral or intravenous administration of glucose.

Insulin is normally secreted by beta cells of the pancreatic islets in response to elevated blood glucose levels. Insulinomas secrete insulin autonomously even in the presence of low blood glucose levels, causing spontaneous hypoglycemia and characteristic clinical symptoms. These symptoms can be divided into two groups as follows:

1. If the blood sugar falls rapidly, the main symptoms will be related to the release of catecholamines such as epinephrine due to hypoglycemia, resulting in sweating, hunger, weakness, tachycardia, tremor, and irritability.

2. If the decrease in blood sugar is more gradual, "neuroglycopenic" symptoms such as headache, mental confusion, visual disturbances, obtundation, convulsions and coma may occur, due to inadequate glucose for metabolism by the brain.

Patients gradually learn that attacks may be prevented by consuming large amounts of carbohydrates, and many eventually become obese.²

In regard to diagnosis, aside from fulfilling the criteria of Whipple's triad, valuable information may be acquired by simultaneous serum insulin and glucose level measurement, with an inappropriately elevated insulin level with respect to serum glucose. An insulin/glucose ratio of greater than 0.4 has also been noted.¹ The most reliable method for diagnosis has been the performance of a 72-hr fast with monitoring of blood insulin and glucose levels every 4-6 hrs and particularly when symptoms develop. However, this has rarely been necessary nowadays.

After the diagnosis has been made, preoperative studies for localization of the offending lesion(s) have been recommended. These have consisted of sonography, CT scan, selective visceral arteriography, and more recently, percutaneous transhepatic portal vein sampling which has been shown to be safe and reliable and up to 100% accurate.

All patients should undergo exploratory laparotomy with the intent of excision of the lesion and cure of the patient. Even patients with advanced malignant disease and hepatic metastases may benefit from palliative tumor debulking and resection of metastases.^{1,2,14} For patients with residual tumor who despite frequent feeding develop hypoglycemic symptoms, medical treatment with diazoxide which directly inhibits the release of insulin from beta cells can be beneficial.^{1,2} The role of adjuvant chemotherapy or hormonal therapy has also been shown to be beneficial,^{1,2} and streptozotocin and octreotide have been tested clinically in this regard.

For simple benign adenomas, simple enucleation is appropriate as stated previously, but for deeply situated

lesions, resection of pancreas harboring the lesion is usually necessary. For lesions in the body and tail, distal pancreatectomy with preservation of the spleen as pointed out earlier is the procedure of choice. Lesions located deeply in the head and uncinate process may require a pylorus-preserving pancreaticoduodenectomy for cure.

For the situation in which no tumor is found at surgery, we recommend a 95% pancreatic resection with splenic preservation. Recently, intraoperative real-time ultrasound has been shown to significantly locate unpalpable tumors, and is emerging as a valuable tool in difficult operations for islet-cell tumors.

In this study, despite the unavailability of new techniques such as transhepatic portal vein sampling and intraoperative ultrasound, we had a success rate of 88.9% and only one failure using the operative technique outlined before. None of our patients developed diabetes and all, except one patient who continues to have attacks of hypoglycemia, are well on follow-up of up to nine years. Furthermore, our complication rate of 11.1% (one patient who developed a pseudocyst postoperatively which resolved spontaneously) and 0% mortality compares favorably with that of the world literature (31.5% complication rate, 6.4% requiring reoperation, and 2% mortality).¹¹

REFERENCES

1. Yeo CJ, Cameron JL: The Pancreas. In: Sabiston DC, (ed.). Textbook of Surgery. The Biological Basis of Modern Surgical Practice. 14th ed, Philadelphia, W.B. Saunders Co., pp. 1098-9, 1991.
2. Silen W, Steer ML: Pancreas. In: Schwartz SI, Shires GT, Spencer FC, (eds.). Principles of Surgery. 5th ed, New York, McGraw-Hill, pp. 1134-6, 1989.
3. Doherty GM, Doppman JL, Shawker TH, et al: Results of a prospective strategy to diagnose, localize and resect insulinomas. *Surgery* 110(6): 989-96, 1991.
4. Bottger TC, Weber W, Beyer J, Junginger T: Value of tumor localization in patients with insulinoma. *World J Surg* 14(1): 107-12, 1990.
5. Doppman JL, Shawker TH, Miller DL: Localization of islet-cell tumors. *Gastroenterol Clin North Am* 18(4): 793-804, 1989.
6. Fojans SS, Vinik AI: Insulin-producing islet-cell tumors. *Endocrinol-Metab Clin North Am* 18(1): 45-74, 1989.
7. Galiber AK, Reading CC, Charboneau JW, Sheedy PF, et al: Localization of pancreatic insulinoma: comparison of preoperative and intraoperative ultrasound with CT and angiography. *Radiology* 166(2): 405-8, 1988.
8. Whipple AO, Frantz VK: Adenoma of islet-cells with hyperinsulinism. A review. *Ann Surg* 101: 1299, 1935.
9. Norton JA, Shawker TH, Doppman JL, et al: Localization and surgical treatment of occult insulinomas. *Ann Surg* 212(5): 615-20, 1990.
10. Vinik AI, Delbridge L, Moattari R, Cho K, Thompson N: Transhepatic portal vein catheterization for localization of insulinomas: a ten-year experience. *Surgery* 109(1): 1-11, 1991.
11. Pasiaka JL, McLeod MK, Thompson NW, Burney RE: Surgical approach to insulinomas. Assessing the need for preoperative localization. *Arch Surg* 127(4): 442-7, 1992.
12. Demeure MJ, Klonoff DC, Karam JH, Duh QY, Clark OH: Insulinomas associated with multiple endocrine neoplasia type I: the need for a different surgical approach. *Surgery* 110(6): 998-1004, 1991.
13. Service FJ, McMahon MM, O'Brien PC, Ballard DJ: Functioning insulinoma-incidence, recurrence, and long-term survival of patients: a 60-year study. *Mayo Clin Proc* 66(7): 711-19, 1991.
14. Rusher AH, Henson K: Metastatic malignant insulinoma: debulking for palliation of symptoms. *J Ark Med Soc* 88(6): 267-9, 1991.