

## INTRODUCTION OF A NEW MODIFIED EYEBROW AND EAR RECONSTRUCTION PROCEDURE

MEHDI DEYLAMIPOUR\*, M.D., AHMAD HOOMAND,\*\*M.D., AND  
NOOR AHMAD LATIFI,‡ M.D.

*From the Department of Plastic and Reconstructive Surgery, Hazrat Fatemeh Training and Treatment  
University Hospital, Iran University of Medical Sciences, Tehran, Islamic Republic of Iran.*

### ABSTRACT

This paper presents a new modified technique for ear and eyebrow reconstruction which was used to reconstruct facial injuries caused by burns, excision of malignant tumors, depressed traumatic scars and a low hairline defect around the auricular region.<sup>1</sup> Other facial reconstructions carried out by this procedure were also highly successful and without complications.

*MJIRI, Vol. 9, No. 2, 127-130, 1995.*

### INTRODUCTION

This new technique which consists of the posteroanterior pedicled fascia island flap<sup>2</sup> is principally applied to prevent hair loss especially in eyebrow reconstruction, for postoperative complications, and in order to reduce failure rates.

### MATERIAL AND METHODS

As the scalp island flap reconstruction method involves a high failure rate, attempts were made to use the modified normal approach of reconstruction which consists of a free graft, pedicled and the simple island flap, to reconstruct the injured eyebrow and the ear. Although the success attained by this procedure is high, it is likely to have a certain percent of failure as well.

### Eyebrow reconstruction by the modified procedure

The eyebrow reconstructed by the modified island flap technique consists of the posteroanterior pedicle fascia island flap which is created to reach the temporoparietal fascia and to distinguish the arterial direction of the lateral flap while subdissecting the pedicle in the superior auricular region (Fig.1, A). Then in order to facilitate flap rotation the posterior end of the designed eyebrow flap (Fig.2,A) is

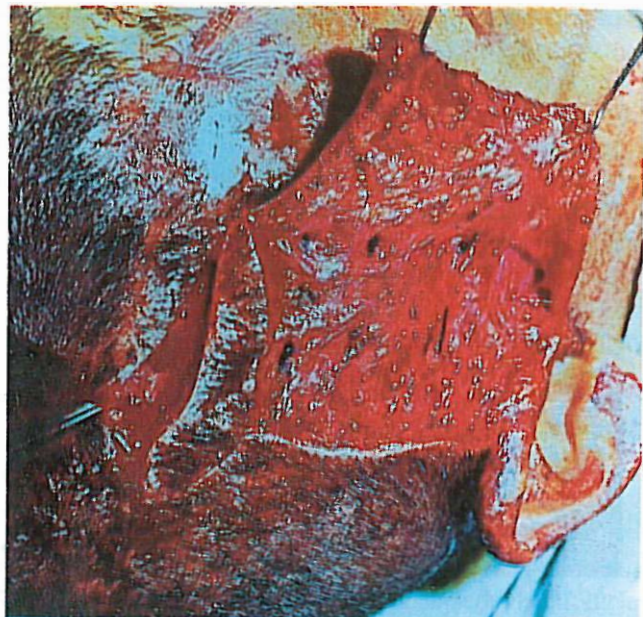


Fig. 1, A. Posteroanterior pedicle fascia island flap.

\* Assistant professor and faculty member of plastic and reconstructive surgery;

\*\* Associate professor and faculty member of plastic and reconstructive surgery; clinical and educational assistant;

‡ Assistant professor and faculty member of plastic and reconstructive surgery, Iran University of Medical Sciences, Hazrat Fatemeh Training and Treatment University Hospital, Tehran, Islamic Republic of Iran.

## Modified Eyebrow and Ear Reconstruction

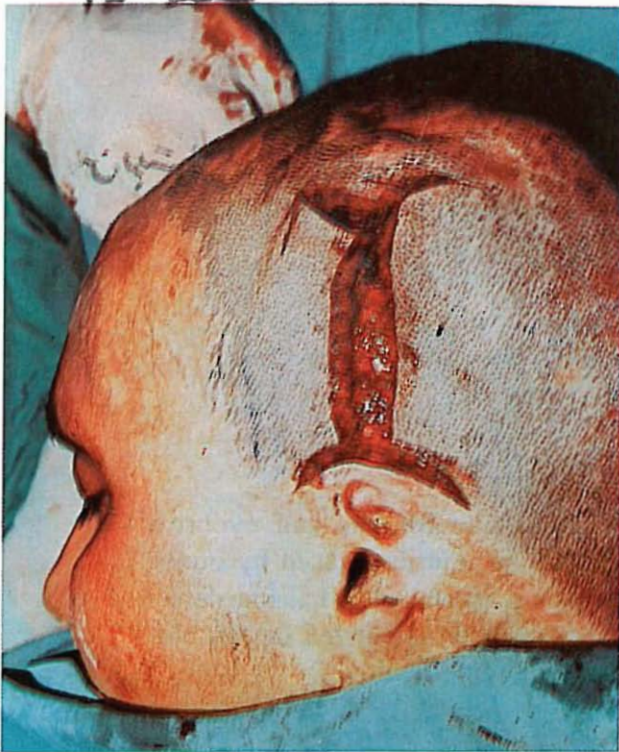

Fig. 1. B. Skin incision around the auricle.

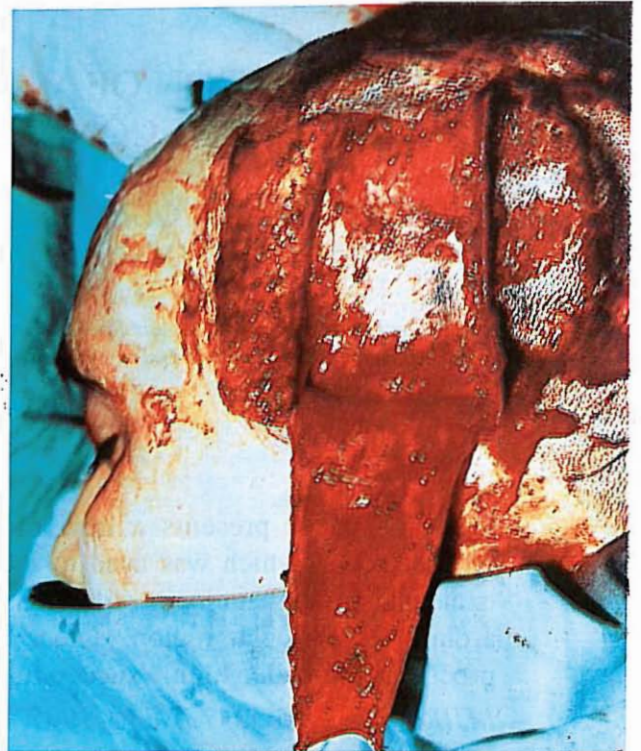

Fig. 2. B. Dissection and elevation of the temporoparietal fascia from the deep fascia situated in the temporal region.

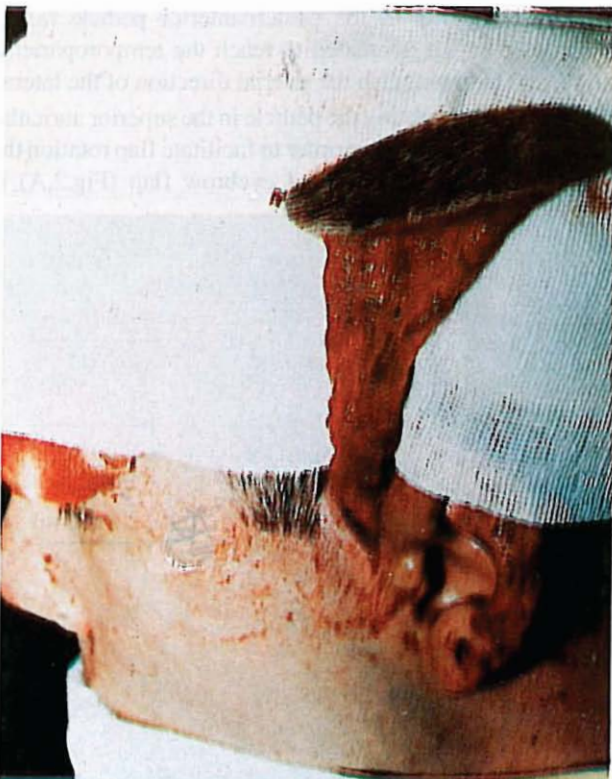

Fig. 2. A. Elevated island flap with vascular pedicle.

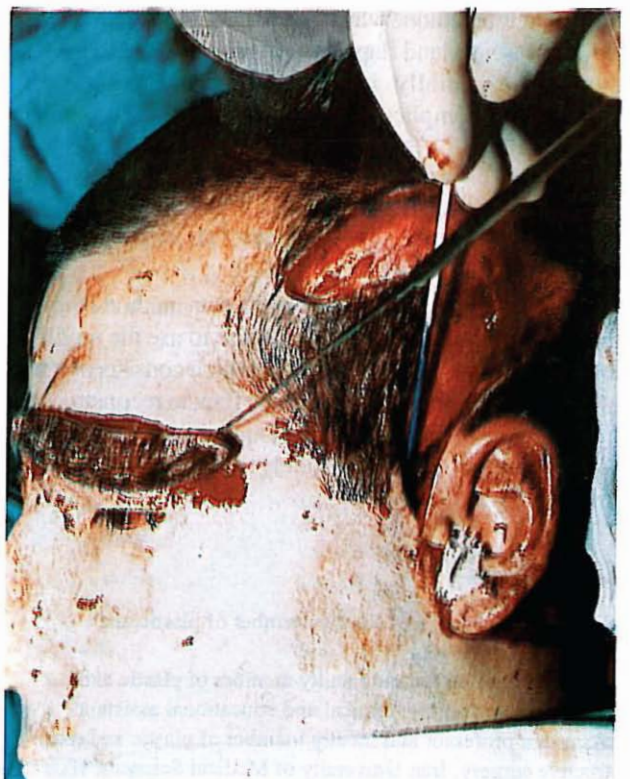

Fig. 3. A. Eyebrow island flap is placed in the recipient area.

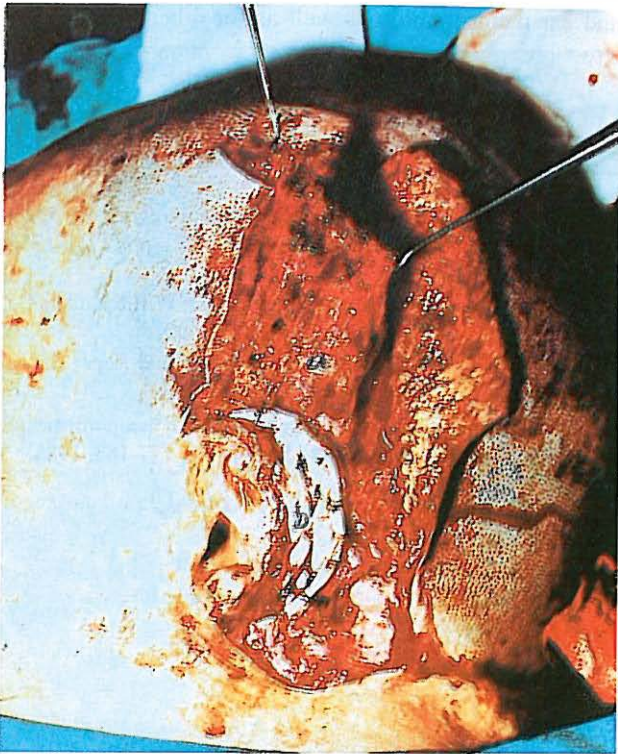

Fig. 3, B. Placing the temporoparietal fascia over the presculpted rib cartilage framework.

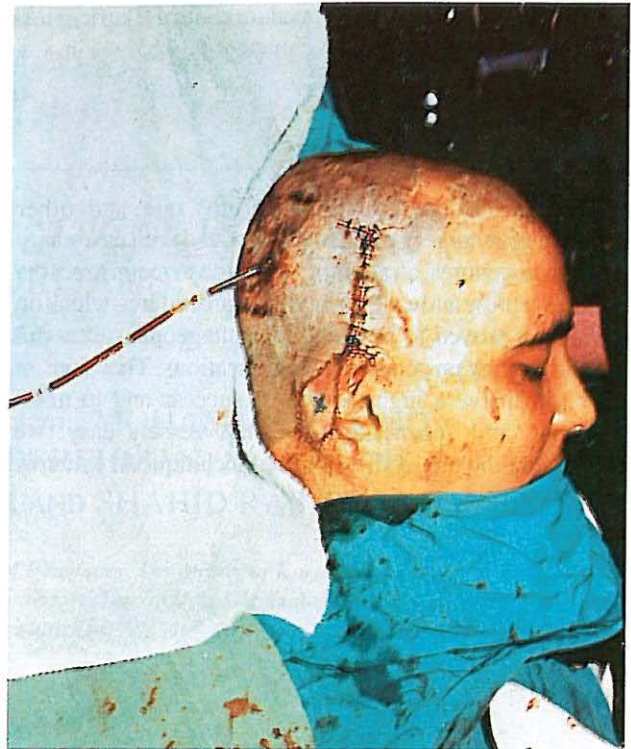

Fig.4,B. Postoperative result: free skin graft over the temporoparietal fascia.

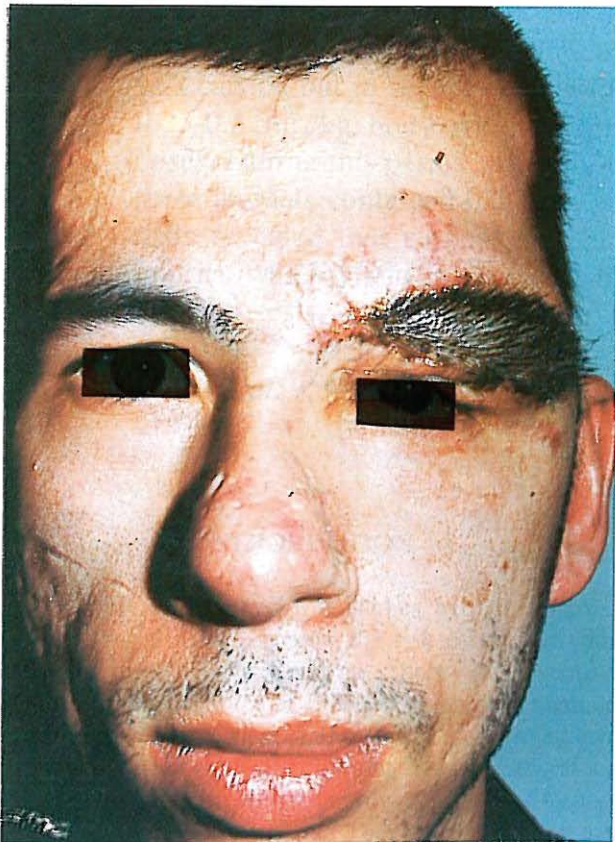

Fig. 4, A. Postoperative result.

placed inside the inner middle region of the eyebrow and its anterior end inside the superior external lateral region (Fig.3,A). As a result the direction of the flap hair growth attained by this procedure is directed upward and outward, similar to the hair direction of a normal eyebrow (Fig.3,A). The postoperative eyebrow flap is illustrated in Fig.4.A.

#### One stage ear reconstruction by the modified procedure

The temporoparietal fascial flap is used to reconstruct the injured ear. It is also used to treat cases of ear defect around the auricle.<sup>4</sup> To reconstruct the ear a skin incision is made and the subfollicle is dissected. This releases the superficial temporoparietal fascia from the deep fascia situated in the temporal region (Fig. 1,B), and is used as the presculpted rib cartilage auricle framework hinge (Fig.2,B). After inserting it in the sculpted cartilage framework it is covered by a free skin graft. The procedure is illustrated by X in Figs. 3,B and 4,B. The external auricle in the final stage is completed by raising the ear and placing the skin graft behind it.

#### RESULTS

In comparison to the customary surgical failures, dissection and specification of the subcutaneous hair follicle vessel is made easy by the island flap technique. Concerning

## Modified Eyebrow and Ear Reconstruction

eyebrow reconstruction, the procedure controls flap hair loss which in turn prevents the development of a bare skin.

and ear reconstruction as well as for other facial reconstructions.

### DISCUSSION

Having observed the high failure rate and other reconstructive surgery problems associated with customary surgical procedures, an attempt was made to reconstruct the injured eyebrow and ear by a modified procedure— which on application proved to be highly advantageous, successful and without any postoperative complications. Therefore, in order to achieve a high percent of success and to make dissection and specification of flap vessels easy, we recommend the use of the modified technique in eyebrow

### REFERENCES

1. Converse JM, et al: *Reconstructive Plastic Surgery*, Vol. 3, 2nd edition, Philadelphia: W.B. Saunders Co., pp. 1745-1750, 1977.
2. McCarthy JG: *Plastic Surgery*. Philadelphia: W.B.Saunders Co, Vol. 3, pp. 2101-3, Vol.4, pp. 3068-9, 1990.
3. Herbert DC: Nasolabial subcutaneous pedicle flaps. *British Journal of Plastic Surgery* 28:90-94, 1975.
4. McCarthy JG, et al: Print experience with temporoparietal fascia. *Plastic Reconstructive Surgery* 76: 177-183, 1985.