

THERAPEUTIC EVALUATION OF INTRALESIONAL INJECTION OF BLEOMYCIN SULFATE IN THE TREATMENT OF RESISTANT WARTS

JAVAD GOLCHAI, M.D., AND MOHAMMAD MEHDI
MOBARHAN VAGHE KAREGAR, M.D.

From the Department of Dermatology, Razi Hospital, Rasht, Islamic Republic of Iran.

ABSTRACT

From June 1992 to March 1993, a group of patients suffering from different types of warts were treated with intralesional injections of bleomycin sulfate.

This study reviews the literature concerning this modality of treatment and the pathophysiology and immunohistopathology of warts and options for treatment.

In this prospective study, a combination of a 1mg/mL solution of bleomycin in distilled water and lidocaine 2% (in equal portions) was injected in 22 patients. No patient received more than 2mL of the solution.

Eighty-four of 95 warts (88.4%) showed complete resolution after 1-3 bleomycin injections, while 10 warts (10.5%) showed incomplete resolution. In only one plantar wart did bleomycin fail to elicit any therapeutic response (1.1%). The cure rate was 96.3% for periungual warts, 84.6% for palmoplantar warts, and 75% for warts located on the extremities. The responsive warts developed a hemorrhagic eschar that healed without scarring. No systemic side-effects were observed but a mild transient pigmentary change was seen at the injection site of one palmar wart.

It is concluded that this form of treatment for resistant warts is safe, reliable and well accepted by the patients if used in the dose mentioned.

MJIRI, Vol. 8, No. 4, 233-236, 1995.

Key Words: Resistant warts; Bleomycin sulfate

INTRODUCTION

Intralesional injection of bleomycin is used for the treatment of severe types of warts. The bleomycins are a group of water-soluble glycopeptides extracted from a strain of *Streptomyces verticellus*, with anti-bacterial, antiviral, and cytotoxic activity.^{1,2,3,4,5,6} Intralesional bleomycin has been reported to be a promising ap-

proach in the effective treatment of resistant warts, with cure rates from 63% to 100%.⁶

The mechanism of action of bleomycin in the treatment of warts is not clear. Bleomycin has been observed to inhibit the replication of viruses, mammalian cells, and a broad range of tumor cells.^{2,3} Bleomycin treatment of sensitive cells *in vitro* has resulted in degradation of preformed DNA and inhibition of DNA synthesis.¹ The cytotoxic and virucidal effects of this drug and the microhemorrhages seen in the injected warts have been mentioned previously by many authors.^{1,2,3}

Correspondence: J. Golchai, M.D., Department of Dermatology, Razi Hospital, Rasht, Islamic Republic of Iran.

Intralesional Bleomycin for Warts

The side effects of intralesional bleomycin in the treatment of warts are rare but may include moderate to severe pain after injection, onychodystrophy, Raynaud's phenomenon, pigmentary changes and local urticaria at the site of injection, or, rarely, cyanosis and gangrene of the treated finger.^{1,2,4,5}

PATIENTS AND METHODS

A total of 22 patients (15 women and 7 men) between 14-45 years of age were treated and followed-up. Most of the patients had experienced their warts for more than 6 months and had been refractory to chemical destruction and electrocautery.

Age, sex, duration of lesions, previous treatment and recurrences (or refractoriness), and objective signs (type, location, and size of each wart) were recorded for each patient.

Bleomycin sulfate was provided by Nippon-Kayaku Co. (Japan) and supplied in the form of vials. Each vial of Bleo-S contained 15 mg of active bleomycin sulfate, which was dissolved in 7.5 mL of distilled water and then added to 7.5 mL of lidocaine 2% (to minimize procedural discomfort) to form a 1mg/mL solution of Bleo-S.^{5,6,7}

A dose of 0.1mL of this solution was injected into warts greater than 10mm, while larger lesions required more drug for injection. Blanching of the wart surface indicated proper injection into the wart tissue. The total volume of injection in each course of treatment (and in each wart) was limited to one mL. The solution was injected intralesionally with disposable syringes fitted with a 30-gauge needle. Patients returned 2 weeks after the initial injection, and persistent warts were injected with the same solution for a second (and rarely a third) time. Therapy was considered a failure and discontinued if warts persisted after 2-3 injections.

Final assessment was made 8 weeks after the first injection, and results were documented and photographed.

RESULTS

From 95 resistant warts treated with bleomycin sulfate, 84 showed complete resolution after 1-3 injections, with an overall cure rate of 88.4%. In addition, 10 of the bleomycin-injected warts showed incomplete resolution (10.5%), and resistance to treatment was seen in only one plantar wart (1.1%).

The therapeutic response according to the location of the wart was 96.3% for periungual warts (52 of 54 warts showed complete cure). In palmoplantar warts, 11

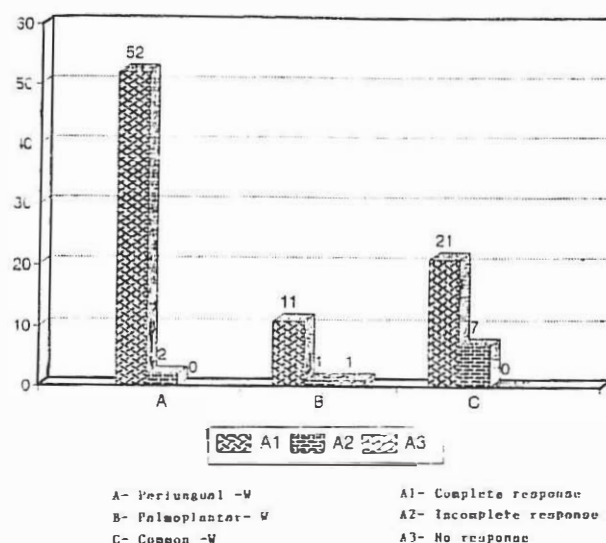


Fig. 1. The therapeutic response according to the type of warts.




Fig. 2. The relationship between various warts and sessions of injection.

of 13 showed complete resolution (84.6%). The cure rate of warts located on the hands and feet was 75% (21 of 28 warts showed complete resolution) (Fig.1). It was noted that of 84 cured warts, 67 were completely cured after only one injection (76.8%), and the remainder (17) resolved after the second or third injection (Fig.2).

All of the 31 warts which had existed for 6-12 months were completely cured (100%). 11 of 12 warts with a duration of less than 6 months (91.7%) and 42 of 52 warts with a duration of more than 12 months (80.8%) showed complete resolution (Fig. 3). Of 14 warts less than 5 mm in diameter, 10 (71.4%) were completely cured. From 67 warts between 5-10 mm in

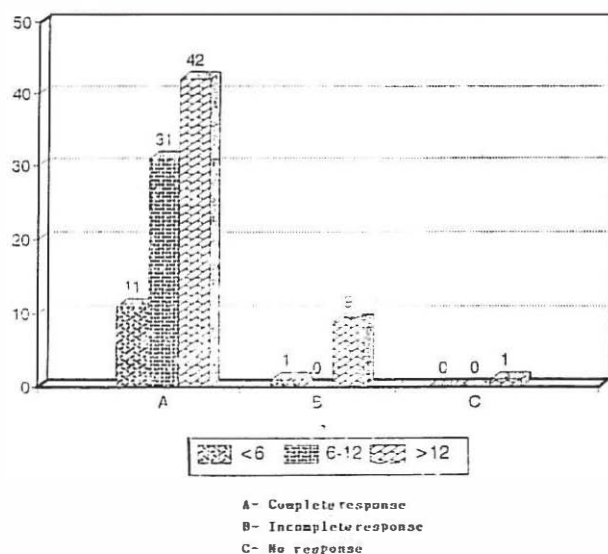


Fig. 3. The relation between duration and therapeutic response.

diameter, 63 warts (94%) and from 14 warts more than 10 mm in diameter, 11 completely disappeared (78.6%) (Figs. 4-5).

A considerable number of patients experienced pain during the injection but this discomfort disappeared within 15-30 seconds (efficacy of lidocaine). Injection pain was transient in 45.3% of warts (resolving spontaneously within 1-2 days), but was quite severe in 4 warts.

The bleomycin injection site usually developed erythema on the day after injection, then blackened and became thrombotic (90.4% of warts showed this in 1-3 days and 9.6% in 4-7 days after injection. An eschar was evident by the first week and separation of the black eschar occurred 10-14 days later, which resulted in complete healing without scarring.

DISCUSSION

Warts are rarely a serious problem, except in instances of treatment failure and/or recurrences. Intralesional Bleo-S has been reported to be effective in the treatment of recalcitrant warts in adults.¹

In 1977, Olsen reported resolution of plantar warts in 18 of 25 patients (72%) treated with bleomycin sulfate and 5 of 21 patients (24%) treated with placebo.⁸ Shumack and Haddock obtained a cure rate of 99.23% after 1-3 injections in patients who received 2 units of bleomycin at 5-day intervals for 20 days after the initial administration.⁹ Cordero et al. (1980) reported a cure rate of 67% in plantar warts, 82% in periungual warts, and 80% in warts located elsewhere.³ Amer et al. in

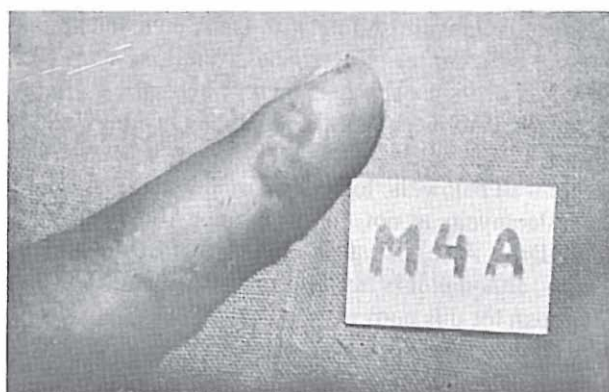


Fig. 4. Patient with wart before treatment.

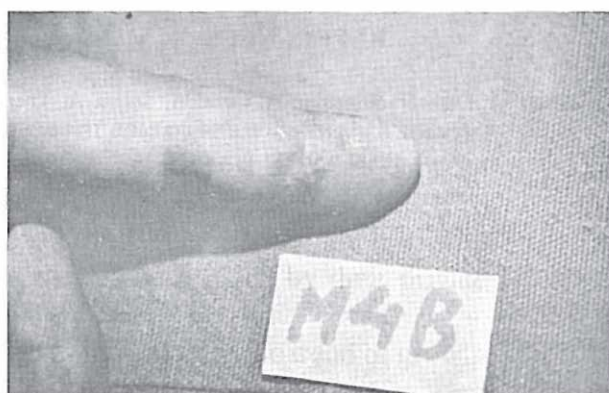

Fig. 5. The same patient after three injections of bleomycin sulfate.

1988 found that intralesional bleomycin injection is a satisfactory regimen for resistant warts, especially periungual warts and warts located on the hands and feet. They reported an overall cure rate of 67.8% for all types of warts (77% for warts on the hands and feet, 71.4% for periungual warts, and 47.6% for plantar warts) while only 2.9% of their placebo injected warts resolved.¹ On the other hand, intralesional bleomycin with lidocaine 1% appears to be a relatively painless form of therapy for recalcitrant verrucae.^{6,7} Mizuno and Ishida (1982) suggested that the addition of lidocaine may actually enhance the cytotoxicity of bleomycin.⁷

In this study, Bleo-S was found to be most effective for periungual warts and less so for planter warts and finally for warts on the hands and feet. Blanching of the warts is critical to ensure proper injection.

No adverse local or systemic reactions were noted in the group of patients treated with Bleo-S plus lidocaine 2% and distilled water. However, patients should be informed of local tenderness or pain at the treated site 1-10 days after injection.

There is the theoretic possibility that the interfer-

ence of bleomycin sulfate with DNA metabolism might induce skin cancer. Nevertheless, the long-term consequences of its use are unknown.^{8,9} It is also noteworthy that all trials with intralesional bleomycin were performed with injections of very small amounts which were well below the lowest reported toxic dose.^{1,9}

Bleomycin is not currently approved by the Food and Drug Administration (FDA) for the treatment of warts, although it is licensed in Canada and widely used in Japan for this purpose.⁶

In conclusion, this study recommends the use of intra-lesional Bleo-S in the treatment of periungual, plantar, and common warts whenever other treatment modalities fail.

REFERENCES

- 1- Amer M, Diab N, Ramadan A, Galal A, Salem A: Therapeutic evaluation for intralesional injection of bleomycin sulfate in 143 resistant warts. *J Am Acad Dermatol* 18 (6): 1313-6, 1988.
- 2- Bunney MH, Nolan MW, Buxton PK, Going SM, Prescott RJ: The treatment of resistant warts with intralesional bleomycin: a controlled clinical trial. *Br J Dermatol* 111: 197-207, 1984.
- 3- Cordero AA, Guglielmi HA, Woscoff A: The common wart: intralesional treatment with bleomycin sulfate. *Cutis* 26 (3): 319-324, 1980.
- 4- Epstein E: Intralesional bleomycin and Raynaud's phenomenon. *J Am Acad Dermatol* 24: 785-6, 1991.
- 5- Hayes ME, O'Keefe EJ: Reduced dose of bleomycin in the treatment of recalcitrant warts. *J Am Acad Dermatol* 15: 1002-6, 1986.
- 6- Manz LA, Pelachyck JM: Bleomycin-lidocaine mixture reduces pain of intralesional injection in the treatment of recalcitrant verrucae. *J Am Acad Dermatol* 25 (3): 524-6, 1991.
- 7- Mizuno S, Ishida A: Selective enhancement of bleomycin cytotoxicity by local anesthesia. *Biochem Biophys Res Commun* 105: 425-31, 1982.
- 8- Olsen RL: Plantar warts yield to DNA inhibitor. *JAMA* 237: 940-1, 1977.
- 9- Shumack PH, Haddock MJ: Bleomycin: an effective treatment for warts. *Aust J Dermatol* 20: 412, 1979.