

CARCINOMA OF THE ESOPHAGUS IN A FOURTEEN YEAR OLD BOY

MANOOOCHEHR M. LARI, M.D., F.A.C.P.,
AHMAD KHOSSRAVY, M.D., AND TAGHI GHIASSI, M.D.*

*From the Departments of Medicine and *Pathology, Mashhad University of Medical Sciences,
Mashhad, Islamic Republic of Iran*

ABSTRACT

This is the first documented case of esophageal carcinoma in a 14 year old boy which has been reported to date. Carcinoma of the esophagus is rare before the third decade. The present case highlights the fact that the condition should be kept in mind in the differential diagnosis of progressive dysphagia even in children and teenagers.

Keywords: Esophageal carcinoma, Epidemiology, Dysphagia, Teen-age.

MJIRI, Vol. 8, No. 4, 277-280, 1995.

INTRODUCTION

Cancer of the alimentary tract in children and teenagers is a rare occurrence. It accounts for not more than 5 percent of all pediatric neoplasms.¹ Moreover, primary esophageal malignancies in children are extremely rare. In 1958, Moore² reviewed the literature on squamous cell carcinoma in children, and found only one case of primary carcinoma in a 14 year old boy in the 48 cases he selected. In Peller's survey over a five-year period,³ only 0.6 percent of annual deaths from esophageal malignancies occurred in the below 14 age group in the United States, while in a comparable series in England there were no deaths from this cause in the same period of time, from 1952 to 1956. In the majority of textbooks on tumors and carcinoma in children, no mention is made of esophageal carcinoma. Willis stated that the affection was rare,⁴ and that he knew of no recorded case of esophageal carcinoma in children. Similarly, Dargeon made no reference to esophageal carcinoma in his book on childhood tumors.⁵ In a large series of esophageal carcinoma, the youngest age groups mentioned were 20 to 30 years for males and 18 to 20 years

for females.⁶ The latest case reported was an eight year old child from India.⁷

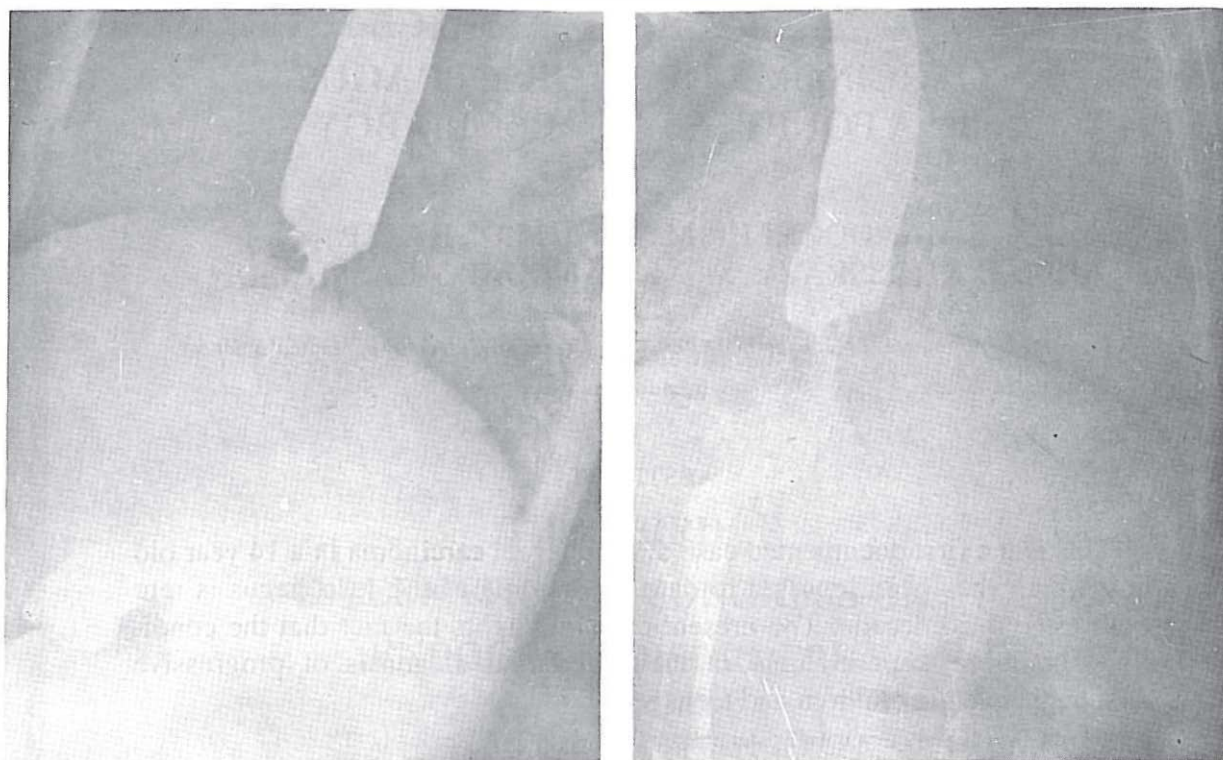
In this paper a case of esophageal carcinoma in a fourteen year old boy is presented. The Caspian Littoral, the Asian esophageal cancer belt and the etiological aspects of esophageal cancer will also be briefly reviewed.

CASE REPORT

A fourteen year old Afghan boy was admitted to the Medical Department of Ghaem Hospital for progressive dysphagia of 3 months' duration. Physical examination revealed a poorly nourished, thinly built male with evidence of marked anemia and mild dehydration. ENT examination was normal. Barium swallow, however, revealed a lower esophageal narrowing with complete hold-up of barium and proximal dilatation (Fig. 1). Chest x-ray showed no evidence of metastases. Esophagoscopy disclosed an exophytic, red, highly vascular, fragile mass almost completely occluding the lumen of the lower esophagus. Biopsy was performed and histopathological examination revealed a well-differentiated squamous cell carcinoma. After reanimation, the patient was referred for surgery.

M.M. Lari, M.D., F.A.C.P., Professor of Medicine,
A. Khosravy, M.D., Assistant Professor of Medicine,
T. Ghiassi, M.D., Asst. Professor of Pathology, Ghaem Hospital,
Mashhad Univ. of Medical Sciences, Mashhad, Islamic Repub. of Iran

Carcinoma of Esophagus in a 14 year-old



Figs. 1,2. Severe stricture with irregularity at the lower esophagus.

DISCUSSION

Incidence rates for carcinoma of the esophagus vary markedly depending on geographical area and may differ even within contiguous regions.⁸ The highest figures have been recorded in the eastern part of the Iranian province of Mazandaran⁹ (up to 110 per 100,000 in males and 184 per 100,000 in females), and the southern Soviet Republics of Kazakhestan and Turkmenia.¹⁰ High rates have also been recorded in Kenya,¹¹ parts of India¹² and Ceylon,¹³ among the Bantu of Africa,¹⁴ and in Puerto Rico.¹⁵ In the United States, high rates for males are found primarily in the urban areas of the northeast and the midwestern region of the Great Lakes. Incidence per 100,000 of the population in the United States is 3.1.

It appears that the Caspian Littoral represents merely one part of an enormous area with high incidence rates of esophageal cancer, referring to the Asian esophageal cancer belt which comprises parts of Iran, Afghanistan, Russia, Central Asia, Siberia, Mongolia, and north and west China. Ethnic variations in the incidence of esophageal carcinoma are not decisive in the Asian cancer belt. For example, esophageal carcinoma is common not only among the Turkoman tribes but also in the Uzbeks, Kara-Kalpaks, Kazakhs and

Uighurs. In southern Africa, an interesting difference in incidence has been reported among African and Indian males in Durban.¹⁶ Further north it has been noted that the high-incidence Kenyan shore of Lake Victoria is largely populated by the Luo Tribe. But isolated observations of this kind require more detailed analyses before ethnic factors can be reasonably implicated. Similar reservations apply to the familial patterns of esophageal cancer that have been described in the high incidence zones of Kazakhestan. There is no positive evidence of genetic susceptibility here and common exposure to extraneous carcinogens seems more feasible in Europe. An association between tylosis (an abnormal thickening of the palms and soles, inherited as a dominant characteristic) and esophageal cancer was proposed by Howell-Evan.¹⁷ The nature of this association is difficult to evaluate at the present time. Other disorders associated with esophageal carcinoma are chronic atrophic gastritis, pernicious anemia, immunodeficiency, familial polyposis, and intestinal metaplasia of the stomach which has been suggested but is difficult to evaluate at the present time.

Both tobacco and alcohol have been implicated as important factors in the development of esophageal cancer in several parts of the world.¹⁸ Excessive exposure to both is common in the same individual, and the rela-

tive importance of each is difficult to appraise. There are, however, situations where a correlation between esophageal cancer, alcohol and tobacco cannot be sustained. No alcohol is consumed by men or women in the high incidence zone of the eastern Caspian Littoral, and it is probable that most Bantu women in the Transkei drink and smoke little, if at all, despite the fact that their incidence of esophageal carcinoma is equal to, and may sometimes even exceed that found in Bantu males from the same area. Furthermore, alcohol consumption among male Bantus has probably been heavy for many years whereas their increased incidence of esophageal cancer is only recent.

In France, there is a high degree of alcoholism in certain western and eastern parts of the country. Mortality from esophageal cancer is increased in Brittany but not in the eastern localities of Savoy. It is important to note that in Brittany, the highest incidence is observed among the poorest segments of the population who drink home-brew. In countries such as Australia, alcoholism is common but cancer of the esophagus is rare.

An association between malnutrition and esophageal cancer is apparent in several parts of the world. Poor nutrition, low socio-economic status and a proclivity to develop esophageal carcinoma co-exist in industrialized societies in Europe and the United States as well as in non-industrialized parts of the world. In rural countries with a high incidence of esophageal cancer, natural environmental conditions may play an important role in determining the degree of malnutrition. The impoverished soil of the eastern Caspian Littoral and the Transkei provide obvious examples. Obviously the etiology of esophageal carcinoma in man is exceedingly complex. The present position has been aptly summed up by Kmet; "Esophageal cancer is no exception to the general rule that particular incidence patterns of a disease in a given population are the result of previous disease experience, environmental exposure, and immunogenetic predisposition modified by the conditions of the specific ecological setting."⁹

The factors commonly implicated in the pathogenesis of carcinoma of the esophagus such as alcoholism, post-radiation, chronic infection, tobacco, a history of lye burns or achalasia were not seen in our patient.

The clinical manifestations of esophageal carcinoma in children are similar to those in adults and include dysphagia, regurgitation, weight loss, chest pain, hematemesis, and occasionally a palpable mass. These symptoms are non-specific and may be indicative of other conditions in children, such as chronic retention of a foreign body in the esophagus, gastroesophageal reflux and its complications, achalasia, or post-corrosive strictures. The radiological finding of a hold-up of

barium with narrowing of the esophageal lumen is also found in other conditions. The important finding in the present case was an exophytic growth on esophagoscopy which is very unusual and rare. The biological behavior of malignant tumors of the esophagus in children or teenagers is similar to adults with frequent widespread metastatic disease commonly involving the liver, thorax, lymph nodes or lungs. In the present case the neoplasm apparently had no secondary deposits in the body.

The treatment of carcinoma of the esophagus includes radical surgery in the absence of metastatic disease and the use of radiotherapy and chemotherapy.

ACKNOWLEDGEMENT

We wish to thank Mrs. C. Taheri for her secretarial assistance.

REFERENCES

1. Landing BH, Martin LW: Adenocarcinoma and other unusual variants of esophageal cancer. *Pediatric Clinics of North America* 14: 223, 1959.
2. Moore C: Visceral squamous cancer in children. *Pediatrics* 21: 573, 1958.
3. Peller S: Cancer in Childhood and the Young. Bristol, John Wright and Sons Ltd., 111-115, 1960.
4. Willis RA: The Pathology of the Tumours of Children, 1st edition. Oliver and Boyd, Edinburgh and London, pp. 179-188, 1982.
5. Dargeon HW: Tumors of Childhood, 1st edition. Paul B. Hoeber, Inc. Medical Division of Harper and Brothers, N.Y., p. 191, 1987.
6. Case RAM, Pearson JT: Cancer death rates, age and sex. England and Wales (1911-1953). London Institute of Cancer Research, Royal Cancer Hospital, 1985.
7. Soni NK, Chatterji P: Carcinoma of the esophagus in an eight year old child. *J Laryngol Otol* 94: 327-329, 1980.
8. Higginson J and Muir CS: Epidemiology of cancer in Holland. In: Holland JF, Frei E III (eds), *Cancer Medicine*. Philadelphia, Lea and Febiger, 456-462, 1973.
9. Kmet J, Mahboubi E: Esophageal cancer in the Caspian Littoral of Iran, Initial studies. *Science* 175: 846-853, 1972.
10. Mahboubi E, Kmet J, Cook PJ, et al: Esophageal cancer studies in the Caspian Littoral of Iran. *The Caspian Cancer Registry, Br J Cancer* 28: 197-214, 1973.
11. Ahmed N, Cook P: The incidence of cancer of the oesophagus in west Kenya. *Br J Cancer* 23: 302-312, 1969.

Carcinoma of Esophagus in a 14 year-old

12. Sanghvi LD, Rao K, Khanalkar VR: Smoking and chewing of tobacco in relation to cancer of the upper alimentary tract. *Br J Cancer* 1: 1111-1114, 1955.
13. Stephen SJ, et al: Some observations on oesophageal carcinoma in Ceylon, including its relationship to betel chewing. *Br J Cancer* 24: 11-15, 1970.
14. Burrell RJW: Distribution maps of esophageal cancer among Bantu in Transkei. *J Natl Cancer Inst* 43: 877-888, 1969.
15. Martinez I: Cancer of esophagus in Puerto Rico: mortality and incidence analysis 1950-1961. *Cancer* 17: 1279-1288, 1964.
16. Scholand M, Bradshaw E: Cancer in the Natal African and Indian. *Int J Cancer* 3: 1964-1966, 1968.
17. Howell-Evan W, McConnel RB, et al: Carcinoma of the oesophagus with keratosis palmaris et plantaris (tylosis). *Quart J Med* 27: 413, 1958.
18. Hakulinen J, Lehtimäki L, et al: Cancer morbidity among two male cohorts with increased alcohol consumption in Finland. *J Nat Cancer Inst* 52: 6, 1974.

The contents appearing in
this publication are indexed by



For further information, please contact:
Dr. Munawar A. Anees, Editor-in-Chief, Periodica Islamica



BERITA PUBLISHING

22 Jalan Liku, 59100 Kuala Lumpur, Malaysia
Tel (+60-3)282-5286 Fax (+60-3)282-1605