

## Original Articles

### CAROTID BODY TUMORS OUR EXPERIENCE WITH 20 PATIENTS

MOHAMMADREZA KALANTAR MOTAMEDI, M. D., F. A. C. S.,  
AND MOHAMMADHASAN KALANTAR MOTAMEDI, M. D.\*



*From the Department of General and Vascular Surgery, Shohada Medical Center, Shahid Beheshti University of Medical Sciences, and the \*Department of Cardiovascular Surgery, Shahid Rajai Heart Hospital, Iran University of Medical Sciences, Tehran, Islamic Republic of Iran*

#### ABSTRACT

In this report of 20 patients with 24 carotid body tumors which is the largest series reported so far from Iran, we have evaluated the various characteristics of this relatively rare tumor in our population and compared our results with that of the literature.

Although the prevalence of the tumor is cited to be equal among both sexes, we found a female to male ratio of 2.3 to 1, as 14 of our patients were female and 6 were male. The tumor was as equally frequent on the right as it was on the left, and was bilateral in four cases. The average tumor size was 5.3 cm in diameter and was found to be malignant in four cases.

The results we obtained following the careful surgical technique which is described in detail compares quite favorably with that in the literature: 3 cases of cranial nerve injury (12.5%) compared to an average of 45% nerve injury in the reports, and no perioperative death versus 2% perioperative mortality in the literature. Also we had no instances of stroke, transient ischemia, Horner's syndrome, or other complications. We propose the surgical technique detailed by the author as the method of choice for treatment of carotid body tumors in Iranian patients.

*MJIRI, Vol. 8, No. 3, 141-147, 1994.*

#### INTRODUCTION

Carotid body tumor is a relatively rare tumor with slow but progressive growth. It often presents as a firm,

pulsatile mass in the neck at the carotid bifurcation deep to the sternocleidomastoid muscle. In this report, 20 patients, 14 female and 6 male, with 24 carotid body tumors who were operated on from 1986 to 1993 at the Department of General and Vascular Surgery, Shohada Medical Center, Shahid Beheshti University of Medical Sciences are presented.

The male to female ratio, median age of the patients, most common side of involvement, chief complaint,

M.R. Kalantar Motamed, M.D., FACS, Professor and Chief, Dept. of General and Vascular Surgery, Shohada Medical Center, Tajrish.

M.H. Kalantar Motamed, M.D., Assistant Professor of Surgery and Fellow of Cardiovascular Surgery, Shahid Rajai Heart Hospital, Tehran.

## Carotid Body Tumors

size of the tumors, family history and diagnostic evaluation are reviewed and compared with that of the literature, and the author's surgical technique for treatment of this tumor with minimal morbidity and complications is presented.

### MATERIAL AND METHOD

From 1986 to 1993, 20 patients (14 female and 6 male) with 24 carotid body tumors were diagnosed and operated on at the Shohada Medical Center. The majority presented with asymptomatic neck mass. The patient's ages ranged from 23 to 62 years, with a mean age of 49.5 years old. The clinical manifestations, diagnostic evaluation, treatment, surgical technique, tumor pathology and complications were evaluated and compared with the current literature.

### RESULTS

#### Clinical manifestations

Of the 20 patients in this study, 14 were female and 6 were male (female: male ratio 2:1). The mass was on the right side in 8 cases (40%), left sided in 8 cases (40%), and bilateral in four cases (20%) (Table I). The duration of symptoms ranged from three months to five years, with a mean of 26 months, depicting the delay involved until patient referral to the physician. The size of the tumor ranged from 2 cm to 15 cm in diameter, with a mean diameter of 5.1 cm (Table II).

The most common complaints consisted of (in decreasing order of frequency): neck mass (90%), headache (40%), dizziness (20%), syncope (20%), pain (15%), hoarseness (15%) and dysphagia (10%) (Table III).

#### Diagnosis

The definitive diagnosis of carotid body tumor is made by selective four-vessel cerebral arteriography, and diagnostic accuracy with this modality approaches 100%. In addition to diagnosis, arteriography aids in demonstrating abnormal tumor blood supply, presence of coexisting atherosclerotic disease of the carotid vessels requiring endarterectomy and planning the surgical approach to treatment.

Sonography (ultrasound) is another diagnostic modality which is safe, inexpensive, effective, and noninvasive and is considered the best method for screening in familial cases.

In cases where the above facilities are not available,

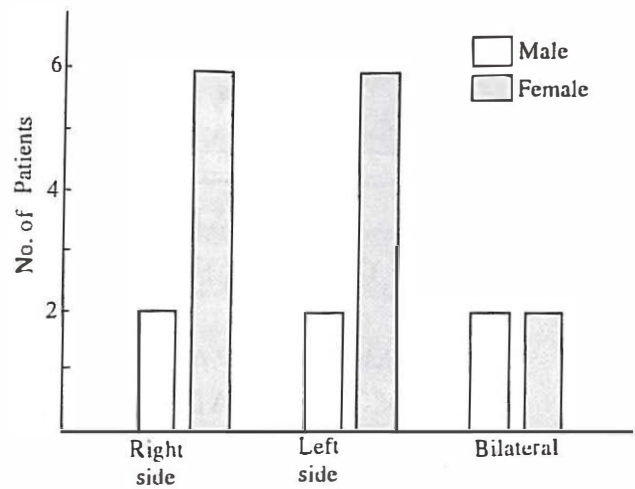


Table I. Sex distribution and laterality of tumor in 20 patients with carotid body tumor.

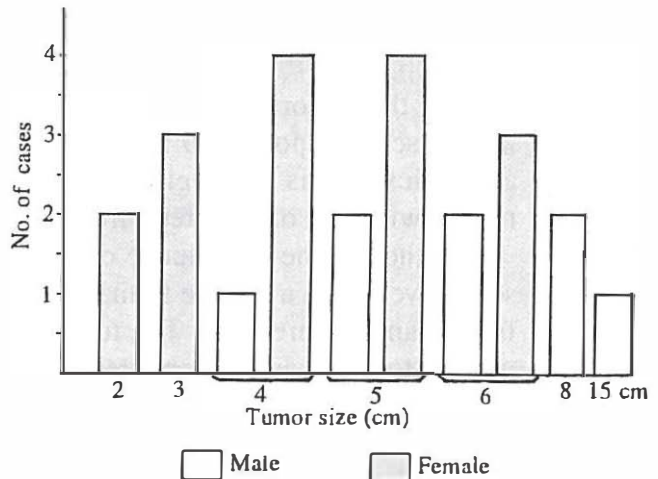


Table II. Tumor size distribution in the patients.

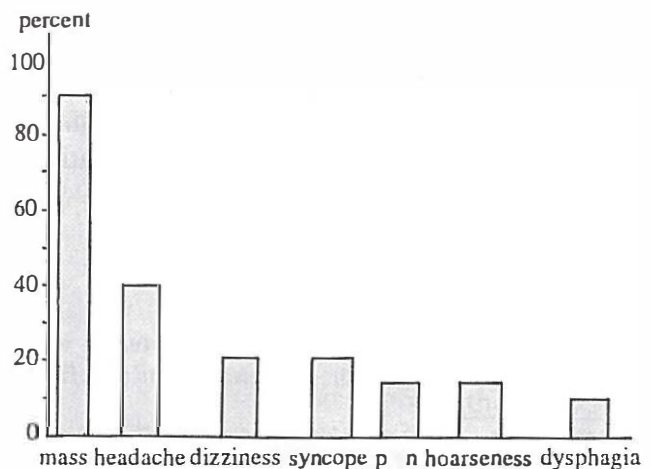


Table III. Symptoms of 20 patients with carotid body tumors.

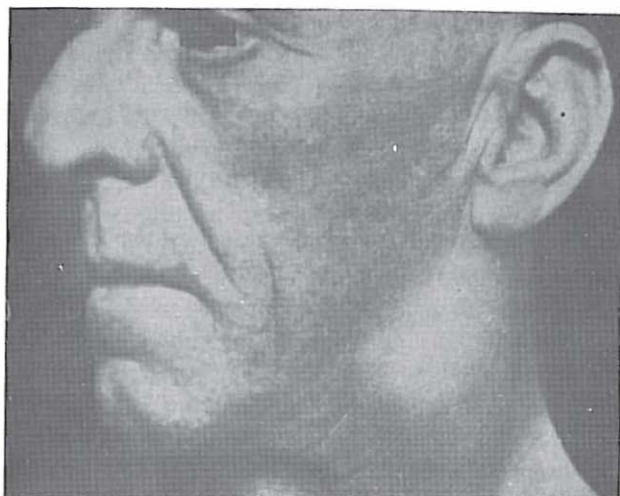


Fig. 1. Typical clinical appearance of carotid body tumor.

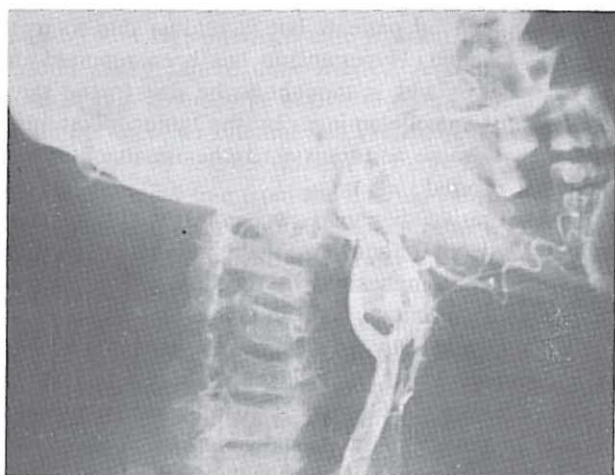


Fig. 2. Carotid arteriogram reveals typical widening of the bifurcation and tumor blush.

palpation of a rubbery, firm pulsatile mass at the carotid bifurcation deep to the sternocleidomastoid muscle or the presence of carotid body dysfunction may lead us to suspect the diagnosis of carotid body tumor. A bruit can be heard in about half the patients and the tumor is more mobile in the horizontal than vertical plane due to adherence to the underlying carotid artery (Fig.1).

Among the patients in our series, arteriography was performed in 15 patients (75%) and in all cases, the typical appearance of the tumor was characteristic (Fig.2). In the remaining cases, diagnosis was based on clinical findings as mentioned above.

### Treatment

The current treatment of carotid body tumor is mainly surgical, and the goal is to remove the tumor

completely without compromising carotid blood flow before excessive growth leads to compression symptoms on vital neck structures.

In cases in which the tumor is small, the tumor can usually be extirpated by careful ligation of the feeding vessels using the no-touch technique and taking care not to place clamps on the very fine and fragile feeding vessels. Alternatively, a more recent technique using bipolar cauterization to dissect the tumor off of the carotid vessels in the subadventitial plane may be used.<sup>1,17</sup> For large and very vascular tumors, tumor blood supply can be greatly diminished and resection facilitated by ligation of the external carotid artery just distal to the bifurcation, with en bloc tumor removal with a segment of external carotid artery, without any adverse effects for the patient. In cases in which the tumor is very large or invasive, sacrifice of the carotid artery may be necessary, or preoperative tumor embolization may be helpful (see Discussion).<sup>17</sup>

Of the 20 patients presented in this report, 12 cases (60%) underwent tumor resection with ligation of the external carotid artery (due to tumor size) and 8 patients (40%) had tumor resection without need for ligation. In two patients due to severe tumor adhesion and invasion of the underlying artery, the tumor was "shaved off" and the patients received post-operative radiotherapy.

### Tumor pathology

Carotid body tumors are mostly benign, but a malignancy rate of 2.6% to 50% has been reported in the literature.<sup>7,11-13</sup> Metastases have been reported in 5% of the cases, most commonly to regional lymph nodes.<sup>7,14</sup> Routine pathology criteria do not correlate well with clinical behavior of the tumor, and it is up to the surgeon to determine malignancy based on tumor morphology and invasiveness.

In our study of 24 tumors, we had four cases of malignancy (16.7%) and no case of tumor metastasis.

### Complications

The most common complication of treatment of carotid body tumors is injury to cranial nerves, especially the vagus, glossopharyngeal, hypoglossal and facial nerves, due to their proximity to the tumor during dissection.<sup>19,31,33</sup> The prevalence of cranial nerve injury has been reported to be from 16% to 67% and averages about 45%.<sup>32-34</sup>

Among the patients in our series, we had three cases of cranial nerve injury (12.5%): one case of vagus nerve involvement in a malignant tumor, one case of glossopharyngeal nerve involvement in a malignant tumor, and one glossopharyngeal branch injury involved in a

## Carotid Body Tumors

benign tumor. We had no case of perioperative death or other complication.

### DISCUSSION

The carotid body is a 3-4 mm structure of pink-gray color located beneath the adventitial layer of the posteromedial aspect of the bifurcation of the common carotid artery on each side of the neck deep to the sternocleidomastoid muscle. Its embryological origin is from mesoderm, structures of the third branchial pouch, and neural crest ectoderm.

Cells of the carotid body are normally sensitive to changes in arterial oxygen tension ( $PO_2$ ), carbon dioxide tension ( $PCO_2$ ), and hydrogen ion concentration (pH)<sup>1</sup>, such that in response to a decrease in  $PO_2$  or an increase in  $PCO_2$  or pH, they are stimulated and this impulse by way of Hering's nerve, travels to the glossopharyngeal nerve and from there to the respiratory center in the medulla, leading to an increase in respiratory rate. Also by stimulating the hypothalamus and acting upon the vascular component of the sympathetic nervous system, it leads to an increase in arterial blood pressure.<sup>2</sup> On the other hand, this impulse leads to a decrease in the activity of the cardiac component of the sympathetic nervous system and therefore, a decrease in heart rate and cardiac contractility and can even lead to syncope, "carotid body syncope".<sup>3</sup> The latter mechanism serves the physiological basis for performing carotid body massage in the emergency treatment of paroxysmal supraventricular tachycardia.<sup>4</sup>

Tumors of the carotid body are comprised of paraganglionic cells and are thus classified under the heading of paraganglioma. Their previous nomenclature under the title of chemodectoma is therefore incorrect. The tumor is mostly benign, but a malignancy rate of 2.6% to 50% has been reported in the literature.<sup>7,11-13</sup> Tumor metastasis has been reported in approximately 50% of the cases and the most common site is regional lymph nodes.<sup>7,14</sup> Determination of tumor malignancy is mostly clinical and up to the surgeon, because routine pathology criteria for malignancy do not correlate well with clinical behavior of the tumor.

The etiology of carotid body tumors is not completely understood but several theories have been proposed by several authors. According to one of these, living at high altitudes (between 7,000 and 14,000 feet), by causing chronic stimulation of the carotid body due to relative hypoxia, may be one of the causes.<sup>5</sup> Indeed, a much higher prevalence of carotid body tumors has been reported among individuals living at these altitudes in comparison to normal controls.

Carotid body tumors are seen in two forms: a spo-

radic type which is more common and is bilateral in only 5% of cases,<sup>6,7</sup> and a familial type which is inherited as an autosomal dominant trait and is bilateral in 32% of cases<sup>7,8</sup> and comprises less than 10% of all cases.<sup>10</sup> From among the 20 patients in our study, four patients (20%) who were siblings (brother and sister), had bilateral tumors.

Carotid body tumors grow relatively slowly but may gradually impinge upon vital adjacent structures,<sup>15</sup> and prompt surgery before invasion of vital neck structures by tumor and signs of nerve paralysis due to compression arise is highly recommended.<sup>16,17</sup> They most often present as a painless, palpable mass at the area of the carotid bifurcation on the lateral aspect of the neck. Large or invasive tumors may cause hoarseness, dysphagia, dyspnea, or difficulty in speech. Cranial nerve involvement has been reported in 20% of patients and the most commonly involved nerves have been the vagus, hypoglossal, and glossopharyngeal.<sup>18</sup> Dizziness is often quoted by patients but is seldom due to true cerebral ischemia. Hypertension has been reported in 6% of patients, and is thought to be due to the rare secretion of catecholamines by the tumor.<sup>7</sup> Tinnitus, Horner's syndrome and transient ischemic attacks have also been reported.<sup>19,20</sup>

The definitive diagnosis of carotid body tumor is made by selective four-vessel cerebral arteriography, which has been emphasized by recent workers<sup>16,19,21,22</sup> and diagnostic accuracy with this modality approaches 100%.<sup>23</sup> Sonography is safe, inexpensive, effective and non-invasive and is considered to be the procedure of choice by some authors.<sup>19,22</sup> It is important to note that needle biopsy or incisional biopsy must never be used for the diagnosis of a suspected carotid body tumor, due to the danger of severe and even life-threatening hemorrhage.

Current treatment of carotid body tumor is surgical, with the aim of removing the tumor completely without compromising carotid blood flow.<sup>1</sup> Prompt surgical excision before development of compression symptoms on vital neck structures is recommended. In cases in which the tumor is small, after obtaining control of the common, internal and external carotid arteries and mobilization of the hypoglossal nerve, the tumor can usually be extirpated by careful ligation of feeding vessels using the no-touch technique and taking care not to place clamps on the very fine and fragile feeding vessels. In instances in which the tumor is large or very vascular, tumor blood supply can be greatly diminished and resection facilitated by ligation of the external carotid just distal to the bifurcation and again beyond the tumor edge distally, with en bloc excision of tumor and a segment of external carotid artery without any adverse effects for the patients.

Another technique introduced fairly recently is subadventitial removal of tumor using bipolar electrocautery of the feeding vessels.<sup>1,17</sup> This technique is mostly suitable for tumors which are small and without invasion to artery or adjacent tissue. Care should be taken during surgery not to place clamps on the common or internal carotid arteries or to interrupt their blood flow without intraoperative monitoring of cerebral function (i.e. electroencephalography, etc.) or use of an indwelling carotid shunt to maintain cerebral perfusion.<sup>32</sup> In cases in which the tumor is very large, malignant or invading the underlying artery, sacrifice of the carotid artery may be unavoidable. In cases where the internal carotid artery is occluded, this poses no problem but if the artery is patent, continuity must be restored with an arterial graft. If after removal of the tumor in such a case, sufficient artery would not be available distally for the anastomosis, it is better not to perform surgery at all than risk a cerebral infarction unless the distal stump pressure is greater than 65 mm Hg, in which case ligation of the internal carotid artery can be done safely.<sup>1</sup> A helpful point to note in this connection is that if on angiography, the angle between the internal and external carotid arteries is less than 90 degrees, then it is likely that the tumor can be dissected free from the internal carotid artery. If this angle is greater than 90 degrees however, then resection of the tumor with the artery en bloc will probably be necessary.<sup>35</sup>

A new technique which has recently been introduced is preoperative tumor embolization. This technique has been recommended by several workers.<sup>17,29-32</sup> Some of the benefits claimed for this technique include decrease in tumor size, less intraoperative blood loss, increased ease of resection, and decreased operative times.<sup>17</sup> It must be pointed out however that this method is not free from adverse side-effects, and requires special facilities and an experienced angiographer. In one report, one case of severe neurological deficit and one case of transient cerebral ischemia occurred following embolization.<sup>31</sup> Furthermore, in another article in which the results of surgery with and without preoperative tumor embolization were compared, no difference was seen in the size of the tumor or the length of operation between embolized and non-embolized cases. However, there was a significant decrease in the amount of blood loss during surgery.<sup>32</sup> Finally, for rare cases in which the tumor is far advanced and unresectable, radiotherapy may be beneficial. In some reports, excellent results have been obtained with radiotherapy alone.<sup>27,28</sup>

Tumor resection with or without ligation of the external carotid artery is the method recommended by the authors and seems to be most appropriate for Iranian patients, who generally present late and with larger tu-

mors than in the West. Other methods such as embolization are presently not available on a wide scale basis, not to mention their potential complications.

Cranial nerve injury is the most common complication of treatment of carotid body tumors. The most commonly injured nerves have been the vagus, glossopharyngeal, hypoglossal and facial.<sup>19,31,33</sup> Also injury to the recurrent laryngeal nerve and postoperative hoarseness, Horner's syndrome, carotid sinus syndrome (intraoperative bradycardia, hypotension and arrhythmias), transient cerebral ischemia, stroke and death have been reported.<sup>19,25,30-32</sup> The prevalence of injury to cranial nerves has ranged from 16% to 67% in the reports, with an average incidence of 45%.<sup>34</sup> In a comparison between our statistics and that reported in the literature, a significant difference was seen in the rate of complications in our series with that reported by others (up to 67% cranial nerve injury and 2% perioperative mortality compared to 12.5% cranial nerve injury and 0% mortality in our series). We credit these results to our precise operative technique and therefore will explain our method of resection in more detail.

### Surgical technique

After exposure of the carotid artery via the classic incision on the anterior border of the sternocleidomastoid muscle extending from the mastoid process to the sternal notch, control is obtained on the common carotid artery below the tumor. The vagus nerve is then identified and a tape passed around it. Dilated feeding vessels of the tumor (vasa vasorum) usually begin a few centimeters below the tumor and should be ligated and divided using the no-touch technique. The cephalad ends can then be dissected subadventitially upwards. Hemostats or arterial forceps should never be used on these vessels due to necrosis of the crushed area and delayed rupture with subsequent hemorrhage. As we proceed upwards dividing feeding vessels, we will reach the tumor which usually encircles the internal carotid artery and on the posterolateral aspect of this vessel where the tumor has the least thickness, the tumor is incised and bivalved. The vagus nerve is also covered by the least thickness of the tumor posterolaterally and receives few vessels from it and therefore using fine-tipped blunt scissors, a tunnel can be created over the nerve and the tumor divided longitudinally and the nerve freed and any vessels ligated. In small tumors of which we had only one case, the nerve is driven posteriorly and is not involved in the tumor.

Following freeing of the nerve, dissection of the tumor from the internal carotid artery is continued by retracting the incised edge away from the artery thereby

## Carotid Body Tumors

exposing small subadventitial feeders which are ligated and divided as described previously. This is continued both anteriorly and posteriorly until the internal carotid is completely freed from tumor. We then direct our attention to the bifurcation and after exposing the beginning of the external carotid, in large and vascular tumors, the external carotid is temporarily ligated with a no. 0 silk ligature, thereby greatly diminishing tumor blood flow and facilitating tumor removal. It should be emphasized that this artery must never be divided after ligation because the stump is not sufficient to hold the knot, resulting in the knot slipping off and severe hemorrhage which can be controlled only by clamping the common carotid artery, increasing the risk of stroke. Dissection of the tumor from the pharynx and medial elements is then continued. An important point to note at this time is that the branches of the glossopharyngeal nerve often pass through the tumor and these fine branches should not be confused with blood vessels. They should be saved by incising the tumor over the tunnel created over each branch as described previously. Branches of the external carotid artery exiting the tumor are ligated and divided and dissection continued towards the base of the skull until the trunk of the glossopharyngeal nerve is identified and freed completely from tumor, preserving its branches. In the cases presented in our series, hypoglossal nerve injury did not occur because the nerve is usually in the form of a single trunk and with care can be dissected away from the tumor, or is driven away and not involved by tumor in the first place. In none of our cases was the tumor in proximity to the facial nerve. In one of our cases in which the tumor was grossly benign, a small branch of the glossopharyngeal nerve was seen to be passing through the middle of the tumor and section of the branch was unavoidable. In another case with an obviously malignant and invasive tumor and who had undergone a previous neck exploration in another hospital and anatomic planes were obscured due to adhesion and scar tissue, branches of the glossopharyngeal nerve were unidentifiable and thus severed. In the second malignant case in which the vagus nerve was obviously involved by tumor and the patient had preoperative symptoms of hoarseness and dysphagia, section of the nerve during tumor resection was again unavoidable. In the remaining cases with benign tumors, we had no case of permanent cranial nerve injury.

After dissecting the periphery of the tumor free from its bed and all branches of the external carotid artery emanating from the tumor have been ligated and divided, we return to the bifurcation area and clear the proximal part of the external carotid from tumor for at least 1 cm so that after suture-ligating the external carotid artery, it can be safely divided distal to the ligature

and the tumor removed.

Carotid body tumor is a relatively rare entity which with its slow growth can cause serious disability for the patient. If one is familiar with this tumor, the presence of a firm, often pulsatile mass at the carotid bifurcation deep to the sternocleidomastoid muscle is sufficient to clinch the diagnosis. If available, bilateral selective cerebral arteriography is helpful in confirming the diagnosis and planning the surgical approach.

With timely diagnosis and prompt surgical treatment of this potentially benign tumor, the unfortunate consequences such as cranial nerve paralysis can be avoided.

### REFERENCES

1. Dean RH: Carotid body tumors. In: Sabiston DC (ed). *Textbook of Surgery*. Philadelphia, W.B. Saunders Co. p. 1562, 1991.
2. Guyton AC: The circulation. In: Guyton AC (ed). *Textbook of Medical Physiology*. Philadelphia, W. B. Saunders Co., pp. 250, 508, 1986.
3. Gann DS, Amaral JF: Endocrine and metabolic responses to injury. In: Schwartz, Shires, Spencer (eds). *Principles of Surgery*. 5th edition, New York, McGraw-Hill, p. 5, 1989.
4. Meredith J: Cardiac arrhythmias in the postoperative patient. *Surg Clin North Am* 49:1083, 1963.
5. High-altitude chemodectoma (editorial). *Lancet* 1:1493, 1973.
6. McIlrath DC, ReMine WH: Carotid body tumors. *Surg Clin North Am* 43:1135, 1963.
7. Shamblin WR, et al: Carotid body tumor. Clinicopathological analysis of 90 cases. *Am J Surg* 122:732, 1971.
8. Grufferman S, et al: Familial carotid body tumors. Case report and epidemiological review. *Cancer* 46: 2116, 1980.
9. Rush BF, Jr: Familial bilateral carotid body tumors. *Ann Surg* 157: 633, 1963.
10. Sobol SM, Dailey JC: Familial multiple cervical paragangliomas: report of a kindred and review of the literature. *Otolaryngol Head Neck Surg* 102 (4): 382-90, 1990.
11. Chambers RG, Mahoney WD: Carotid body tumors. *Am J Surg* 116: 554, 1968.
12. Gaylis H, Miény CJ: The incidence of malignancy in carotid body tumors. *Br J Surg* 64: 885, 1977.
13. Staats EF, Brown RL, Smith RR: Carotid body tumors, benign and malignant. *Laryngoscope* 76: 907, 1966.
14. Irons GB, Weiland LH, Brown WL: Paragangliomas of the neck: clinical and pathological analysis of 116 cases. *Surg Clin North Am* 57: 575, 1977.
15. Pantanowitz D, et al: Are carotid body tumors malignant? *S Afr J Surg* 28 (3): 97-9, 1990.
16. Bernard PR: Carotid body tumors. *Am J Surg* 163 (5): 494-6, 1992.
17. Ward PH, Liu C, Vinuela F, Bentson JR: Embolization: an adjunctive measure for removal of carotid body tu-

- mors. *Laryngoscope* 98 (12): 1287-91,1988.
18. Davidge-Pitts KJ, Pantanowitz D: Carotid body tumors. *Surg Annu* 16: 203,1984.
  19. Keating JF, Miller GA, Keaveny TV: Carotid body tumors: report of six cases and a review of management. *J R Coll Surg Edinb* 35 (3): 172-4,1990.
  20. Chamorro-Sanchez A, et al: Carotid body tumor: unusual cause of transient ischemic attacks. *Stroke* 19 (1): 102-3,1988.
  21. Krause DH, et al: Carotid body tumors. *Arch Otolaryngol Head Neck Surg* 116 (12): 1384-7,1990.
  22. Warshawski SJ, de Souza FM: The carotid body tumor. *J Otolaryngol* 18 (6): 306-10,1989.
  23. Williams MD, Phillips MJ, Nelson WR, Rainer WG: Carotid body tumor. *Arch Surg* 127 (8): 963-7,1992.
  24. Iacconi P, Spinelli C, Cecchini GM, et al: Carotid body tumors: a review of eight cases. *Eur J Surg Oncol* 18 (2): 93-7,1992.
  25. Rosen RD, Weiss M, Milman B, et al: Carotid body tumor: diagnostic and therapeutic approach. *South Med J* 85 (7): 756-9,1992.
  26. Krupski WC, Effeney DT: Arteries. In: Way LW (ed). *Current Surgical Diagnosis and Treatment*. Norwalk, Appleton and Lange, p. 743,1991.
  27. Valdagni R, Amichetti M: Radiation therapy of carotid body tumors. *Am J Clin Oncol* 13 (1): 45-8,1990.
  28. Powell S, Peters N, Harmer C: Chemodectoma of the head and neck: results of therapy in 84 patients. *Int J Radiat Oncol Biol Phys* 22 (5): 919-24,1992.
  29. Smith RF, Shetty PC, Reddy DJ: Surgical treatment of carotid paragangliomas presenting unusual technical difficulties. The value of preoperative embolization. *J Vasc Surg* 7 (5): 631-7,1988.
  30. Robison JG, Shagets FW, Beckett WC Jr, Spies JB: A multidisciplinary approach to decreasing morbidity and operative blood loss during resection of carotid body tumors. *Surg Gynecol Obstet* 168 (2): 166-70,1989.
  31. Wax MK, Briant JD: Carotid body tumors: a review. *J Otolaryngol* 21 (4): 237-85,1992.
  32. LaMuraglia GM, Fabian RL, Brewster DC, et al: The current surgical management of carotid body paragangliomas. *J Vasc Surg* 15 (6): 1038-44,1992.
  33. Daudi FA, Thurston OG: Carotid body tumors: the University of Alberta Hospital experience. *Can J Surg* 32 (3): 159-61,1989.
  34. Hallett JW Jr, Nora JD, Hollier LH, et al: Trends in neurovascular complications of surgical management of carotid body and cervical paragangliomas. A 50 year experience with 153 tumors. *J Vasc Surg* 7 (2): 284-91,1988.
  35. Pantanowitz D, Davidge-Pitts K, Demetriades D: The significance of the carotid bifurcation angle in carotid body tumors. *S Afr Med J* 80 (7): 318-21,1991.