

Case Reports

TUFTED HAIR FOLLICULITIS

J. GOLCHAI, AND J. SHAMS GILANY

From the Department of Dermatology, Razi hospital, Rasht, Islamic Republic of Iran.

ABSTRACT

A 28 year old albino man presented with a cicatricial alopecic plaque on the vertex. The patient had multiple hairs emerging from a single dilated follicular opening. Following inflammatory changes, new tufted hair appeared in spite of several periods of antibiotic treatment, and the disorder followed a relapsing and destructive course.

Tufted hair folliculitis (THF) is a relapsing localized inflammatory disease of the scalp. Unfortunately, this situation results in cicatricial alopecia. This disease, initially designated as "THF" by Smith and Sanderson in 1978, has been reported in only 10 patients to date.

MJIRI, Vol. 8, No. 2, 127-128, 1994.

Keywords: Tufted folliculitis, Scalp folliculitis

CASE REPORT

A 28 year old albino man had a persistent, severely pruritic, exudative and erythematous lesion on his vertex of three years' duration.

Physical examination revealed a 10×5 cm, mildly tender, pruritic plaque on the vertex. At the margin of the plaque there were multiple tufts of 5-10 hairs arising from each hair ostium. The plaque had undergone recurrent episodes of exudation and crusting, and follicular discharge of purulent material was evident. Laboratory investigations except for those mentioned below were normal. Several cultures from discharges revealed *S. aureus*. In histopathologic examination, mild perifollicular inflammation and an infiltration of lymphocytes, PMNs and plasma cells involving

the mid-dermis was reported.

The patient was treated with topical and systemic antibiotics (cloxacillin, cephalixin and co-trimoxazole). In spite of mild and transient improvement, several follicular pustules formed around the plaque. Slight pressure around the follicle produced a purulent discharge and *Staphylococcus aureus* was isolated. The folliculitis relapsed after discontinuing therapy.

After multiple episodes of erythema, swelling, and scaling, peripheral extension of the lesion and newly-formed tufted hairs ultimately resulted in a progressive scarring alopecia.

DISCUSSION

THF is a progressive, recurrent, exudative and erythematous plaque with perifollicular inflammation and is characterized by multiple hair tufts arising from a single hair ostium.

Address for correspondence:

J. Golchai, M.D.

Department of Dermatology, Razi Hospital, Rasht, Islamic Republic of Iran.

Tufted Hair Folliculitis

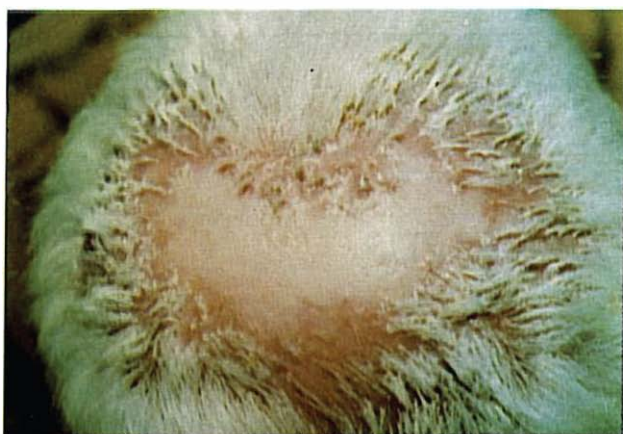

Fig. 1. Scarring alopecia with tufted hairs arising from a common ostium.

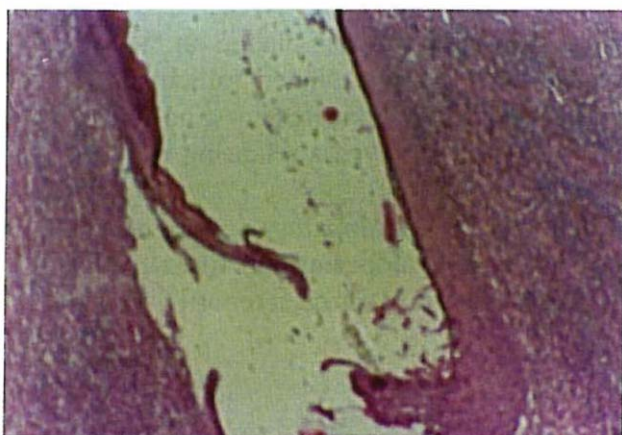

Fig. 2. A dilated common follicular duct surrounded by monocyctic and histiocytic infiltrations.

Age of onset varies from 19-53 years. The disease appears as a single or multiple erythematous exudative plaques involving the scalp. Within the affected areas, several tufts of 5 to 20 normal hairs emerge from a single follicle¹⁻⁴ (Fig. 1) Over a variable period from weeks to months, local tenderness, exudation and pruritus indicate recurrence and exacerbation. After subsequent relapses, an erythematous, scaly and cicatricial alopecia with new tufts of hair appear around the plaque.

Perifollicular inflammation around the upper portion of hair follicles with widely dilated ducts and infiltrations of plasma cells are the main histopathological features. Sometimes a ruptured follicle causes a foreign body granulomatous reaction to occur (Fig. 2,3).

Smith and Sanderson suggested that a local inflammatory process leads to destruction of superficial parts of the follicle and ultimately causes local fibrosis and scarring.¹

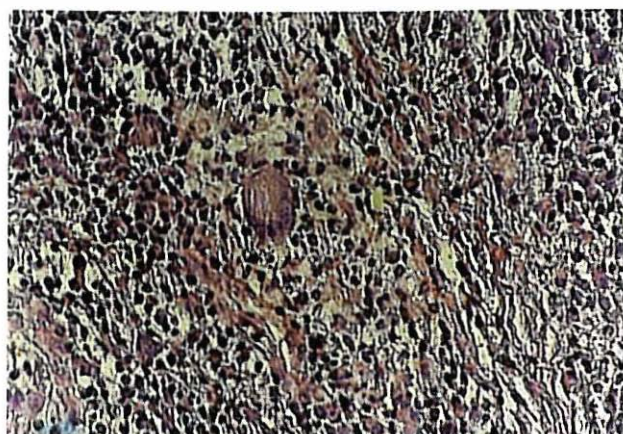


Fig. 3. A high power magnification shows foreign body giant cells, histiocytes and polymorphonuclear leukocytes.

Some authors postulated a possible immunological defect that leads to an increased susceptibility to *S. aureus*.^{2,3,4}

The differential diagnosis includes all conditions that are characterized by multiple hair bundles; folliculitis decalvans (FD) is characterized by the presence of cicatricial alopecia with marginal multiple pustules.²⁻⁵

Dissecting cellulitis (DC) is characterized by multiple nodules on the scalp that become fluctuant and ultimately form sinuses. Although these conditions have some similarities with THF, nodules and sinuses are not common features in the latter, and, conversely, hair bundles are not usual findings in FD and DC.^{3,6}

Management is very difficult. Topical antiseptics and oral antibiotics (cephalexin, cloxacillin and erythromycin) diminish the inflammatory process but do not affect hair tufting. Sometimes surgical operations might lead to good results.

REFERENCES

1. Smith NP, Sanderson KV: Tufted folliculitis of the scalp. *J Roy Soc Med* 71: 606-608, 1978.
2. Tong AKF, Baden HP: Tufted hair folliculitis. *J Amer Acad Dermatol* 21: 1096-1099, 1989.
3. Dalziel KL, Telfer NR, Wilson CL, Dawber RPR: Tufted folliculitis: A specific bacterial disease. *Amer J Dermatopathol* 12: 37-41, 1990.
4. Pujol RM, Matius-Guiu XM, et al: Tufted-Hair Folliculitis. *Clinical and Experimental Dermatology* 16: 199-201, 1991.
5. Bogg A: Folliculitis decalvans. *Acta Dermato, Venerologica Stockholm* 43: 24, 1963.
6. Barney RE: Dissecting folliculitis of the scalp. *Archives of Dermatology* 23: 503-518, 1931.