

MULTIPLE ENCHONDROMATA: OLLIER'S DISEASE

K.H. MAHLOUJI

*From the Ali Asghar Medical Center, Children's Hospital, Iran University of Medical Sciences, Tehran,
Islamic Republic of Iran.*

ABSTRACT

This report is a brief presentation of one case of Ollier's disease. Ollier's disease (multiple enchondromata) patients have widespread involvement of the skeleton, especially the hands; the lesions are detected because of bone pain or deformity. Virtually all cases have been sporadic.

Roentgenographically, the lesions may be detectable in early infancy as clear, homogeneous, oval lesions with axes parallel to the longitudinal axis of the bone. *MJIRI, Vol. 8, No. 2, 129-131, 1994.*

CASE REPORT

A 10 year old boy was admitted to the hospital for lumps on flexor surfaces of almost all joints of the fingers and toes of 2 years' duration. He was well until 8 years of age when he started to develop small tumor masses 2×2 and 5×5 cm on metaphyseal zones of both upper and lower extremities. The lumps had a round shape with a shiny pale surface

He is the 9th child of a total of 11 children, five male and six female. Four sibs died at one and two years of age, presumably from measles, and the rest are apparently healthy. Parents are not related. Family history is negative for similar illness.

Past history was not remarkable except that he had measles followed by a suppurative adenitis in the groin which needed hospitalisation for 30 days.

Significant physical findings were: wt. 30kg, ht. 110cm, BP 100/60. Abnormal physical findings were limited to skin and joints. Many skin nevi of dark color were noted all over the body. Distal ends of all bones in both extremities were bulky and overgrown (Figs. 1-3).

Lab tests: Hb 14.5 g/dL, Hct 44%, WBC 7200/mm³,

PMN 50%, Lymph 44%, Eos 1%, ESR 15mm/1st hour, Ca 11.2 mg/dL, P 5.5 mg/dL, Alkaline phosphatase 58 units (normal for age), L.E. cell prep, once positive and once negative, BUN normal, uric acid normal, urinalysis normal, platelet count increased, IgG slightly decreased, IgA moderately and IgM slightly increased compared to normal values.

X-rays of involved bones showed expansion of metaphyses with radiolucent areas.

Biopsy of bone lesions taken from metaphysis reported chondroid tissue. Skin biopsy reported hyperkeratosis and slight acanthosis, fibrosis of dermis and atrophy.

DISCUSSION

Patients with Ollier's disease usually complain of bone pain and eventually develop deformities of hands and go on to have widespread skeletal malformations. Virtually all cases have been sporadic. Bone lesions could be detected in early infancy by x-ray, as clear homogenous oval lesions with axes parallel to longitudinal axes of the bones. Some patients present with growth disturbance and limping due to swelling of toes. These lesions may be symmetric or asymmetric. They may produce visible or palpable swelling

Correspondence: K.H. Mahlouji Associate Professor of Pediatrics
Ali Asghar Med. Center, Tehran, Iran.

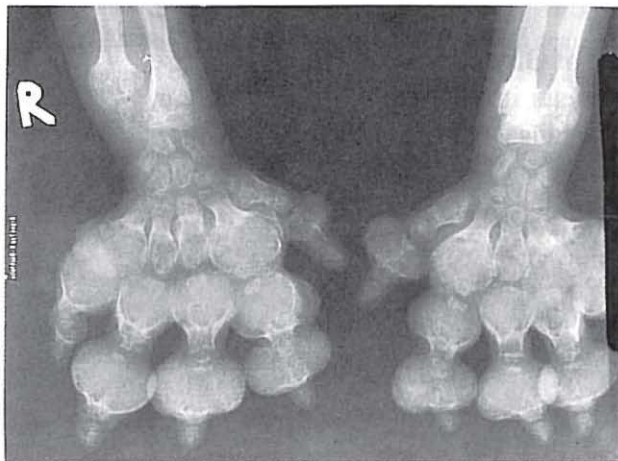
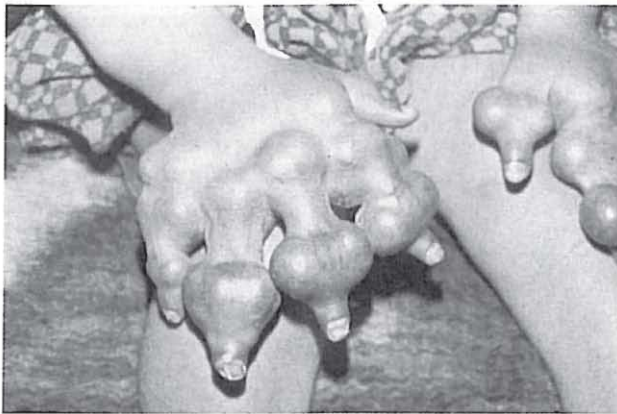


Fig. 1,2. Distal ends of all bones in hands were bulky and over grown.

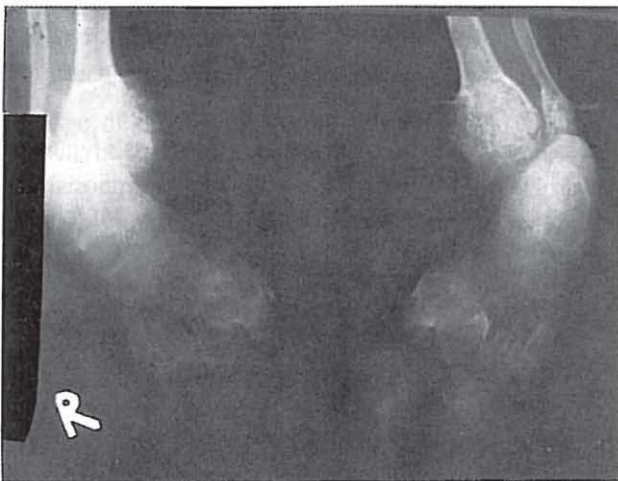

Fig. 3. Distal ends of all bones in feet were bulky and over grown also.

particularly in the hands or on the distal ends of the long bones. They are somewhat elastic and may cause limitation of motion in adjacent joints. Phalangeal chondromas may lead to severe deformities of the fingers.^{8,9,11-14}

The effect of enchondromas on growth is usually much more serious than that of exostoses and the prognosis is worse. Asymmetric growth disturbances are more troublesome. Involvement of the distal ulna and radius may cause severe deformity of the wrist leading to ulnar deviation of involved hands. Malignant transformation is more common in adults than children.^{1-6,10,15-20} Tenderness and rapid growth in size and or radiologic evidence of endosteal erosion may indicate a malignant process.^{2,8,14}

Surgical intervention is necessary for lesions causing local symptoms.⁷

REFERENCES

1. Liu J, Hudkins PG, Sweet RG, Unni KK: Bone sarcomas associated with Ollier's disease. *Cancer* 59(7): 1376-85, 1987.
2. Achwartz HS, Zimmerman NB, Simon MA, Wroble RR, Millar EA, Bonfiglio M: The malignant potential of enchondromatosis. *J Bone Joint Surg Am* 69(2): 269-74, 1987.
3. Miki K, Kawamoto K, Kawamora Y, Matsumura H, Asada Y, Hamada A: A rare case of Maffucci's syndrome combined with tuberculum sellae enchondroma, pituitary adenoma and thyroid adenoma. *Acta Neurochir Wien* 87(1-2): 79-85, 1987.
4. Rawlings CE: A case of Ollier's disease associated with two intracranial gliomas. In: Bullard D, Burger PC, Friedman AH. (eds.), *Neurosurgery*, pp. 400-403, 1987.
5. Mawhinney HJ: Chondrosarcoma in Maffucci's syndrome [letter] *J Bone Joint Surg Am* 68(6): 953, 1986.
6. Vaz RM, Turner C: Ollier disease (Enchondromatosis) associated with ovarian juvenile granulosa cell tumor and precocious pseudopuberty. *J Pediatr* 108(6): 945-7, 1986.
7. Fatti JF, Mosher JF: Treatment of multiple enchondromatosis (Ollier's disease) of the hand. *Orthopedics* 9(4): 512-8, 1986.
8. Suzuki A, Ito S, Takechi H: Follow-up study of cartilaginous bone tumors. *Acta Med Okayama* 40(3): 147-61, 1986.
9. Mellon CD, Carter JE, Owen DB: Ollier's disease and Maffucci's syndrome: distinct entities or a continuum. Case report: Enchondromatosis complicated by an intracranial glioma. *J Neurol* 235(6): 376-8, 1988.
10. Velasco Oses A, Alonso Alvaro AL, Blanco Pozo A, Nogales FF: Ollier's disease associated with ovarian juvenile granulosa cell tumor. *J Cancer* 1, 62(1): 222-5, 1988.
11. Ben Itshak I, Denolf FA, Verstfeld GA, Noll BG: The Maffucci syndrome. *J Pediatr Orthoped* 8(3): 345-8, 1988.
12. Cannon SR, Sweetnam DR: Multiple chondrosarcomas in dyschondroplasia (Ollier's disease). *Cancer* 55(4): 836-40, 1985.
13. Sutthipaisal N, Nitidandhaprabhas P: A case of Maffucci's syndrome (dyschondroplasia with multiple hemangioma). *J Med Assoc Thai* 72(7): 404-7, 1989.
14. Urist MR: A 37-year follow-up evaluation of multiple-stage femur and tibia lengthening in dyschondroplasia (enchondromatosis) with a net gain of 23.3 centimeters. *Clin Orthop* (242): 137-57, 1989.

15. Pospiech J, Mehdorn HM, Reinhardt V, Grote W: Sellar chondroma in a case of Ollier's disease. *Neurochirurgia Stuttg* 32(1): 30-5, 1989.
16. Traflet RF, Babaria AR, Barolat G, Doan HT, Gonzalez C, Mishkin MM: Intracranial chondroma in a patient with Ollier's disease. Case report. *J Neurosurg* 70(2): 274-6, 1989.
17. Weyl Ben Arush M, Oslander L: Ollier's disease associated with ovarian Sertoli-Leydig cell tumor and breast adenoma. *Am J Pediatr Hematol Oncol* 13(1): 49-51, 1991.
18. Peleiderer AG, Thomson P, Milroy CM: View from beneath: Pathology in focus. ENT presentation of Ollier's disease. *J Laryngol Otol* 105(2): 148-50, 1991.
19. Bushe KA, Naumann M, Warmuth Metz M, Meixensberger J, Muller J: Maffucci's syndrome with bilateral cartilaginous tumors of the cerebellopontine angle. *Neurosurgery*, 27(4): 625-8, 1990.
20. Patt S, Weigel K, Mayer HM: A case of dyschondroplasia associated with brainstem glioma: diagnosis by stereotactic biopsy. *Neurosurgery* 27(3): 487-91, 1990.