

# AUTOLOGOUS MARROW TRANSPLANTATION IN THE TREATMENT OF MOPP AND ABVD-RESISTANT HODGKIN'S DISEASE

TALEB AZARM, M.D.

*From the Division of Hematology/Oncology and B.M.T., Seyed-al-Shohada Hospital, Isfahan University of  
Medical Sciences, Isfahan, Islamic Republic of Iran.*

## ABSTRACT

Six patients with disseminated Hodgkin's disease resistant to MOPP (mechlorethamine, vincristine, procarbazine and prednisolone), and ABVD (adriamycin, bleomycin, vinblastine and dacarbazine) chemotherapy were treated with high-dose chemotherapy and autologous marrow transplantation. The patients first underwent marrow aspiration and storage for subsequent autologous bone marrow transplantation (ABMT).

Three patients remain alive in unmaintained complete remission (CR) at 18, 17, and 15 months after transplant. In the other three patients, reasons for failure included relapse in two patients after 7 and 8 months, and death after 6 months due to pulmonary infection (pneumonia).

These results demonstrate that some patients with MOPP, ABVD and other salvage chemotherapy (SC)-resistant Hodgkin's disease can obtain prolonged complete remission following intensive chemotherapy and autologous marrow transplantation.

*MJIRI, Vol. 8, No. 1, 9-16, 1994.*

**Keywords:** Autologous marrow transplantation, Hodgkin's disease.

## INTRODUCTION

Even though malignant lymphoma can be considered among the most sensitive of malignancies regarding response to chemotherapy and radiation therapy, Hodgkin's disease is one of the malignancies most curable with this therapy.<sup>1</sup> Patients who present with stage 1 disease can be cured approximately 90% of the time with regional radiotherapy, and patients with stage 2 disease who do not present with a large mediastinal mass can be cured approximately 70% of the time with extended field radiotherapy.<sup>1,2</sup> Patients who present with more extensive disease, or who have a recurrence after receiving primary radiotherapy, can frequently be cured with chemotherapy.<sup>2,4</sup> Since the original report of cure of Hodgkin's disease utilizing MOPP (mechlorethamine, oncovine { vincristine }, procarbazine, prednisone), a variety

of other combinations of chemotherapeutic agents have been demonstrated to have curative potential.<sup>3,4</sup> Controversy continues regarding the best chemotherapy regimen for Hodgkin's disease. Some physicians favor a MOPP or a MOPP-like regimen alone, some ABVD (adriamycin {doxorubicin}, bleomycin, vinblastine, dacarbazine)<sup>5,6</sup> and others a combination of the two approaches. With the optimal application of each of these chemotherapeutic strategies patients who present with extensive disease but without systemic symptoms have a greater than 80% long-term, disease-free survival, whereas patients with systemic symptoms are cured less often.<sup>2,4</sup> Approximately one-third of all patients who develop Hodgkin's disease will eventually need salvage chemotherapy (SC).<sup>7</sup> Hodgkin's disease is one of the few malignancies in which cure is possible after an initial, effective chemotherapy regimen fails.<sup>7,8</sup> A few patients

## Marrow Transplantation in Resistant Hodgkin's Disease

Table I: The clinical characteristics of six patients.

No.	Age	Sex	Stage of HD	Histology	"B" symptoms	No. of relapse
1	51Y	M	4	MC	+	Third Relapse
2	36Y	M	4	MC	+	Third Relapse
3	28Y	F	4	LD	+	Without CR*, 4m PR*, relapsed
4	26Y	M	4	NS	+	Third relapse
5	23Y	M	4	MC	+	Second relapse
6	30Y	M	4	LD	+	Third relapse

Y: year, MC: Mixed cellularity, LD: Lymphocyte depletion, NS: Nodular sclerosing.

\*CR: complete response, PR: partial response

treated primarily with chemotherapy have a local recurrence and can be cured with subsequent local /regional radiotherapy.<sup>9</sup> There is also some evidence that patients with a very long initial remission are especially likely to benefit from repeating their initial chemotherapy regimen.<sup>10,11</sup> However, most patients will not fall under either of these, achieving a complete remission (CR). Those who do not achieve an initial remission with chemotherapy, and patients in whom more than one chemotherapy regimen fails have a poor prognosis.<sup>11</sup> Even for patients in whom MOPP fails and who then receive ABVD, the long-term, disease free survival

rate is not much greater than 10%.<sup>12</sup> Patients with disease resistant to both MOPP and ABVD sometimes respond to third-line regimens, but long-term, disease-free survival is very uncommon in this setting.<sup>13,14</sup> Until recently, the only option available for patients after a chemotherapy relapse was treatment with similar or noncross-reactive salvage chemotherapy regimens. This low chance for cure has provided a stimulus for seeking alternate treatment approaches in these patients.

High-dose chemotherapy with reinfusion of autologous bonemarrow cells to alleviate otherwise often hematopoietic toxicity has become an increasingly popular treatment for a variety of malignancies.<sup>15,21</sup> Because disease occurs in young patients, it is an obvious condition in which to utilize bone marrow transplantation. Advances in the area of autologous bone marrow transplantation have been associated with numerous reports of very promising pilot studies.<sup>14,22</sup> Autologous bone marrow transplantation (ABMT) offers an attractive alternative to salvage chemotherapy (SC) and phase 2 trials of high-dose chemotherapy followed by autologous bone marrow rescue have frequently resulted in higher complete remission rates and longer disease-free survival than previous series using salvage chemotherapy.<sup>19,21</sup>

High-dose chemotherapy followed by marrow transplantation has been shown to be able to cure patients with a variety of hematologic malignancies even after conventional therapy has failed.<sup>15,22</sup> Numerous groups have

Table II: Pretransplant characteristics of six patients transplanted for relapsed Hodgkin's disease.

N	Response to MOPP*	Other prior Chemotherapy	Interval from D to ABMT	Prior radiotherapy	Major disease sites at time of ABMT
1	CR 6 mo.	ABVD B C MOPP/ABVD	18 months	Mantle, Ribs	Nodes, Bone, Liver, Mediastinum, Spleen
2	CR 12 mo.	MOPP/ABVD BCNU & ABVD	21 months	Mantle, Cervical	Nodes, Skin, Spleen, Liver
3	CR 7 mo.	MOPP/ABVD BCNU	25 months	Mantle	Nodes, Lung, Mediastinum
4	CR 4 mo.	MOPP/ABVD ABVD	16 months	None	Nodes, Liver, Lung, Spleen
5	PR 6 mo.	MOPP/ABVD ABVD	13 months	None	Nodes, Spine, Bone, Spleen
6	CR 10 mo.	BACOD, MOPP LOPP+BCNU	31 months	Spine, Mediastinum	Nodes, Liver, Bone, Spine, Lung

\*CR: complete response, PR: partial response, mo: months.

C: cycle, D: diagnosis.

LOPP: chlorambucil, vincristine, procarbazine, prednisolone.

BACOD: bleomycin, adriamycin, cyclophosphamide, vincristine and prednisolone.

TABLE III: Schedule of chemotherapy.

Agent	Total Daily Dose	Route	DAY					
			-5	-4	-3	-2	-1	0
Cyclophosphamide	50 mg/kg	IV	*	*	*	*	R	A
Etoposide (VP-16)	250 mg/m <sup>2</sup>	IV	*	*	*	*	E	B
							S	M
							T	T
Busulfan	4 mg/kg	PO	*	*	*	*	D	D
							A	A
							Y	Y

IV: intravenously, PO: orally

reported durable complete remission after autologous bone marrow transplantation for Hodgkin's disease.<sup>24</sup> Long-term, disease-free survival exceeding 40% has been reported in selected patients with Hodgkin's disease.<sup>20-24</sup> Armitage et al. have suggested that ABMT should be considered in patients who fail or relapse after primary induction therapy.<sup>2,16,23</sup> These encouraging results and expanding indications have resulted in an increase in the number of ABMTs performed for patients with lymphoma. Despite the increased use of ABMT, the optimal preparative regimen for advanced Hodgkin's disease has not been identified.

Ideally, the preparative regimen should exploit dose-response relationships and have acceptable toxicity. In addition, regimens lacking total especially desirable for patients with lymphoma because TBI following mediastinal irradiation (>2000 cGy) increases the risk of fatal

introduced the combination of busulfan and etoposide (VP-16) as a preparative regimen, and busulfan, cyclophosphamide, melphalan,<sup>14</sup> and other combinations<sup>23-27</sup> as an alternative conditioning regimen for such patients.

To determine if a similar approach would benefit our patients with advanced Hodgkin's disease who had developed MOPP and ABVD and other protocol regimens chemotherapy-resistant disease, six such patients were treated with high-dose chemotherapy with cyclophosphamide, etoposide (VP-16) and busulfan (CVB regimen) and autologous bone marrow transplantation (ABMT). This report presents the therapeutic results observed in these patients.

## PATIENTS AND METHOD

From June 1991 to December 1991, 6 consecutive advanced recurrent Hodgkin's disease patients resistant to MOPP and ABVD chemotherapy with active disease who fulfilled the eligibility criteria listed below were entered into the protocol and received intensive chemotherapy and

autologous B.M.T. at Seyyed-al-Shohada Medical Center, Isfahan University of Medical Sciences. First the diagnosis of Hodgkin's disease was confirmed by a review of biopsy specimens. The clinical characteristics of the patients are presented in Table I.

### Eligibility Criteria

1. Progressive Hodgkin's disease after multi-agent chemotherapy given with curative intent,
2. Presumed incurability with further conventional therapy, specifically excluding patients with localized recurrences potentially curable with radiotherapy.
3. Age  $\leq$  51 years,
4. No evidence of marrow involvement with Hodgkin's disease at the time of marrow harvest,
5. Absence of severe comorbid illness precluding intensive chemotherapy, and
6. Previous exposure to no more than one of the agents used in the CVB conditioning regimen.

Patients were ineligible if they had prior pelvic irradiation, or if a bone marrow biopsy prior to ABMT had evidence of involvement with Hodgkin's disease.

Patients between the ages of 23 to 51 years were resistant to MOPP and ABVD and had either progressed during primary chemotherapy or relapsed within the first 12 months of completion of MOPP or MOPP/ABVD. Four of the six patients had also failed other salvage chemotherapeutic programs. At the time of transplantation all patients were in relapse and all had extranodal involvement. The pretransplant characteristics of six patients are presented in Table II. The technique of marrow transplantation varied according to the protocols in use at Seattle at the time of transplantation.<sup>28,30</sup>

All risks and method of the treatment protocol were fully explained to patients and relatives and informed consent was obtained in writing from all patients. One to two weeks prior to bone marrow aspiration and harvest, patients underwent an evaluation including restaging of the tumors (clinical staging), hemogram, chemistry profile, chest radiography, cardiac examination and EKG, bone marrow



## Marrow Transplantation in Resistant Hodgkin's Disease

**TABLE IV: Complications of high-dose chemotherapy in six patients with relapsed Hodgkin's disease.**

Toxicity	No.	%
Mucositis	6	100
Severe stomatitis	2	33
Neutropenic fever	6	100
Bacteremia	1	17
Fever of unknown origin	5	83
Oral candidiasis	6	100
Diarrhea	2	33
Transient abnormal liver function tests	1	17
Pulmonary infection	3	50
Transient dysuria	4	67
Transient macroscopic hematuria	1	17

**TABLE V: Hematologic recovery after ABMT**

Cells	Days post ABMT
Neutrophils $\geq 0.5 \times 10^9/L$	24 (range 18-31)
Leukocytes $\geq 1.5 \times 10^9/L$	19 (range 16-30)
Platelets $\geq 50 \times 10^9/L$	37 (range 32-43)

examination, renal and liver function tests, pulmonary function studies and dental examination. All patients had a central venous catheter inserted at the time of bone marrow harvest.

Bone marrow was harvested under general anesthesia, and between  $1.8$  to  $5.2 \times 10^8$  nucleated cells per kilogram of patient weight were collected.

The patients proceeded directly to ABMT after marrow aspiration at a median of 7 days (range 6-9 days)<sup>30</sup> of protocol entry. Aspiration and harvest was performed on day-7 of ABMT and reinfusion on day 0. Marrow was aspirated with a Jamshidi needle. Single aspirations of

between 2-5 ml were collected sequentially from multiple puncture sites. All marrow aspirations were performed only from the posterior iliac crests. A unit of whole blood was removed and stored from patients and was reinfused during the marrow harvesting procedure.

### High-dose therapy regimen

The high-dose therapy regimen in all patients consisted of:

1- Cyclophosphamide 50mg/kg/day for four consecutive days,

2- Etoposide (VP-16) 125mg/m<sup>2</sup> twice daily for three consecutive days (ABMT-Days: -5 through -3),

3- Busulfan orally 3.5mg/kg/day for four consecutive days, from day-5 through -2. Busulfan doses were repeated if the patient vomited within one hour of receiving the dose. Doses of chemotherapy were based on ideal body weight. The schedule of chemotherapy is shown in Table III. All patients underwent bladder irrigation to ameliorate cyclophosphamide-associated bladder injury.

Busulfan was administered orally at a dose of 3.5mg/kg/day in three divided doses for four days (total dose, 14mg/kg), starting from day-5 of the ABMT protocol.

Cyclophosphamide was administered intravenously at a dose of 50mg/kg on each of four successive days. This treatment was followed by etoposide 125mg/m<sup>2</sup> twice daily, administered intravenously for three consecutive days, (from day-5 to -3 of ABMT protocol). Marrow was infused 72 hours after the last dose of etoposide.

The patients received nonabsorbable oral antibiotics and a low-bacteria diet. Systemic prophylaxis with amikacin and piperacillin was begun on the day of transplantation (day 0), and continued until the granulocyte count exceeded  $0.5 \times 10^9/L$  and the patient was afebrile.

Patients with persistent unexplained fever were treated

**TABLE VI: Results of Autologous Bone Marrow Transplantation in six patients with relapsed Hodgkin's disease.**

No.	Survival	C.R.	Relapse	Outcome
1	11 mo.	Yes	Yes, after 7 mo.	Death 4 mo. after relapse
2	18 mo.	Yes	No	Alive in C.R., Karnofsky score
3	17 mo.	Yes	No	Alive in C.R., Karnofsky score 100%
4	6 mo.	Yes	No	Death after 6 mo. of C.R. due to pulmonary infection
5	15 mo.	Yes	No	Alive in C.R., Karnofsky score 100%
6	10 mo.	Yes	Yes, after 8 mo.	Death 2mo. after relapse

C.R.: complete remission, mo: months.

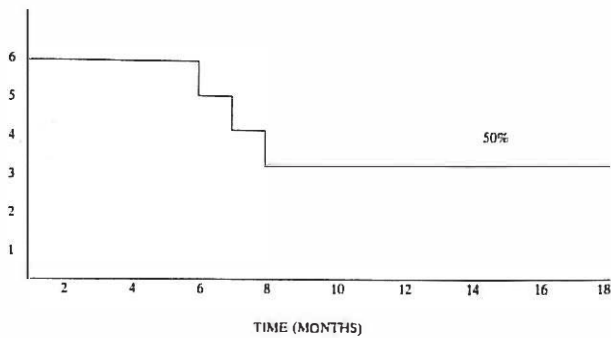


Fig. 1: Overall survival with complete remission (disease-free survival) of six patients with refractory Hodgkin's disease after ABMT.

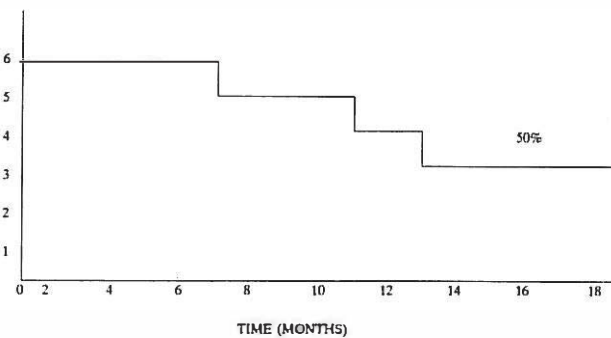


Fig. 2: Overall survival of six patients with refractory Hodgkin's disease after ABMT.

with Amphotericin B.

On day 0 of ABMT protocol the marrow was reinfused at a rate of approximately 200 to 250 ml/hour. Patients were housed in separate rooms (Low Bacterial Contamination Rooms), and hand washing, gowning and masking were required to enter the room. Oral antifungal prophylaxis with nystatin suspension was started on day+1 ABMT and continued until the total granulocyte count recovered to  $0.5 \times 10^9/L$ .

On the day prior to the first dose of intensive chemotherapy, patients were started on oral phenytoin (300mg/daily) and allopurinol 300mg daily. Phenytoin was administered for five consecutive days. The final dose of allopurinol was administered on day-2 of ABMT. A two-day rest period (days-2 and-1) was scheduled between the last dose of chemotherapeutic drugs and marrow infusion.

### Regimen-related toxicity

Most of the signs of regimen-related toxicity were during etoposide (VP-16) infusion. The etoposide infusion period was associated with hypotension (more than 10% decrease in systolic pressure) in two cases, and fever (more than  $38^{\circ}C$ ) in three cases. The hypotension and fever appeared to be ameliorated by premedication with intravenous

dexamethasone 10 mg 30 min prior to VP-16 infusion, then 5mg/6h for four doses, and acetaminophen. One patient developed anaphylactic-type symptoms as manifested by tachycardia, tachypnea, and wheezing during the VP-16 infusion. These symptoms resolved after treatment with oxygen and intravenous diphenhydramine. One patient developed mild diffuse erythema. Although vomiting occurred in all patients, it was usually of short duration and mild to moderate in severity.

### Complications after ABMT

Severe stomatitis (inability to eat) occurred in three of six patients on day 7, mucositis was frequently moderate to severe and two patients required parenteral nutrition. Two patients developed acral erythema and in another case areas of prior trauma were also affected. One patient developed generalized erythroderma that progressed to bullous formation and desquamation. The erythroderma was first detectable at day 6 following transplant and after 12 days improvement was noticeable.

All patients developed neutropenic fever requiring broad spectrum antibiotics. One patient had documented infection with pseudomonas. Five patients received prophylactic acyclovir, and one patient not receiving prophylactic acyclovir developed symptomatic mucosal infections with herpes zoster and was treated with acyclovir. Varicella zoster infection was seen in two patients within 6 months of protocol entry. Mild reversible abnormalities of liver function tests were observed in one patient. No clinical hepatic veno-occlusive disease was seen.

The major procedure-related toxicities were significant neutropenia and thrombocytopenia. Febrile episodes occurred in all patients (100%) during the period of neutropenia. Complications of patients are shown in Table IV.

### Engraftment

Patients achieved an absolute neutrophil count of  $500/\mu l$  at a median of 24 days after ABMT (range 18-31 days). A platelet count of  $50,000/\mu l$  was achieved at median 37 days (range 32-43). A comparable number of nucleated bone marrow cells ( $3.6 \times 10^8$ ) were infused into patients, (range  $1.8-5.2 \times 10^8$ ). No patient required a "back up" marrow infusion. No patient had failure of marrow engraftment. The hematologic recovery of the patients is shown in Table I.

### Evaluation

Patients were clinically re-staged at the time of entry to the protocol. An attempt was made to biopsy any readily accessible tissue at this time. Organ function was evaluated

## Marrow Transplantation in Resistant Hodgkin's Disease

TABLE VII: Published results from 8 ABMT Series

First Author and Reference No.	Year Published	Median Age-Years (range)	Median Follow-Up (months)	No. of Patients in Study	%CR	% Death Due to Complications	%3-Year DFS for CRs
ABMT (N=268)							
Gribben <sup>32</sup>	1989	29(18-34)	<36	44	48	5	90
Carella <sup>17</sup>	1988	27(12-45)	NR	50	46	4	45
Jagannath <sup>33</sup>	1989	28(15-56)	34	59	46	7	40
Phillips <sup>19</sup>	1989	30(15-57)	42	26	69	23	65
Jones <sup>34</sup>	1990	26(11-55)	26	28	64	21	71
Yahalom <sup>35</sup>	1989	27(20-43)	36	17	71	24	92
Zulian <sup>36</sup>	1989	28(15-51)	<18	20	46	18	†
Bonadonna <sup>37</sup>	1991	NR	<36	24	79	0	50
Average		28	35	34	59	13	65
Weighted average					55	10	61

Abbreviations: NR, not reported, DFS: disease-free survival

†Unable to report because some patients were in CR at the time of ABMT.

by a routine serum chemistry panel, creatinine clearance and other tests of renal function. Restaging procedures were repeated at day+30 and again at day+100 after ABMT if no obvious progression had occurred. Routine tumor staging studies were repeated every 2 months for the first year, then every 3-4 months, unless symptoms of disease recurred.

Patients who survived to at least day+30 and had no evidence of tumor by clinical, biochemical, radiologic, or isotopic evaluation for at least one month's duration were classified as having a complete remission (CR). Patients with greater than 80% reduction of tumor radiographically and who had no progression for one year were upgraded to CR status.

### RESULTS

All six patients achieved CR, and three of six patients remained in CR for 18, 17, and 15 months. (the time of last evaluation is 1/1/1993). Two patients relapsed from CR, at 7 months (patient 1) and 8 months (patient 6) after ABMT and subsequently died of progressive disease after 4 and 2 months of relapse. Patient number 6 had been heavily pretreated with multiple chemotherapy drugs and palliative mediastinal and spine radiation 5 months before entry to this study, and no conventional cytoreduction therapy had

been given before CVB & ABMT. The results are summarized in Table VI.

Both patients relapsed at sites of previous disease. New sites of disease involvement were not seen after ABMT, and progressive disease that occurred did so at previously involved sites. In particular, no patients developed bone marrow involvement after ABMT. One patient died of pulmonary infection six months after ABMT, who was in CR and had no evidence of relapse one month before the time of death. He died in another city, autopsy was not performed, and the cause of death remains unknown. The remaining patients continue being in remission at 18, 17, and 15 months and have a Karnofsky performance status score of 100%. Overall survival with complete remission is shown in Fig. 1. These three cases include patient number 2 and 3 who had previously failed radiation therapy and two different chemotherapy regimens (MOPP, ABVD) and BCNU. The third case (patient number 5) had failed MOPP and MOPP/ABVD regimens. Overall survival is shown in Fig. 2.

### DISCUSSION

High-dose combination chemotherapy with ABMT when necessary achieved a complete remission rate of approximately 50% in a group of heavily pretreated patients



with active Hodgkin's disease. Only two patients who achieved a complete remission have relapsed at the time this article was written. Although reports from other groups have given comparable results<sup>17,37</sup>, the results of some reports are shown in Table VII.

This study has been performed with unpurged autologous bone marrow, which may result in re-infusion of residual disease, contaminating the harvested bone marrow, but not detected by routine histology. However, there is a low incidence of overt bone marrow involvement in Hodgkin's disease.<sup>38,39</sup> The pattern of disease progression in our relapsed two patients is clearly owing to failure of eradication of existing disease rather than re-infusion of tumor cells at the time of ABMT. To date we have no evidence to suggest that purging of autologous bone marrow is necessary in the treatment of Hodgkin's disease. Furthermore, it would be difficult to demonstrate any benefit from this procedure until there are advances in eradication of existing disease.

The identification of patients who would benefit from intensive treatment of this nature at an earlier stage in their disease is difficult. Patients who have primary resistant disease or who have failed any two modalities of therapy (radiotherapy and chemotherapy) should be considered candidates for this approach, but before the adverse features of advanced extensively treated malignancy are manifest. The best time for its use remains to be determined.

Although our observation is limited by small patient numbers, the results of this study and other reported studies demonstrates the potential value of ABMT in the treatment of refractory Hodgkin's disease.

All patients in this study had active Hodgkin's disease resistant to standard regimens of therapy at standard dosage at the time of ABMT. However, this is not an unselected group of patients. These patients had clearly been selected by their referring physicians. In fact, this is a problem of all non-randomized studies undertaken in referral centers for bone marrow transplantation.

Since the goal of these treatments is long-term disease-free survival, follow-up to 5 years is required to allow firm conclusions to be made.

Clearly, the strategy of using autologous BMT regimens to treat Hodgkin's disease patients who are otherwise incurable with conventional chemotherapy is now a fully accepted technique. Further efforts to refine this technique should be useful in curing an increasing number of such patients.

#### ACKNOWLEDGEMENT

I gratefully acknowledge Dr. M. Ghanei, Dr. H. Imami and Dr. F. Makareian for their assistance, and the skills of the Nursing and Anesthesiology staff of the Bone Marrow Transplantation Unit in Seyyed-al-Shohada Hospital, Isfahan.

#### REFERENCES

1. Phillips GL, Reece DE: Clinical studies of autologous bone marrow transplantation in Hodgkin's disease. *Clin Haematol* 15: 151-16, 1986.
2. Armitage JO: Autologous bone marrow transplantation for patients with relapsed Hodgkin's disease. *Amer J Med* 91: 605-11, 1991.
3. DeVita VT, Serpick AA, Carbone PP: Combination chemotherapy in the treatment of advanced Hodgkin's disease. *Ann Intern Med* 73: 881-5, 1970.
4. De Vita VT, Simon RM, Hubbard SM, et al: Curability of advanced Hodgkin's disease with chemotherapy. Long term follow up of MOPP-treated patients at National Cancer Institute. *Ann Intern Med*; 92: 587-95, 1980.
5. Case DC, Young CW, Lee BJ: Combination chemotherapy of MOPP-resistant Hodgkin's disease with adriamycin, bleomycin, dacarbazine and vinblastine (ABVD). *Cancer* 39: 1382-6, 1977.
6. Papa G, Mandelli F, Anselmo AP, et al: Treatment of MOPP-resistant Hodgkin's disease with adriamycin, bleomycin, vinblastine and dacarbazine (ABVD). *Eur J Cancer Oncol* 18: 803-6, 1982.
7. Clamon GH, Corder MP: ABVD treatment of MOPP failure in Hodgkin's disease: a re-examination of goals of salvage therapy. *Cancer Treat Rep* 1978; 62: 363-7, 1978.
8. Tseg A Jr, Jacobs C, Coleman C, et al: A pilot study utilizing CCNU, VP-16 and methotrexate as third-line therapy for recurrent Hodgkin's disease [abstract]. *Proc Am Soc Clin Oncol* 5: 204a 1985.
9. Fox RA, Lippman SM, Caddady JR, et al: Radiation therapy salvage of Hodgkin's disease following chemotherapy failure. *J Clin Oncol* 5: 38-45, 1987.
10. Fisher RI, De Vita VT, Hubbard SP, et al: Prolonged disease-free survival in Hodgkin's disease with MOPP reinduction after first relapse. *Ann Intern Med* 90: 761-3, 1979.
11. Longo DL, Duffey PL, et al: Conventional-dose salvage combination chemotherapy in patients relapsing with Hodgkin's disease after combination chemotherapy: The low probability for cure. *J Clin Oncol* 10(2): 210-8, 1992.
12. Piga A, Ambrosetti A, Todeschini G, et al: Doxorubicin, bleomycin, vinblastine, and dacarbazine (ABVD) salvage of mechlorethamine, vincristine, prednisone, and procarbazine (MOPP)-resistant advanced Hodgkin's disease. *Cancer Treat Rep* 68: 947-51, 1984.
13. Tannir N, Hagemester F, Vellekoop L, et al: MIME: A new effective third-line combination chemotherapy for patients with recurrent Hodgkin's disease. *Proc Am Soc Clin Oncol* 3: 245, 1984.
14. Appelbaum FR, Sullivan KM, Thomas ED, et al: Allogeneic marrow transplantation in the treatment of MOPP-resistant Hodgkin's disease. *J Clin Oncol* 3(11): 1490-94, 1985.
15. Phillips GL, Shepherd JD, et al: Busulfan, cyclophosphamide, and melphalan conditioning for autologous bone marrow transplantation in hematologic malignancy. *J Clin Oncol* 9(10): 1880-8, 1991.
16. Jagannth S, Dick KA, Armitage JO, et al.: High-dose cyclophosphamide, carmustine and etoposide and autologous bone marrow transplantation for relapsed Hodgkin's disease. *Ann Intern Med* 104: 163-8, 1986.

## Marrow Transplantation in Resistant Hodgkin's Disease

17. Carella AM, Congiu AM, Gaozza E, et al: High-dose chemotherapy with autologous bone marrow transplantation in 50 advanced resistant Hodgkin's disease patients. *J Clin Oncol* 6: 1411-6, 1988.
18. Philip T, Dumont J, Teillet F, et al: High-dose chemotherapy and autologous bone marrow transplantation in refractory Hodgkin's disease. *Br J Cancer* 53: 737-42, 1986.
19. Phillips GL, Wolff SN, Herzig RH, et al: Treatment of progressive Hodgkin's disease with intensive chemotherapy and autologous bone marrow transplantation. *Blood* 73: 2086-92, 1989.
20. Reece D, Barnett M, Connors J, et al: Augmented cyclophosphamide (C), BCNU (B), and etoposide (V)=CBV and autologous bone marrow transplantation (ABMT) for progressive Hodgkin's disease. *Blood* 72: 402 a, 1989.
21. Rosenfeld CS, Ka DP, Terry L, et al: Autologous bone marrow transplantation following high-dose busulfan VP-16 for advanced non-Hodgkin's lymphoma and Hodgkin's disease. *Exp Hematol* 19: 317-321, 1991.
22. Thomas ED: Marrow transplantation for malignant disease (Karnofsky)
23. Jagannath S, Armitage JO, Dicke KA, et al: Prognostic factor for response and survival after high-dose cyclophosphamide, carmustine, and etoposide with autologous bone marrow transplantation for relapsed Hodgkin's disease. *J Clin Oncol* 7: 179-185, 1989.
24. Vose JM, Bierman PJ, Anderson JR, Armitage JO, et al: Progressive disease after high-dose therapy and autologous transplantation for lymphoid malignancy: Clinical course and patient follow-up. *Blood*, 80(8): 2142-8, 1992.
25. Reece DE, Barnet MJ, Joseph M, et al: Intensive chemotherapy with cyclophosphamide, carmustine and etoposide followed by autologous bone marrow transplantation for relapsed Hodgkin's disease. *J Clin Oncol* 9(10): 1871-9, 1991.
26. Appelbaum FR, Sullivan KM, et al: Treatment of malignant lymphoma in 100 patients with chemotherapy, total body irradiation, and marrow transplantation. *J Clin Oncol* 5: 1340, 1987.
27. Blume KG, Foraman SJ: High-dose busulfan/etoposide as a preparatory regimen for second bone marrow transplantation in hematologic malignancies. *Blut* 55: 49, 1987.
28. Buckner CD, Clift RA, Sander JE, et al: Marrow harvesting from normal donors. *Blood* 64(3): 630-4, 1984.
29. Thomas ED, Storb R: Technique for human marrow grafting. *Blood* 36: 507, 1970.
30. Jin NR, Hill RS, et al: Marrow harvesting for autologous marrow transplantation. *Exp Hematol* 13: 879-84, 1985.
31. Lim SH, Baglin TP, et al: High-dose mitoxantrone-an etoposide conditioning in autologous bone marrow transplantation for relapsed Hodgkin's disease. *Eur J Haematol* 48: 110-4, 1992.
32. Gribben JG, Linch DC, Singer CRJ, et al: Successful treatment of refractory Hodgkin's disease by high-dose combination chemotherapy and autologous bone marrow transplantation. *Blood* 73: 390-4, 1989.
33. Philip T, Biron P: Role of high-dose chemotherapy and autologous bone marrow transplantation in the treatment of lymphoma. *Eur J Cancer*. 27(3): 320-2, 1991.
34. Jones RJ, Piantadosi S, Mann RB, et al: High-dose cytotoxic therapy and bone marrow transplantation for relapsed Hodgkin's disease. *J Clin Oncol* 8(3): 527-37, 1990.
35. Yahalom J, Gulati S, Shank B, et al: Total lymphoid irradiation, high-dose chemotherapy and autologous bone marrow transplantation for chemotherapy-resistant Hodgkin's disease. *Int J Radiat Oncol Biol Phys* 17: 915-22, 1989.
36. Zulian GB, Selby P, Milan S, et al: High-dose melphalan BCNU and etoposide with autologous bone marrow transplantation for Hodgkin's disease. *Br J Cancer* 59: 631-5, 1989.
37. Bonadonna G, Santoro A, Gianni AM, et al: Primary and salvage chemotherapy in advanced Hodgkin's disease.
38. Bartl R, Frisch B, Burchhardt T, et al: Assessment of bone marrow histology in Hodgkin's disease correlation with clinical factors. *Br J Haematol* 51: 345, 1982.
39. MacIntyre EA, Vaughan Hudson B, et al: The value of staging marrow trephine biopsy in Hodgkin's disease. *Eur J Haematol* 39: 66, 1987.
40. Rapoport AP, Rowe JM, et al: Treatment of relapsed or refractory Hodgkin's disease and non-Hodgkin lymphoma with high-dose chemoradiotherapy followed by unstimulated autologous peripheral stem cell rescue. *Amer J Hematol* 40: 86-92, 1992.
41. Copelan EA, Deeg HJ: Conditioning for allogeneic marrow transplantation in patients with lymphohematopoietic malignancies without the use of total body irradiation. *Blood* 80(7): 1648-58, 1992.
42. Desch CE, Lasala MR, Thomas J, Hillner BE: The optimal timing of autologous bone marrow transplantation in Hodgkin's disease patients after a chemotherapy relapse. *J Clin Oncol* 10(2): 200-9, 1992.



## Marrow Transplantation in Resistant Hodgkin's Disease

17. Carella AM, Congiu AM, Gaozza E, et al: High-dose chemotherapy with autologous bone marrow transplantation in 50 advanced resistant Hodgkin's disease patients. *J Clin Oncol* 6: 1411-6, 1988.
18. Philip T, Dumont J, Teillet F, et al: High-dose chemotherapy and autologous bone marrow transplantation in refractory Hodgkin's disease. *Br J Cancer* 53: 737-42, 1986.
19. Phillips GL, Wolff SN, Herzig RH, et al: Treatment of progressive Hodgkin's disease with intensive chemotherapy and autologous bone marrow transplantation. *Blood* 73: 2086-92, 1989.
20. Reece D, Barnett M, Connors J, et al: Augmented cyclophosphamide (C), BCNU (B), and etoposide (V)=CBV and autologous bone marrow transplantation (ABMT) for progressive Hodgkin's disease. *Blood* 72: 402 a, 1989.
21. Rosenfeld CS, Ka DP, Terry L, et al: Autologous bone marrow transplantation following high-dose busulfan VP-16 for advanced non-Hodgkin's lymphoma and Hodgkin's disease. *Exp Hematol* 19: 317-321, 1991.
22. Thomas ED: Marrow transplantation for malignant disease (Karnofsky)
23. Jagannath S, Armitage JO, Dicke KA, et al: Prognostic factor for response and survival after high-dose cyclophosphamide, carmustine, and etoposide with autologous bone marrow transplantation for relapsed Hodgkin's disease. *J Clin Oncol* 7: 179-185, 1989.
24. Vose JM, Bierman PJ, Anderson JR, Armitage JO, et al: Progressive disease after high-dose therapy and autologous transplantation for lymphoid malignancy: Clinical course and patient follow-up. *Blood*, 80(8): 2142-8, 1992.
25. Reece DE, Barnet MJ, Joseph M, et al: Intensive chemotherapy with cyclophosphamide, carmustine and etoposide followed by autologous bone marrow transplantation for relapsed Hodgkin's disease. *J Clin Oncol* 9(10): 1871-9, 1991.
26. Appelbaum FR, Sullivan KM, et al: Treatment of malignant lymphoma in 100 patients with chemotherapy, total body irradiation, and marrow transplantation. *J Clin Oncol* 5: 1340, 1987.
27. Blume KG, Foraman SJ: High-dose busulfan/etoposide as a preparatory regimen for second bone marrow transplantation in hematologic malignancies. *Blut* 55: 49, 1987.
28. Buckner CD, Clift RA, Sander JE, et al: Marrow harvesting from normal donors. *Blood* 64(3): 630-4, 1984.
29. Thomas ED, Storb R: Technique for human marrow grafting. *Blood* 36: 507, 1970.
30. Jin NR, Hill RS, et al: Marrow harvesting for autologous marrow transplantation. *Exp Hematol* 13: 879-84, 1985.
31. Lim SH, Baglin TP, et al: High-dose mitoxantrone-an etoposide conditioning in autologous bone marrow transplantation for relapsed Hodgkin's disease. *Eur J Haematol* 48: 110-4, 1992.
32. Gribben JG, Linch DC, Singer CRJ, et al: Successful treatment of refractory Hodgkin's disease by high-dose combination chemotherapy and autologous bone marrow transplantation. *Blood* 73: 390-4, 1989.
33. Philip T, Biron P: Role of high-dose chemotherapy and autologous bone marrow transplantation in the treatment of lymphoma. *Eur J Cancer*. 27(3): 320-2, 1991.
34. Jones RJ, Piantadosi S, Mann RB, et al: High-dose cytotoxic therapy and bone marrow transplantation for relapsed Hodgkin's disease. *J Clin Oncol* 8(3): 527-37, 1990.
35. Yahalom J, Gulati S, Shank B, et al: Total lymphoid irradiation, high-dose chemotherapy and autologous bone marrow transplantation for chemotherapy-resistant Hodgkin's disease. *Int J Radiat Oncol Biol Phys* 17: 915-22, 1989.
36. Zulfian GB, Selby P, Milan S, et al: High-dose melphalan BCNU and etoposide with autologous bone marrow transplantation for Hodgkin's disease. *Br J Cancer* 59: 631-5, 1989.
37. Bonadonna G, Santoro A, Gianni AM, et al: Primary and salvage chemotherapy in advanced Hodgkin's disease.
38. Bartl R, Frisch B, Burchhardt T, et al: Assessment of bone marrow histology in Hodgkin's disease correlation with clinical factors. *Br J Haematol* 51: 345, 1982.
39. MacIntyre EA, Vaughan Hudson B, et al: The value of staging marrow trephine biopsy in Hodgkin's disease. *Eur J Haematol* 39: 66, 1987.
40. Rapoport AP, Rowe JM, et al: Treatment of relapsed or refractory Hodgkin's disease and non-Hodgkin lymphoma with high-dose chemoradiotherapy followed by unstimulated autologous peripheral stem cell rescue. *Amer J Hematol* 40: 86-92, 1992.
41. Copelan EA, Deeg HJ: Conditioning for allogeneic marrow transplantation in patients with lymphohematopoietic malignancies without the use of total body irradiation. *Blood* 80(7): 1648-58, 1992.
42. Desch CE, Lasala MR, Thomas J, Hillner BE: The optimal timing of autologous bone marrow transplantation in Hodgkin's disease patients after a chemotherapy relapse. *J Clin Oncol* 10(2): 200-9, 1992.