

## DIFFUSE ARTERIAL ECTASIA IN MARFAN SYNDROME

MOHAMMAD J. HASHEMI, M.D., AND ALI ANDON  
PETROSSIANS, M.D.

*From the Shahid Rajai Heart Hospital and Cardiovascular Research Center, Iran University of Medical  
Sciences, Tehran, Islamic Republic of Iran.*

### ABSTRACT

A 22 year old male referred with palpitation. General appearance and physical exam impressed us in that the patient has Marfan syndrome. Cardiac catheterization showed diffuse arterial ectasia. We found no previous report of this generalized diffuse ectasia.

*MJIRI, Vol. 8, No. 1, 63-64, 1994.*

**Keywords:** Marfan syndrome, diffuse arterial ectasia

### CASE REPORT

A 22 year old male referred with dyspnea and palpitation. He complained of these symptoms for three years, which had gradually worsened. On admission the patient was in New York Heart Association functional class II. Physical examination revealed a slender man not in acute distress with height: 187cm, weight 68kg, heart rate 70/min and blood pressure, 140/45. ENT exam showed mild high arch palate. Lungs were normal. Heart sounds were normal, with diastolic blowing murmur with maximal intensity at the left second intercostal space radiating to the axilla and an ejection systolic murmur of grade II/VI at the same area. Liver was palpated 2cm below right costal margin. Extremities revealed long fingers, narrow palms and upper segment to lower segment ratio of 0.65.

During clenching the hand around a fixed thumb, the thumb protruded past the ulnar side. Electrocardiography showed normal sinus rhythm, and no signs of atrial or ventricular enlargement. CXR showed moderate cardiomegaly with left ventricular dominance. Two dimensional echocardiography revealed normal left atrium: 2.50cm, LVEDD: 6.0cm, LVESD: 4.5cm, RVID: 2.00cm.

Correspondence: Ali Andon Petrossians, Fellowship of Cardiology, Mohammad Jafar Hashemi, Assistant Professor of Cardiology, Cardiovascular Research Center, P.O. Box: 15745-153 Tehran-Iran Fax (98-21) - 292023

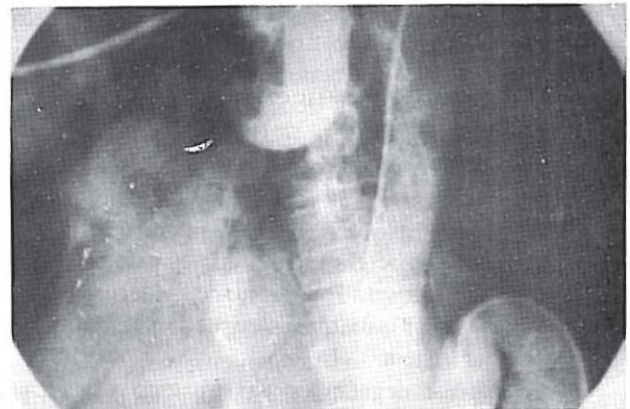

Fig. 1. Abdominal and thoracic aorta are tortuous and deformed.

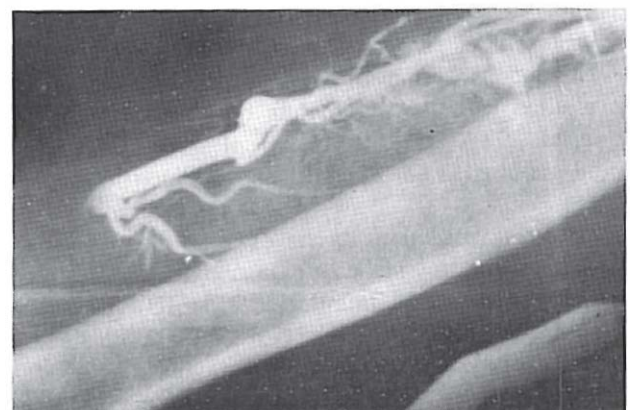


Fig. 2. Ectasia of upper extremity arteries.

## Diffuse Arterial Ectasia

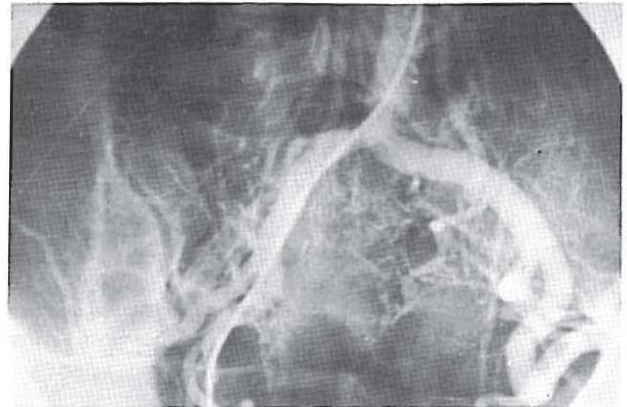
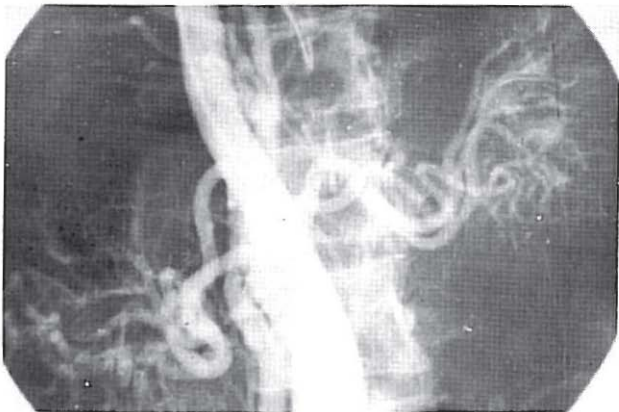


Fig. 3. Diffuse ectasia at A, renal, and B, lower extremity arterial level.

IVS: 0.8cm. Aorta was dilated with a diameter of 5.00cm. Doppler proved aortic regurgitation. Catheterization for this patient was performed in two consecutive sessions, once by Judkins and the second time by Sones technique, but we were not able to reach the aortic arch at either time due to excessive tortuosity at different levels from the abdominal aorta upward (Fig. 1). There was also severe ectasia at the level of the forearms (Fig. 2) and at the renal and lower extremity level (Fig. 3, A,B).

### DISCUSSION

Diagnosis of Marfan syndrome is made by general features and physical exam.<sup>1</sup> The cardiovascular system<sup>2</sup> is also frequently involved. Aortic regurgitation is a consequence of aortic dissection, dilated aortic root, or prolapse of aortic cusps. There is marked degeneration of aortic media<sup>3-5</sup> which is the characteristic abnormality of the cardiovascular system.<sup>1</sup>

In this rare case, degeneration was so extensive that it had deformed the entire aortic trunk, with degeneration extending

to the peripheral arteries to involve the subclavian, radial, renal and all other peripheral arteries, inducing diffuse ectasia.

### REFERENCES

1. Baer R, Taussig PB, Oppenheimer EH: Congenital aneurysmal dilatation of the aorta associated with arachnodactyly. *Bull Johns Hopkins Hosp* 72: 309-18, 1942.
2. Erdheim J: Medionecrosis aortae idiopathica cystica. *Virchows Arch [B]* 276: 187-229, 1930.
3. McKusick VA: The cardiovascular aspects of Marfan's syndrome: A heritable disorder of connective tissue. *Circulation* 11: 321-42, 1955.
4. Marvel RJ, Genovese, PD: Cardiovascular disease in Marfan syndrome. *Am Heart J* 42: 814-823, 1951.
5. Pyeritz RE, McKusick VA: The Marfan syndrome: diagnosis and management. *N Engl J Med* 300: 772-7, 1979.
6. Wagenvoort CA, Neufeld HN, Edwards JE: Cardiovascular system in Marfan syndrome and in idiopathic dilatation of the ascending aorta. *Am J Cardiol* 9: 496-507, 1962.