

REGRESSION OF METASTATIC NEUROBLASTOMA TO GANGLIONEUROMA

SHARIAR DABIRI, M.D.*,
SEYYED REZA SHARIFI, M.D.***

*From the Departments of *Pathology, **Radiology, and ***Orthopedics, Kerman University of Medical Sciences, Kerman, Islamic Republic of Iran.*

ABSTRACT

The spontaneous regression of neuroblastoma to ganglioneuroma is a rare occurrence. Reviewing the literature, we found no more than 12 cases reported.^{1,2,9,10,14,15} We report a case of metastatic neuroblastoma of multifocal skeletal and soft tissue areas with gross deformities which regressed to ganglioneuroma, with good prognosis. *MJIRI, Vol. 7, No. 3, 211-214, 1993.*

Keywords: Neuroblastoma, ganglioneuroma, nerve growth factors.

INTRODUCTION

Neuroblastoma is a malignant tumor of the neuroblasts as primary adrenal or extra-adrenal tissue, most of which appear during the first three years of life. It accounts for about 5-8% of pediatric cancers in Kerman, according to Cancer Registry Center reports.¹¹

Regression could occur as complete disappearance of the tumor or maturation to a benign form. Spontaneous regression is rare, occurring in 1-2% of cases. However, this lesion has the highest rate of spontaneous regression of any human cancer.¹⁶

Neuroblastoma has long been cited as the prime example of a tumor that can undergo spontaneous regression. The comprehensive monograph by Verson and Cole⁸ includes 29 case reports of neuroblastoma patients considered to have had true spontaneous regression. These 29 cases form a considerable proportion (17%) of the total 176 patients included in the monograph. Considering the low incidence of neuroblastoma in the population, approximately 3 per million,¹⁷ it is striking that 17% of the reported cases of spontaneous regression occur in this tumor. This fact suggests that neuroblastoma has unique characteristics. One of these is the ability to mature into a benign tumor. Although most instances of regression lead to complete disappearance of all evidence of the tumor, there are cases, documented by histologic examination, known as malignant neuroblastoma regressing to benign ganglioneuroma.^{6,8}

We report a patient with neuroblastoma who received no medication and had long-term survival (eight years). Multiple skeletal deformities developed with differentiation to the mature ganglioneuroma.

CASE REPORT

A 10-year-old boy from Kerman presented with multiple skull tumors and a chest wall kyphotic mass for several

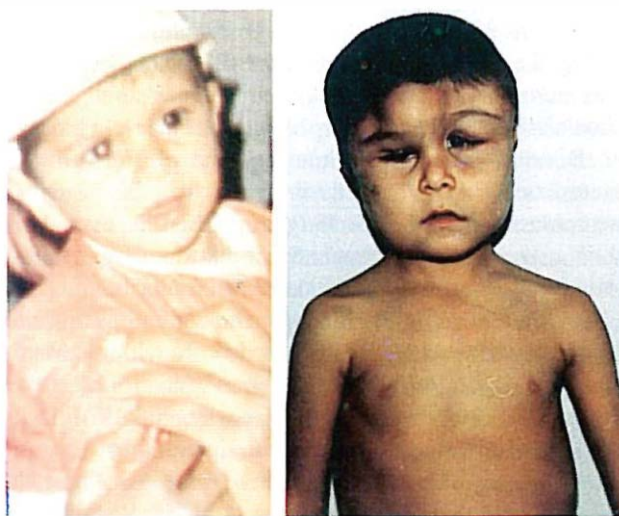

Fig. 1. Comparing photographs of the patient at 1.5 and 10 years shows developing skull-bulging deformities.

Regression of Neuroblastoma

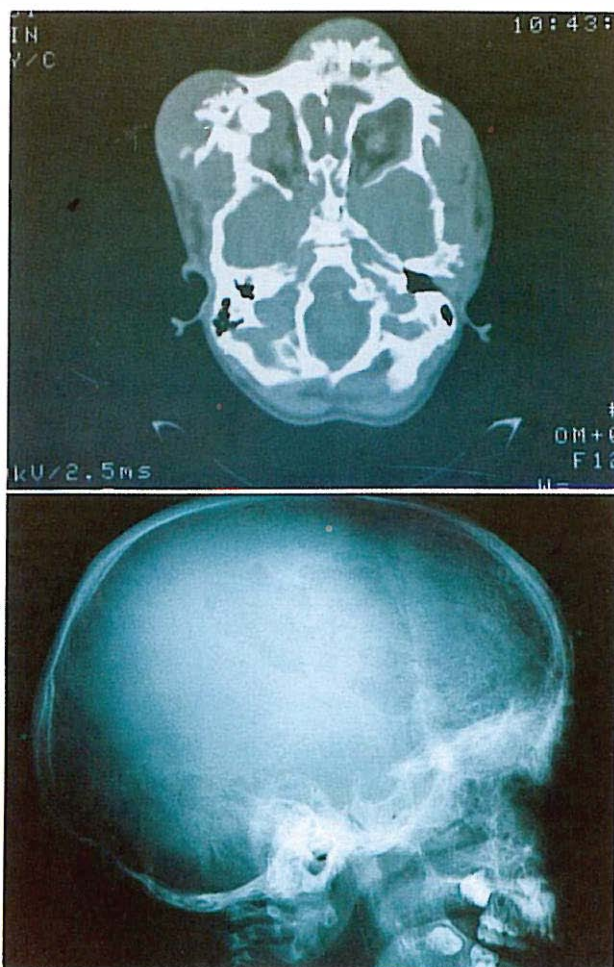


Fig. 2. Skull x-rays and C.T. scans show sunburst appearance of the fronto-orbital bones.

years. Reviewing his history showed that eight years ago he developed fever and abdominal swelling. Paraclinical work-up were Hb 12 g/dL; WBC 8000/mm³ (lymphocytes 55%, neutrophils 38%, monocytes 5%, eosinophils 2%); F.B.S. 80 mg/dL; urea 30 mg/dL; creatinine 0.5 mg/dL. Urinalysis was normal. Urinary V.M.A. was not measured. I.V.P. showed slight downward displacement of the right kidney.

Bone marrow aspiration revealed clusters of the metastatic round blue cells with the final diagnosis of neuroblastoma. He was discharged upon his father's consent without any medical treatment. Since that time, he gradually developed deformities of the skull with frontal bulgings, a chest wall mass, and difficulty in walking. Routine laboratory tests on his final admission are within normal limits: Hb 13.2 g/dL; WBC 8500 mm³, (neutrophil 60%, lymphocytes 30%, monocytes 8%, eosinophils 2%) F.B.S. 80 mg/dL; urea 28 mg/dL; urinary V.M.A. and chromosomal karyotyping were not performed (Fig. 1).

X-ray findings on lateral view of the skull showed a destructive process with sunburst appearance with narrow transitional zone in frontal and parietal bones and floor of

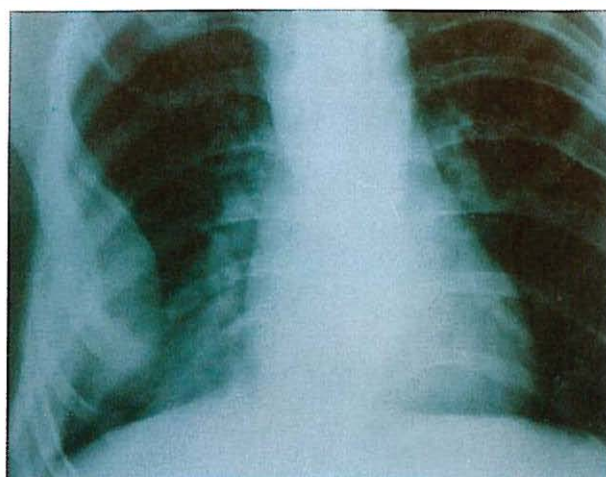


Fig. 3. Chest x-ray shows a solid mass of the soft tissue of the right thorax with rib deformities.

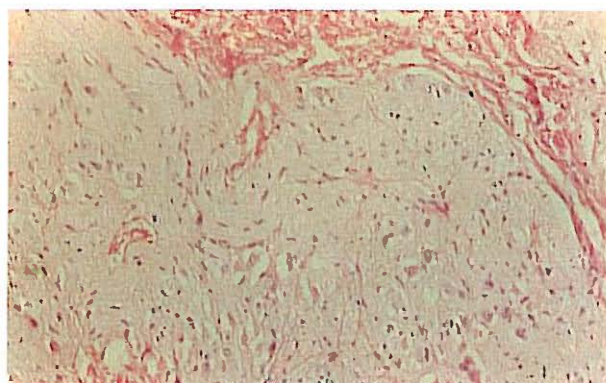


Fig. 4. Sections of the soft tissue mass of the thorax show benign wavy neural tumor cells with dispersed ganglion cells.

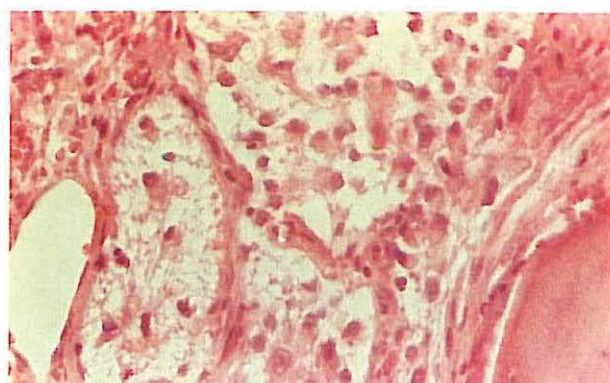


Fig. 5. Sections of the iliac bone biopsy show marrow spaces and spongy bone trabeculae which are separated by ganglioneuromatous elements.

anterior fossa and soft tissue mass. These findings were confirmed by C.T. scan (Fig. 2). Chest x-ray shows expansile and destructive lesion with narrow transitional zone and mild sclerotic borders in anterior aspect of right 4th and left 8th rib in axillary line with soft tissue mass (Fig.

3). Both forearm and arm roentgenograms showed destructive and expansile lesions with narrow transitional zone in the distal humerus, proximal radius and ulna.

Section of biopsy from posterior chest wall mass showed benign proliferation of the neural elements with wavy background. Between them mature ganglion cells were seen. Bone marrow biopsy of the left iliac lytic lesion also reveals normocellular marrow with adequate blood precursor cells. Between mature spongy and marrow spaces, there were bundles of hyperplastic neural fibers overgrowth which were intermingled with mature ganglion cells. These patterns were most prominent perivascularly. There was no evidence of neuroblastoma (Fig. 5).

DISCUSSION

Neuroblastoma arises from the adrenal medulla and the sympathetic ganglia of the autonomic nervous system. It is common in children under three years of age and more than half occur under one year. It is the most common human neoplasm to undergo spontaneous regression which occurs by necrosis or maturation to ganglioneuroma.³

Modern therapy has little impact on survival. It is strikingly dependent on age according to "Bolande classification" which classified two year survival according to the age of onset; neonatal, 1 yr, 2 yr, 4 yr, which are 62-70%, 35%, 19%, and 5%, respectively.³

Neuroblastoma is one of the most common malignant neurogenic tumors in the retroperitoneum, occurring almost

exclusively in children. Extra-adrenal tumors are approximately half as frequent as those of adrenal origin. Generally solitary, they may be multiple with as many as six retroperitoneal tumors having been observed.¹⁵

Spontaneous differentiation, purported to be more in the pelvic, retroperitoneal and cervical-thoracic tumors, occurs in primary and metastatic sites.¹⁵

Mediastinal neuroblastomas usually produce symptoms and signs. In some series survival figures are better than for abdominal neuroblastoma. The prognosis gradually worsens with increasing age of the patients.¹⁵

In situ neuroblastoma describes small nodules indistinguishable from neuroblastoma found incidentally at autopsy in the adrenal glands of up to 1% of infants less than three months old. The frequency of these neuroblastomas has been cited as further evidence for the inherent tendency of neuroblastoma to regress.³

The prognosis is generally grave, with metastases occurring frequently to one or more sites, and bone, regional nodes, liver, skull, and lungs being most frequent. Patient age, tumor differentiation, extent of involvement, and primary tumor location influence the prognosis. It is better in younger children and in tumors of the pelvis and retroperitoneum than in those of the adrenal.¹⁵

Although the possibility of maturation of a "neuroblastoma" into a "ganglioneuroma" is one of the most debated and most intriguing features of this tumor, the actual number of cases in which this transition has been demonstrated is disappointingly small.^{1,2,7-10,14,16}

The cause of spontaneous maturation remains obscure. However, Hellstron et al.^{12,13} found that lymphocytes from children with neuroblastoma inhibit the formation of colonies of neuroblastoma cells in culture, but not normal fibroblasts or cells derived from other tumor types. Indeed, lymphocytes from all patients with neuroblastoma are cytotoxic to cultures of any neuroblastoma tumor and this effect is not related to the extent of disease. The lymphocytes of the mothers of neuroblastoma patients are cytotoxic to the same tumor culture, too. Also, the presence of blocking factors reflects the response of the patient with decreasing levels after removal of the primary tumor and increasing amounts in patients with progressive disease. The presence of these factors may be one mechanism whereby tumors can grow despite a normal cell mediated reaction to the tumor. Thus the better survival observed in infants could be explained by an efficient immune response.⁸

Maturation of neuroblastoma to ganglioneuroma may also depend on host environmental factors. Various agents have been shown to alter the proliferative rate of human neuroblastoma cells in culture and to produce morphologic changes indicative of differentiation,^{4,9} among them nerve growth factor (NGF), a protein isolated from the murine submaxillary gland as a dimer of molecular weight 26,000 daltons. It is possible that progressive differentiation of

Table I. International staging system for neuroblastoma

Stage 1: Localized tumor confined to the area of origin: complete gross excision, with or without microscopic residual disease: identifiable ipsilateral and contralateral lymph nodes negative microscopically.
Stage 2A: Unilateral tumor with incomplete gross excision: identifiable ipsilateral and contralateral lymph nodes negative microscopically.
Stage 2B: Unilateral tumor with complete or incomplete gross excision: with positive ipsilateral regional lymph nodes: identifiable contralateral lymph nodes negative microscopically.
Stage 3: Tumor infiltrating across the midline with or without regional lymph node involvement; or unilateral tumor with contralateral regional lymph node involvement; or, midline tumor with bilateral lymph node involvement.
Stage 4: Dissemination of tumor to distant lymph nodes, bone, bone marrow, liver, and/or other organs (except as defined in stage 4s).
Stage 4s: Localized primary tumor as defined for stage 1 or 2 with dissemination limited to liver, skin, and/or bone marrow.

Regression of Neuroblastoma

neuroblastoma results from high levels of NGF, or that regression of undifferentiated neuroblastoma is the consequence of a decline in NGF.⁹

The responses of partially-differentiated neuroblastoma and ganglioneuroblastoma to NGF have not been investigated. Furthermore, circulating levels of NGF in children with and without neuroblastoma have not yet been properly measured, in part because of lack of appropriate standardized assays.

Investigation of the role of NGF in spontaneous differentiation of neuroblastoma may provide useful insights into the management of the disease by promotion of cytodifferentiation.⁸

In conclusion, the regressive changes of cytomaturation and improved biological behavior of the neuroblastoma may be a reflection of growth factor releasing and/or immune surveillance overactivities.

REFERENCES

1. Aterman K, et al: Maturation of neuroblastoma to ganglioneuroma. *Am J Dis Child* 20: 217-22, 1970.
2. Bass D, et al: Complete pathologic maturation and regression of stage IVs neuroblastoma without treatment. *Cancer* 62: 818-25, 1988.
3. Berry PJ: Pediatric solid tumor. *Recent Advances in Histopathology* 3: 216-220, 1987.
4. Bottenstein JE: Differentiated properties of neuronal cell lines. In: Sato GH(ed). *Functionally Differentiated Cell Lines*. New York: Alan R. Liss, Inc. 155-84, 1981.
5. Broderur GM, et al: International criteria for diagnosis, staging and response to treatment in patients with neuroblastoma. *J Clin Oncol* 16(12): 1874-81, 1988.
6. Cushing H, Wolbach SB: The transformation of a malignant paravertebral sympatheticoblastoma into a benign ganglioneuroma. *Am J Pathol* 3: 203-16, 1927.
7. Dyke PC, Mulkey DA: Maturation of ganglioneuroblastoma. *Cancer* 20: 1349, 1967.
8. Evans AE, et al: Spontaneous regression of neuroblastoma. *Natl Cancer Inst Monogr* 44: 54, 1976.
9. Garvin GH, et al: Ganglioneuroma presenting with differentiated skeletal metastases. *Cancer* 54: 357-60, 1984.
10. Griffin ME, et al: Familial neuroblastoma with regression and maturation to ganglioneurofibroma. *Pediatrics* 43: 377-82, 1969.
11. Gupta, PK, Tabrizchee H: Pattern of malignant tumors in Kerman province. *Med J Islam Republ Iran* 5(3,4):91-5, 1991.
12. Hellstron I, et al: Studies on cellular immunity to human neuroblastoma cells. *Int J Cancer* 6: 172-88, 1970.
13. Hellstron I, et al: Demonstration of cell-bound and human immunity against neuroblastoma cells. *Proc Natl Acad Sci* 60: 1231-8, 1968.
14. McLaughlin JE, Urich H: Maturing neuroblastoma and ganglioneuroblastoma: study of four cases with long survival. *J Pathol* 121: 19-26, 1977.
15. Silverberg SG: *Principles and Practice of Surgical Pathology*, London: Churchill Livingstone, 965, 998-9, 1990.
16. Sitarz AL, et al: Complete maturation of neuroblastoma with bone metastases. *J Pediatr Surg* 10(4): 533-6, 1975.
17. Sutow WW, et al: *Clinical Pediatric Oncology*. St. Louis: Mosby, 2, 1973.