

## ACTINOMYCOSIS: AN UNUSUAL COMPLICATION OF ORAL SURGERY—A CASE REPORT

MOHAMMAD HOSEIN KALANTAR MOTAMEDI, D.D.S., O.M.F.S.\*

*From the Oral, Maxillofacial and Reconstructive Surgery Clinic, Baqiyatallah Medical Center, Imam  
Hosein University of Medical Sciences, Tehran, Islamic Republic of Iran.*

### ABSTRACT

Actinomycosis, a rather uncommon infection of the oral cavity, poses and unusual problem: recurrence. Primary or initial diagnosis of the disease is difficult and can be made easier only if the clinician bears in mind a few important facts: a previously compromised site is usually present, a slow, low-grade, almost painless infectious course is prevalent which tends to localize, and responds to short-term antibiotic therapy only to be followed shortly by recurrence. It is stated that with this set of features the patient should be considered to have actinomycosis until proven otherwise. This report presents a rather unusual case of cervicofacial actinomycosis which occurred secondary to an attempted surgical extraction of an impacted maxillary third molar tooth. The organism was sampled under anaerobic conditions, identified, isolated and confirmed by Gram's stain, culture, and biochemical tests, respectively. Cure was obtained only after surgical drainage, debridement, and oral antibiotic administration continuing for approximately three months.

*MJIRI, Vol. 7, No.2, 137-140, 1993.*

### INTRODUCTION

Actinomycosis is a chronic granulomatous suppurative fibrosing disease caused by anaerobic gram-positive, branched, filamentous, opportunistic bacteria of low virulence and of the genus *Actinomyces* which were previously thought to be fungi. It has a worldwide distribution, is uncommon in children, and more common in males (4:1). *Actinomyces*, not found free in nature, are normal inhabitants of the nasopharynx and GI tract. Infection occurs when these bacteria enter damaged tissue following infection, trauma, or surgery.<sup>1,3,4,6,11</sup>

Actinomycosis is classified anatomically as three forms: (1) cervicofacial, (2) abdominal, (3) pulmonary. The disease may remain localized or spread to the contiguous salivary glands, bone, or skin of the face and neck and does not follow anatomic fascial planes in contrast to other infections.

\*Assistant Professor and Head of Clinic of Oral, Maxillofacial and Reconstructive Surgery Baqiyatallah Medical Center, Tehran, Islamic Republic of Iran.

60% of actinomycotic infections are cervicofacial and there is a history of extraction or jaw fracture in 20% of the cases. The disease runs a protracted course and it usually takes six weeks or longer for suppuration. Multiple sinuses are almost pathognomonic. Acute pain is uncommon.<sup>1-6,11,16,20,23,25</sup>

The most commonly isolated organisms in order of decreasing frequency are, *A. naeslundii*, *A. viscosus*, *A. odontolyticus*, and *A. propionica*. All components of the oral flora and plaque are capable of causing the disease in humans. The microbe is not invasive and grows slowly in culture and tissue. The disease does not respond to antifungal agents. Entry portal must be extensive and is usually of traumatic origin. There is almost always concurrent infection with other anaerobic microorganisms.<sup>1,3,4,6,11,12,18,20</sup>

The usual disease pattern is one of localization and abscess formation tending to drain by sinus tracts. The pus commonly exhibits the typical "sulfur granules" or bacterial colonies formed by masses of filamentous organisms and myceliae which are bound by calcium

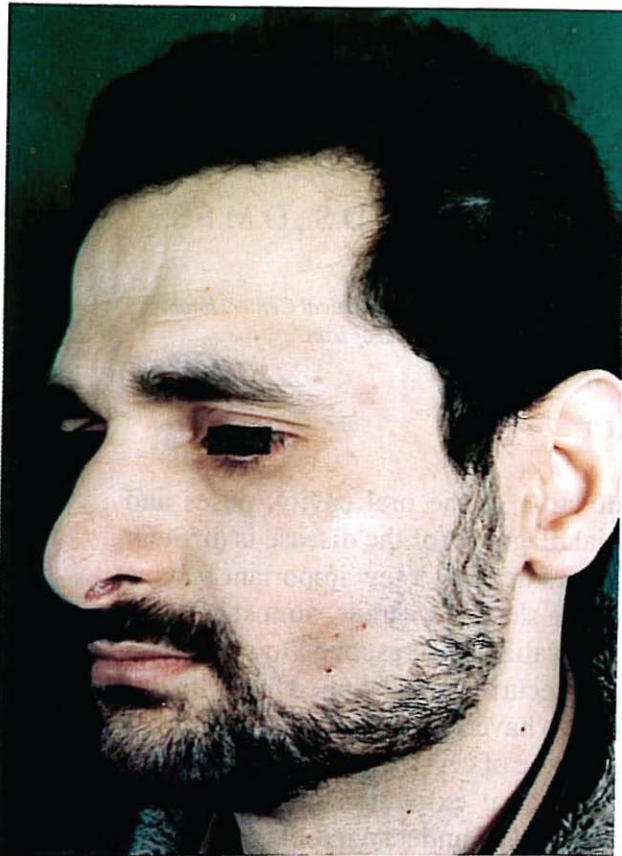

Fig. 1. The appearance of the patient prior to the acute state. Note slight erythema in the area of the left cheek.

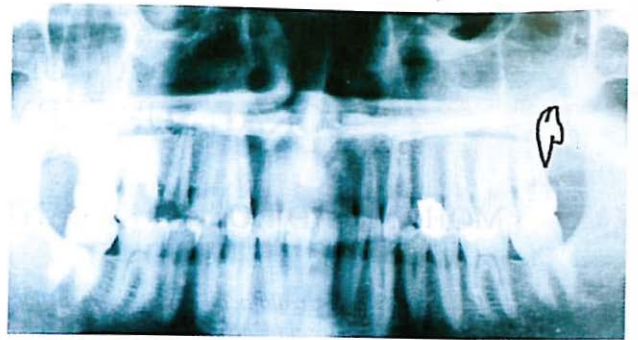


Fig. 2. The orthopantomogram x-ray of the patient upon referral. Note the remnants of the upper left third molar tooth (outlined).

phosphate and appear as yellow grains 2 mm in diameter suspended in the suppurative material. The hyphae can fragment into short bacilli and are basophilic. Growth in culture is slow and may take up to 10 days.

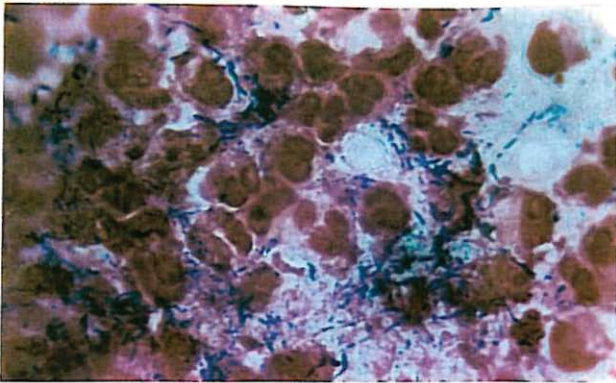
The Gram's stain may exhibit the gram-positive filaments. Fluorescent antibody tests for *A. israelii* available will allow definite diagnosis to be made early in the course of the disease. Treatment with penicillin in the usual dose and duration will cause apparent resolution but recurrence always occurs within several weeks along with painless fibrosis and scarring. Therefore, treatment must be of long-term and with massive doses of penicillin. Obviously, incision, drainage, and adequate debridement are an essential part of any similar surgical procedure.<sup>2,3,5,12,13,15,17,19,23</sup>

### CASE REPORT

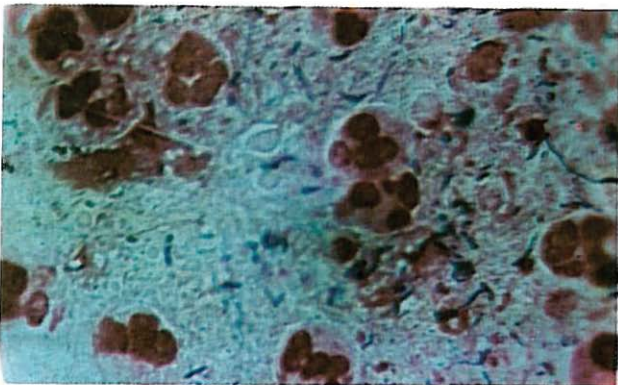
A 35-year-old male lab technician from Tehran referred to the OMFS clinic of Baqiyatullah Hospital Medical Center on December 24, 1991 complaining of a hard, fibrous, slightly tender and non-fluctuant swelling 2 cm in

diameter in the left cheek. The patient stated that the swelling developed approximately two weeks after an unsuccessful surgical extraction attempt of the upper left impacted third molar tooth, one year ago. Apparently the procedure was very lengthy and traumatic, for the patient stated that it was followed by massive facial and infraorbital edema which took nearly a week to subside after which a "lump" gradually developed in the upper part of his left cheek. This swelling failed to subside and fluctuated in size every now and then despite oral and parenteral antibiotic therapy prescribed intermittently during the past year by his dentist (Fig. 1).

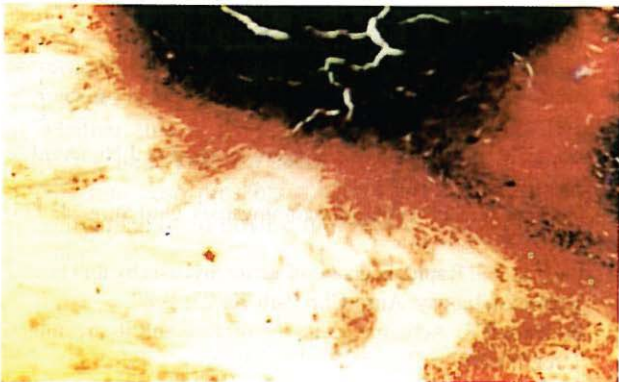Upon first visit, the patient stated that the swelling had recently increased in size and became acute but was painful only when squeezed. Intraoral and extraoral exams were noncontributory except for the firm swelling noted above which was palpable in the left cheek anterior to the masseter and at the level of the parotid duct papilla. X-ray findings were normal and non-contributory except for the remainings of the upper left third molar tooth (Fig. 2). The parotid duct and salivary secretion were tested normal upon first visit but during the ten-day work-up period when the patient returned with an acute episode of exacerbation and enlargement of the swelling, the "milking test" was negative. The pressure presumably prevented salivary secretion from the left parotid duct since sialography was normal afterwards. Despite antibiotic therapy during this period of laboratory and clinical work-up the swelling took the form of an extra-oral abscess surfacing in the days following. Incision and drainage of the abscess was performed before development of a sinus tract in an attempt to prevent scarring. Five to ten ml of white odorless pus was thus obtained demonstrating green and almost fluorescent "sulfur granules", which were aspirated and sent anaerobically for Gram stain evaluation and culture. The patient was prescribed phenoxymethyl potassium penicillin and probenecid 500 mg of each every eighth hours. The diagnosis was confirmed and the species identified in four days using Gram stain smear isolation on blood agar, and anaerobic culture by the jar and gas pack



A



B

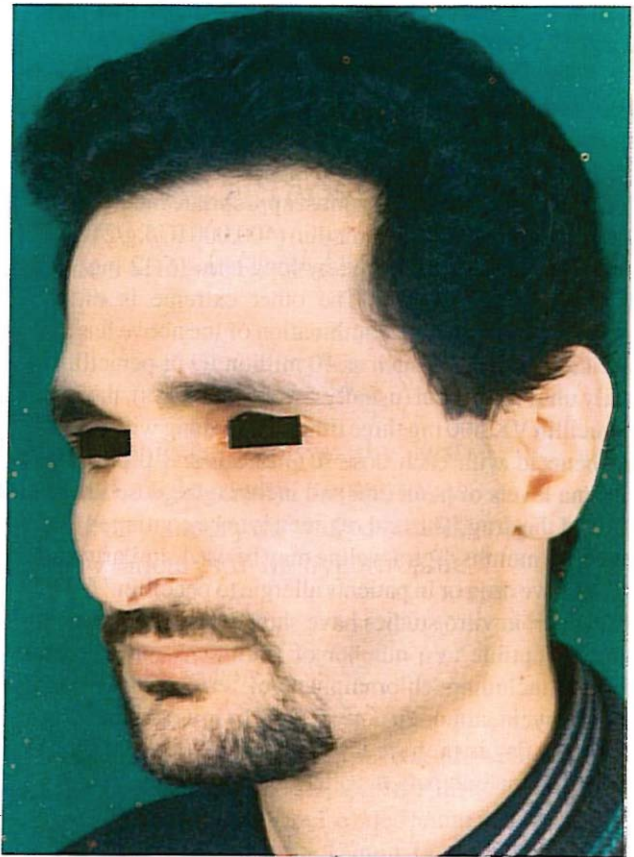


C

**Fig. 3.** A, and B: Photomicrographs of a crushed sulfur granule. Note the basophilic rods of the bacteria dispersed among the polymorphonuclear leukocytes C., Modified Gram stain depicts the branched morphology of the bacteria (in white) among the cellular debris, (magnification 1000 ×).

system and biochemical tests (Fig. 3).

The patient was unable to obtain the drug prescribed and thus was given oral tetracycline 500 mg every six hours for a period of two and a half months, effectuating a definite cure (Fig. 4).



**Fig. 4.** The appearance of the patient approximately six months after extraoral incision, drainage, and antibiotic therapy.

## DISCUSSION

The pathogenesis of actinomycosis is not entirely clear. It appears to be endogenous and is non-communicable. Trauma seems to play a role in providing a portal of entry; thus extraction of teeth, mucosal lacerations, periodontal pockets or carious teeth can provide entry for the organism, although however, this is not equivocal.

The skin overlying the abscess may appear purplish red and indurated or fluctuant (Fig. 1). The sinus tracts heal and recur at multiple sites and cause disfigurement and facial scarring.<sup>3-6,15,17-20</sup> The pus usually contains the typical yellow sulfur granules. However, in our case the granules were bright green. Such an occurrence was not found to be reported in the literature.

Infection of the soft tissues may burrow through to involve the mandible or less commonly the maxilla. If the bone of the maxilla is invaded the ensuing osteomyelitis may eventually involve the cranium, meninges, or brain itself. Once the infection reaches bone, tissue destruction may be extensive. Such destructive lesions within bone may occur or localize at the apex of one or more teeth and simulate a pulp-related infection such as a granuloma or

## Actinomycosis Following Dral Surgery

cyst. Wesley and colleagues have reported such a case and noted 12 other such cases in the literature.<sup>1,2,5,14,16,23,25</sup>

Actinomycosis usually grows on brain-heart agar, blood agar, or thioglycolate broth media. However, in 50% of the cases the organism is not grown.

Once diagnosed, treatment must be specific, although controversy exists as to the most appropriate method. One view is for high dose IV penicillin (400,000 IU/kg/24 h) for six to eight weeks followed by long term (6-12 mo) oral penicillin (2-4 g/24 h). The other extreme is of oral administration only. A combination of the above has also been recommended such as 10 million IU of penicillin G daily until resolution (usually seven to ten days), then oral penicillin VK 500 mg three times a day along with 500 mg probenecid with each dose to increase and prolong the plasma levels of penicillin and increase the dose interval time of the drug. The oral regimen is to be continued for at least 3-6 months. Tetracycline may be used similarly as an alternative drug or in patients allergic to penicillin.<sup>7,10,11,21,22</sup> However, in vitro studies have shown that actinomycetes are susceptible to a number of additional antimicrobial agents including chloramphenicol, erythromycin, and clindamycin, although doxycycline or minocycline given once per day is preferred over tetracycline as the second drug of choice in patients allergic to penicillin.<sup>8,12,3</sup>

### ACKNOWLEDGEMENTS

The author would like to thank Mr. Mehran Azadeh and Mr. Ranazanalı Ataie M.S., Head of the Department of Microbiology, Baqiyatallah Hospital, for their assistance, and also my esteemed colleague Dr. Masoud Yagmaic D.D.S., O.M.F.S. for his guidance.

### REFERENCES

1. Barclay JK: Actinomycosis of the mandible: a case report. Aust Dent J 23: 477, 1978.
2. Bazhanov NN: Use of hyperbaric oxygen in the therapy of maxillofacial actinomycosis. Stomatologia 59: 28, 1980.
3. Blair GS: An unusual dental abscess. Br Dent J 147: 17, 1979.
4. Blake GH: Cervicofacial actinomycosis associated with *Eikenella corrodens*: case report. Milit Med 147: 474, 1982.
5. Borssen E: Actinomycosis of infected dental root canals. Oral Surg 51: 643, 1981.
6. Bronner M: Actinomycosis, 2nd ed., Bristol, John Wright and Sons, 1971.
7. Brown JR: Human actinomycosis: a study of 181 subjects. Human Path 4: 319, 1973.
8. Butas CA: Disseminated actinomycosis. Can Med Assoc J 103: 1069, 1970.
9. Choukas NC: Actinomycosis of the mandible. Oral Surg 11: 14, 1958.
10. Crowley MC: Actinomycosis in the normal mouth and in infection processes. Am J Orthod Oral Surg 30: 680, 1944.
11. Davis MIJ: Analysis of 46 cases of actinomycosis with reference to etiology. Am J Surg 52: 447, 1941.
12. Drake DD: Childhood actinomycosis. Arch Dis Child 51: 979, 1976.
13. Eastridge CE: Actinomycosis: a 24-year experience. South Med J 65: 839, 1972.
14. Fergus HS: Actinomycosis involving a periapical cyst in the anterior maxilla: Report of a case. Oral Surg 49: 390, 1980.
15. Freeman LR: conservative treatment of periapical actinomycosis. Oral Surg 51: 205, 1981.
16. Happonen RP: *Actinomyces israelii* in osteoradionecrosis of the jaws. Oral Surg 55: 580, 1983.
17. Hurt DF: Clinicopathologic conferences, Case 39, Part 3. Cervicofacial actinomycosis: J Oral Maxillofac Surg 40: 367, 1982.
18. Kirsch SA: Cervicofacial actinomycosis following surgical trauma in rats. Oral Surg 46: 827, 1978.
19. Lerner PI: Susceptibility of pathogenic actinomycetes to antimicrobial compounds. Antimicrobial Agents Chemo 5: 302, 1974.
20. Lopez MV: Cervicofacial actinomycosis. Eur J Nuc Med 7: 143, 1982.
21. Norman JE: Cervicofacial actinomycosis. Oral Surg 24: 735, 1970.
22. Pollock PG: Rapid diagnosis of actinomycosis by thin needle aspiration biopsy. Am J Clin Path 70: 27, 1987.
23. Robbins TS: Actinomycosis: the disease and its treatment. Drug Intell Clin Pharm 15: 49, 1981.
24. Samuels HS: Actinomycosis of the mandible. J Oral Surg 32: 679, 1974.
25. Walker S: Mandibular osteomyelitis caused by *Actinomyces israelii*. Oral Surg 51: 243, 1981.