

A RARE CASE OF GASTRIC LIPOMA

HOSSEIN FOROUTAN, M.D.

From the Department of Gastroenterology, Imam Khomeini Medical Center, Tehran University of Medical Sciences, Tehran, Islamic Republic of Iran.

ABSTRACT

A middle age woman was hospitalized for investigation of a mobile filling defect in the stomach with exacerbation of 3-year gastric symptoms. Gastroscopy revealed a huge pedunculated polyp. Histologic report of the mass was gastric antral lipoma. Since the patient refused surgery, cauterization polypectomy was performed without any complication.

MJIRI, Vol. 6, No. 4, 309-310, 1993.

CASE REPORT

A 55-year-old woman was referred to our hospital in August, 1991, with exacerbation of gastric symptoms. She had a 3-year history of postprandial nausea, vomiting, and epigastric pain. Physical examination on admission except for epigastric tenderness was normal.

Admission laboratory routine studies were in the normal limit. Upper GI series performed in June, 1991, revealed a mobile pedunculated mass and hiatal hernia (Figs. 1 and 2). Small bowel transit and barium enema were normal.

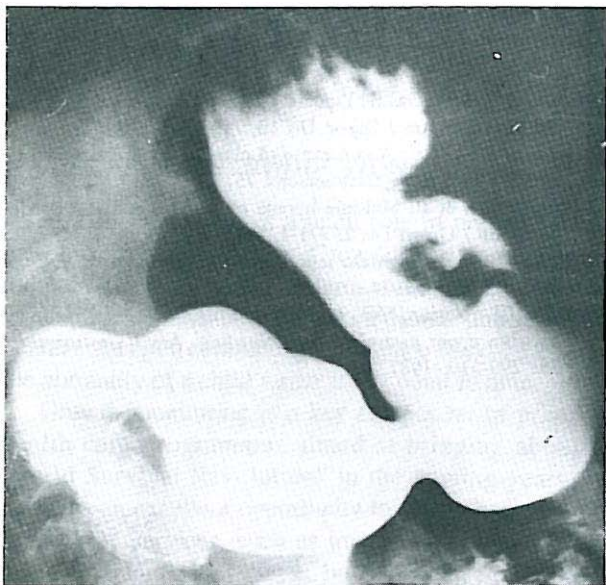

Fig. 1. Upper gastrointestinal series showing filling defect on greater curvature.

Gastroduodenoscopy was done. A 5x4 cm pedunculated mass with normal mucosal surface was found and several deep biopsies were taken. The histologic report was gastric antral lipoma (Fig. 4).

Surgery was advised but was refused by the patient. So with great caution a nonsurgical preparation polypectomy with snare cauterization was done with no complication. (The procedure was recorded by videoscope camera).

After 10 days of hospitalization and close observation, repeated endoscopy showed no lesion and the patient was discharged in excellent condition. After six months of follow-up, there was no problem (Fig. 3).

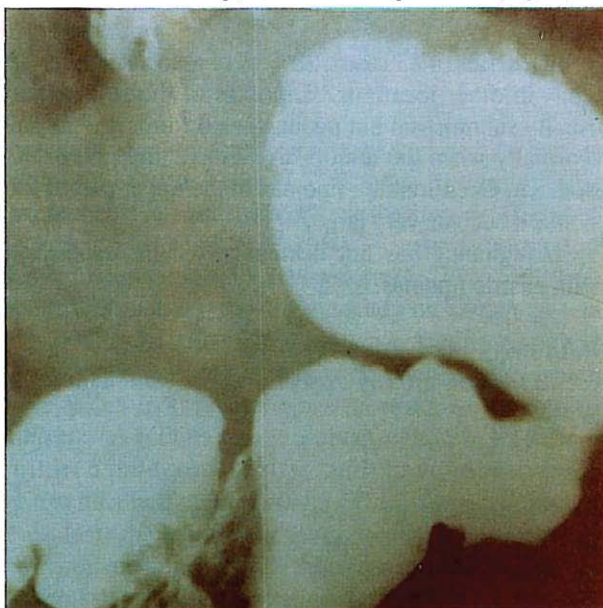


Fig. 2. Upper GI series, filling defect in antrum.

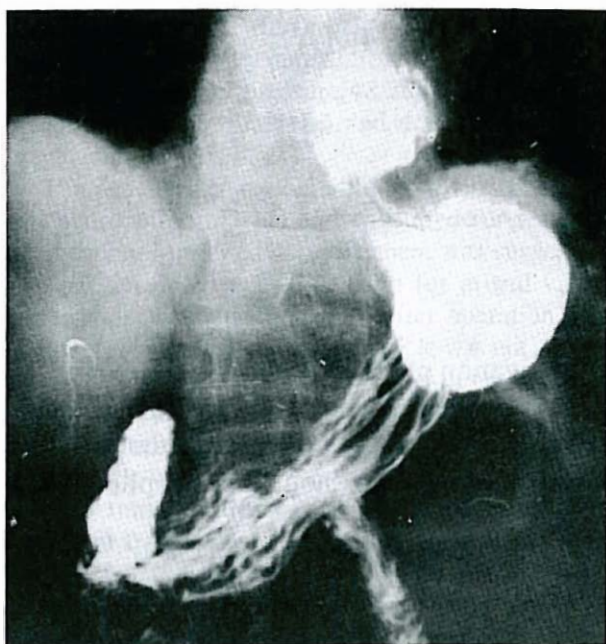


Fig. 3. Upper GI series after polypectomy.

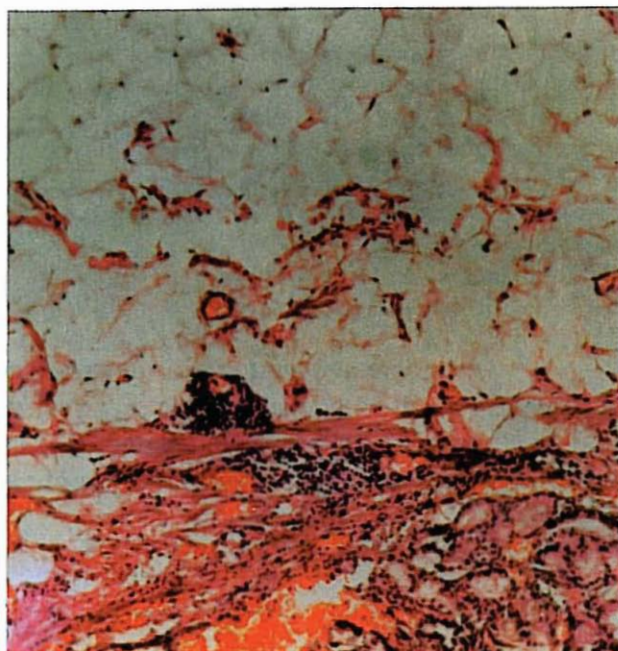


Fig. 4. Submucosal lipoma (X 20).

DISCUSSION

Lipoma of the stomach is a rare tumor arising from submucosal tissue.¹ Lipomas are usually solitary and are located in the distal part of the stomach (75% in the antrum).

The most common symptom is GI bleeding.² Gastric lipomas comprise about 3% of all benign tumors of the stomach. Histologically, these lesions are purely lipomatous and do not differ from those in the other parts of the body.

In a series of 83 cases, 28% were associated with lipomas in other locations.³ Lipomas of the stomach are usually submucosal but pedunculated forms are unusual especially when the tumors are in the antral part of the stomach. Occasionally, lipomas of the upper part of the stomach become very large.⁴

Malignancy has not been reported in association with gastric lipomas.

Pathology and Management

The lesion grossly appears benign, although often

secondary to overlying pressure it is necrotic and ulcerated. When gastric lipoma is suspected, circumferential excision with a margin of normal tissue is the treatment of choice.⁵ Although in our case surgery was suggested, it was refused by the patient. Therefore, cauterization polypectomy, with regard to the long stalk that facilitates polypectomy, was carefully performed without any complication.

REFERENCES

- 1- Turkinyton RW: Gastric Lipoma. Report of a case and review of the literature. *Am J Digest Dis* 10: 719-25, 1965.
- 2- Johnso: DSI, et al: A rare cause of massive upper gastrointestinal bleeding. *Am J Gastroenterol* 75: 299, 1981.
- 3- Deeths TM, et al: Multiple lipoma of the stomach and duodenum. *Am J Digest Dis* 2: 771-4, 1975.
- 4- Bloch C, Peck HM: Case report: giant gastric lipoma. *Sinai J Med* 41: 593-6, 1974.
- 5- Denis CI, Johnson, MD, et al: Gastric lipomas. A rare cause of massive upper gastrointestinal bleeding. *Am J Gastroenterol* 75: 299-310, 1987.