

BRUCELLA MELLITENSIS ENDOCARDITIS: DIAGNOSIS AND TREATMENT IN SIX ADULT PATIENTS.

IRAJ NAZERY, MD AND MASSOUD ESLAMI, M D

*From the Department of Cardiology, Imam Khomeini Hospital, Tehran University of Medical Sciences, Tehran,
Islamic Republic of Iran.*

ABSTRACT

Brucella endocarditis is an uncommon but not rare manifestation of brucellosis in our country. We report six adult patients aged 20 to 45 years. Two of our patients were female, and this is the first time that Brucella endocarditis was reported in adult females.

In five cases, aortic valve replacement was performed in addition to combined antibiotic therapy. One of them died due to immediate complication of cardiac surgery, but the others had an excellent recovery. Our study shows that medical treatment is not sufficient for *Brucella mellitensis* endocarditis, and urgent cardiac valve replacement must be considered.

The prognosis will not be poor with combined medical and surgical therapy.

MJIRI, Vol. 6, No. 1, 35-37, 1992

INTRODUCTION

With fatal brucellosis, endocarditis has been found in 80% of cases.¹ Fortunately, endocarditis is an uncommon complication of brucellosis. Its incidence in adult population varies from 0.3% to 1.6%.^{2,3}

This report gives further information about symptoms, signs, laboratory findings, non-invasive studies, and management of *Brucella mellitensis* endocarditis.

MATERIAL AND METHODS

The clinical records of six patients with brucella endocarditis were reviewed. There were four males and two females with an average age of 31 years (range 20 to 45 years). *Brucella mellitensis* was isolated from blood, bone marrow and/or vegetation. Five patients underwent aortic valve replacement. In one of them (case 3), apical rupture occurred during surgery which was repaired. Two hours after operation, sinus bradycardia, atrioventricular dissociation and finally cardiac arrest occurred. Unfortunately, cardiopulmonary resuscitation was unsuccessful.

Urgent mitral valve replacement was not performed in one of the cases (case 6). She was discharged from hospital in good general condition and elective mitral valve replacement was considered. Approximately one month later, she suddenly became dyspneic. A clinical diagnosis of pulmonary edema due to acute mitral regurgitation was made. Six hours after admission, she died in low output state. Autopsy was not performed.

Four patients were followed postoperatively for an average period of 33 months (range 12 to 48 months). All of them are asymptomatic and no major complication occurred.

RESULTS

From 1985 to 1989, six cases of *Brucella mellitensis* endocarditis were admitted to the Imam Khomeini Hospital. The details of the cases are given in Table I.

The disease was more common in males (4 cases) than females (2 cases). In our cases, brucella endocarditis typically presented as a subacute or chronic infection. Fever and dyspnea were found in all of our

Brucella Endocarditis

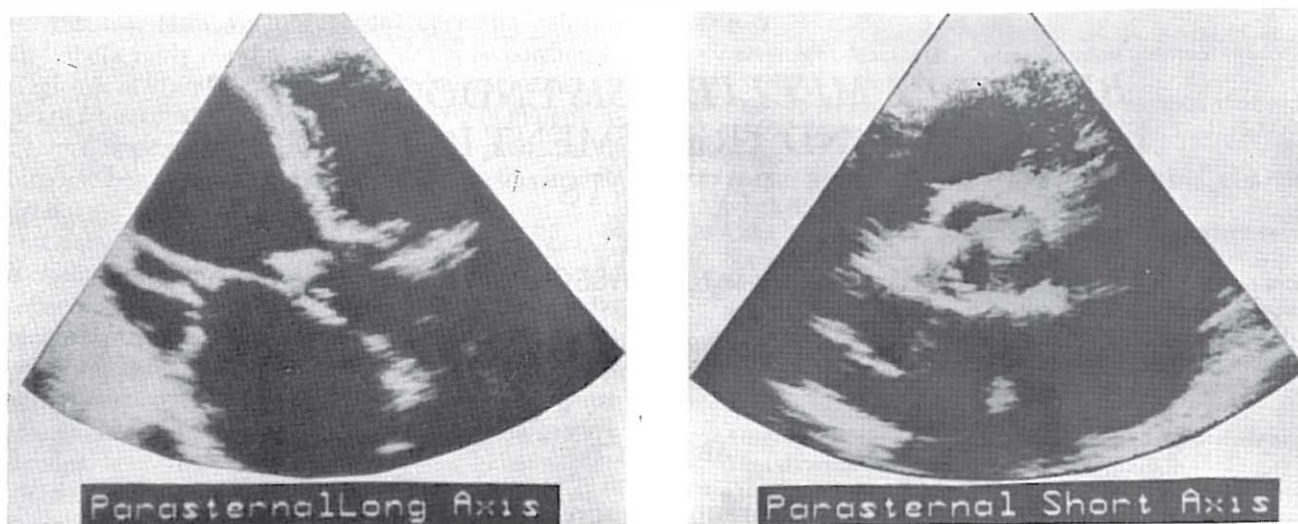


Fig.1,2: Large vegetation over ventricular side of right and noncoronary cusps of aortic valve.

Table I. Summary of important findings in six patients with *Brucella mellitensis* endocarditis

Case	Sex	Age (yrs)	Duration of Symptoms (months)	Wright Agglutination Titer	2ME Titer	Blood Culture	Bone Marrow Culture	Vegetation culture	Echocardiography	Treatment	Outcome
1	male	32	2	1:640	1:320	positive	positive	positive	aortic valve vegetation	rifampicin + doxycycline + aortic valve replacement	completely asymptomatic after 3 years
2	male	28	6	1:1280	1:320	positive	positive	not performed	aortic valve vegetation + aneurysm of valsalva sinus	rifampicin + tetracycline + streptomycin + aortic valve replacement	completely asymptomatic after 3 years
3	male	45	12	1:640	1:160	negative	negative	positive	aortic valve vegetation	rifampicin + tetracycline + aortic valve replacement	died due to immediate complication of cardiac surgery
4	male	20	8	1:320	1:160	positive	negative	not performed	aortic valve vegetation	tetracycline + streptomycin + aortic valve replacement	completely asymptomatic after four years
5	female	25	8	1:640	1:320	positive	not performed	not performed	aortic valve vegetation	rifampicin + tetracycline + cotrimoxazole + aortic valve replacement	completely asymptomatic after one year
6	female	36	12	1:640	1:160	positive	positive	not performed	aortic and mitral valve vegetations	rifampicin + tetracycline	died due to relapse

patients, splenomegaly in 83%, and clubbing in 50% of cases. A history of previous rheumatic or congenital heart disease was not found.

Laboratory examination revealed leukopenia or normal leukocyte count in 100%, 2-ME titer above 1:80 in 100%, positive blood culture for *Brucella mellitensis* in 83%, and positive bone marrow culture in 60% of cases.

Aortic valve vegetation was detected in all of the patients by 2-D echocardiography (Fig. 1,2) but mitral valve vegetation was seen in only one of them. In one of the patients (case 3), a very small vegetation was detected during surgery, which was not reported by 2-D echocardiography.

In five cases, aortic valve replacement was performed with Bjork-Shiley prosthesis in addition to

combined antibiotic therapy. One of them died due to immediate complication of cardiac surgery, but the others had an excellent recovery. After one to four years follow-up, they were asymptomatic and no complication occurred.

DISCUSSION

Two of the six patients described here were female and this is for the first time that *Brucella mellitensis* is reported in adult females.¹⁻¹³

In all of our cases the diagnosis of endocardial involvement was made by two dimensional echocardiography. Catheterization was not performed.

The etiologic agent (*Brucella mellitensis*) was clearly identified by blood, bone marrow, and vegetation cultures. No underlying heart disease was detected.

Although many antibiotic regimens have been tried for treatment of brucella endocarditis in adult patients, we presently prefer a combination of rifampicin (600-900 mg/day), Co-trimoxazole (Sulfamethoxazole 2400 mg/day, trimethoprim 480 mg/day), and tetracycline (2g/day) or doxycycline (200mg/day) over a period of 12 weeks.

In Lubain et al's study,¹² brucella endocarditis in children was treated successfully by tetracycline and streptomycin. Medical therapy is not sufficient in adult patients however, and urgent cardiac valve replacement must be considered in addition to antibiotics.^{7-12,14} In one of our patients (case 6), mitral valve replacement was not performed and she suddenly died due to acute mitral regurgitation and pulmonary edema.

Our study shows that prognosis is not poor with combined medical and surgical therapy. The myocardial dysfunction is reversible such that after completion of antibiotic therapy and cardiac surgery, survival rate is notable.

REFERENCE

- 1- Perry TM, Belter LF: Brucellosis and heart disease. II. Fatal brucellosis. *Am J Pathol* 36: 673, 1960.
- 2- Dalrymple-Champney SW: Brucella infection and undulant fever in man. London, Oxford University Press, 1960.
- 3- Spink W: The Nature of Brucellosis. Minneapolis, University of Minnesota Press, 1956.
- 4- Hart FD: Morgan A, Lacey B: *Brucella abortus* endocarditis. *Br Med J* 2:1048, 1951.
- 5- Wanderman KL, Yarom R: Brucellosis with endocarditis: report of an unusual case with observations on the relationship to aortic stenosis and on treatment. *Isr J Med Sci* 6:273, 1970.
- 6- Golden B: Layman TE, Koontz FP, et al: *Brucella suis* endocarditis. *South Med J* 63:392, 1963.
- 7- O'Meara JB: Eykny S, Jenkins BS, et al: *Brucella mellitensis* endocarditis: successful treatment of an infected prosthetic mitral valve. *Thorax* 29:377, 1974.
- 8- Heibig J: Beall AC, Myers P, Harder E, Feteih N: Brucella aortic endocarditis corrected by prosthetic valve replacement. *Am Heart J* 106, 594, 1983.
- 9- Cleveland JC, Suchor RJ, Dague J: Destructive aortic valve endocarditis from *Brucella abortus*: Survival with emergency aortic valve replacement. *Thorax* 33, 616, 1978.
- 10- Pratt DS: Tenney JH, Bjork CM, Reller L B: Successful treatment of brucella endocarditis. *Am J Med* 64, 897, 1978.
- 11- Arefi H, Kamal-Hedayat D: Osler's node in a patient with brucella endocarditis. *Acta Med Ira* 29, 43, 1987.
- 12- Lubani M, Sharda D, Helin I.: Cardiac manifestations in brucellosis. *Arch Dis Child*, 61, 569, 1986.
- 13- Wolf LM, Hazan E, Courtosis H, Schrub CI: Endocardite brucellienne, La. *Novelle Press Medicale* 2, 493, 1973.
- 14- Jeroudi MO, et al: Brucella endocarditis. *Br Heart J* 58 (3), 279-83, 1987.