

## Original Articles

# THERAPEUTIC EMBOLIZATION OF BRONCHIAL ARTERY FOR MASSIVE HEMOPTYSIS

FARHOOD SAREMI, M.D.

*From the Department of Diagnostic Radiology, Vali-Asr Hospital, Imam Khomeini Medical Center, Tehran  
University of Medical Sciences, Tehran, Islamic Republic of Iran.*



### ABSTRACT

34 bronchial and 13 intercostal arteries were selectively embolized in 27 patients. The most frequent predisposing factor was either active or residual pulmonary tuberculosis. The procedure was performed with Urografin as the contrast agent, cobra shaped or headhunter catheters, and gelfoam (no. 18) or Ivalon (no. 9) particles. The most common anatomic pattern was a common bronchial artery trunk (48%). Immediate hemostasis was achieved in 23 of 27 patients (85%). Early recurrence (24-72 hours) occurred in 13%. 2 patients underwent surgery following successful embolization. 16 patients were followed at least for six months, and recurrent hemoptysis developed in three patients (18.75%). Spinal cord injury with neurologic symptoms occurred in one patient. The immediate cause of the injury was probably the toxicity of the contrast medium.

*MJIRI, Vol.5, No. 1,2, 1-7, 1991*

### INTRODUCTION

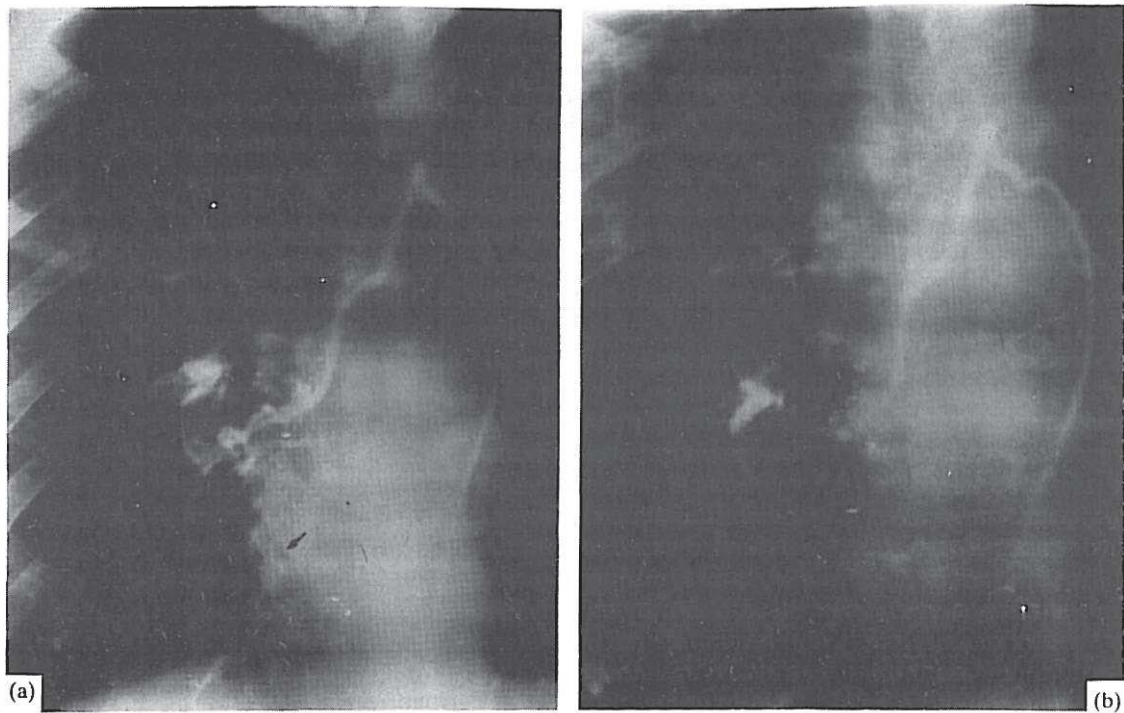
Transcatheter embolization of bronchial and other systemic pulmonary arteries has proved to be an effective method of accomplishing temporary or permanent hemostasis.<sup>1,2</sup> This method has become an accepted method to control massive or recurrent hemoptysis especially in patients with chronic pulmonary diseases who are poor candidates of lung resection.<sup>3,4</sup> In addition, bronchial artery embolization can provide information about the cause and location of the hemoptysis. To gain a better understanding of the importance of this relatively new procedure, I report my experience in 27 patients with life-threatening hemoptysis.

### MATERIAL AND METHODS

34 bronchial and 13 intercostal arteries were selec-

tively embolized in 27 patients with lung diseases from June, 1987, to October, 1990. All procedures were performed in the Vali-Asr Diagnostic Radiology Department of Imam Khomeini Hospital, affiliated to Tehran University of Medical Sciences. There were 16 men and 11 women, aged 21 to 65 years. The patients were referred for embolization after clinical, endoscopic, and surgical evaluation. Any hemoptysis that was considered to be life-threatening was an indication for bronchial artery embolization. The most frequent pulmonary diseases were tuberculosis (16), chronic pulmonary infection or bronchiectasis (3), post-traumatic (1), bronchial carcinoma (1), chronic interstitial pulmonary disease (1), anthracosilicosis (1), and idiopathic hemorrhage (3). Percutaneous transfemoral catheterization was performed in all patients under local anesthesia. Either cobra shaped or headhunter catheters (Cook Incorporation) were used. After selective injections, embolization of all branches re-

## Embolization of Bronchial Artery



**Fig. 1.** Case 1. (a) Selective bronchial angiogram shows enlarged right bronchial artery with extravasation of contrast material into the posterobasilar branch of the intermediate bronchus due to active bleeding (arrow). (b) Postembolization angiogram demonstrates complete occlusion of the peripheral branches. Egg-shell calcifications are also noted in perihilar region.

responsible for hemoptysis was performed unless a spinal cord artery branch was detected on the selective arteriogram. Either Urografin or Angiografin was used as the contrast material. The amount of contrast medium injected ranged from 3 cc to 5 cc per injection. The angiographic findings included pathologic hypervascularization of the involved area, hypertrophy of the supplying artery, and interarterial bronchopulmonary shunt. Acute extravasation was noted in 2 patients. Gelfoam that had been cut into small fragments was used in 18 patients, and polyvinyl alcohol foam (Ivalon) was chosen in 9 patients. The fragments were softened in dextrose-saline. Then the distal end of the radiopaque was wedged in the appropriate artery and embolic particles were carefully introduced into the artery in quantities of 3 to 5 at a time under the fluoroscopic control.

### RESULTS

47 arteries in 27 patients were successfully embolized. Failure to achieve selective localization of the catheter occurred in 2 patients. A patient could not be treated by this procedure because of the presence of a spinal artery connected to right intercostobronchial trunk. These 3 patients were deleted from the study. The immediate hemostasis was achieved in 23 of 27

patients (85%). Recurrent bleeding 24-72 hours after transcatheter embolization occurred in 3 of the 23 patients (13%) with initially successful hemostasis. The sources of rebleeding were additional routes of systemic (intercostal) blood supply that had not been embolized during initial therapy. These arteries were also successfully embolized. 2 patients with successful embolization underwent surgery 2 weeks following embolization.

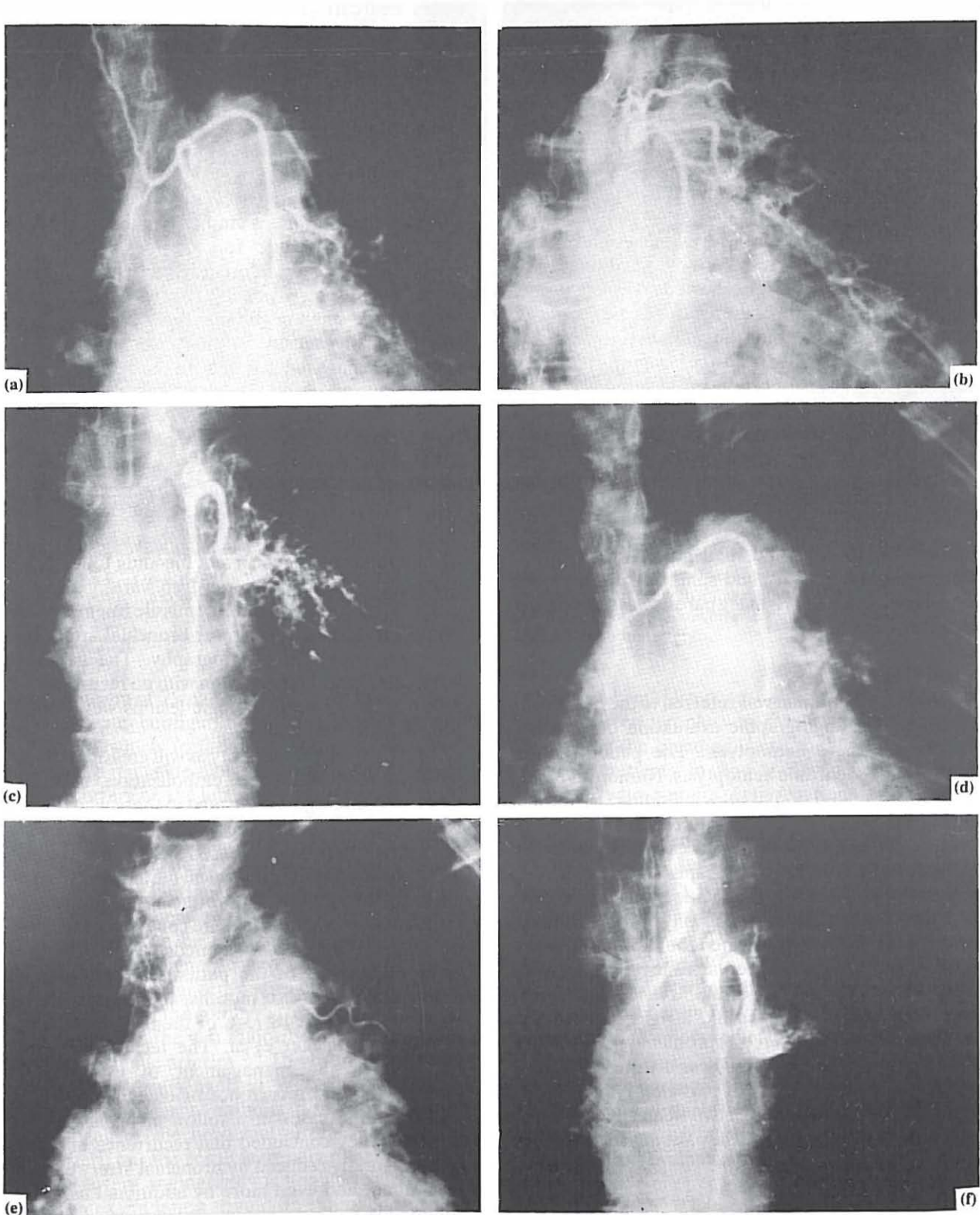
In the group of patients with successful embolization without surgery (no: 21), 16 were followed at least for 6 months. Recurrent hemoptysis developed in 3 patients (18.75%), but the hemoptysis was less severe than before treatment. 5 of these patients were lost to follow-up.

During diagnostic angiography and embolization, cough was a usual finding as contrast material or emboli were injected selectively. Chest pain and low grade fever were also frequent after embolization and often subsided within 24 hours. No major complications were encountered in this series of patients except one (case report 1).

### Case Report 1

A 60-year-old man was admitted to the hospital complaining of shortness of breath and three episodes of massive hemoptysis during the past 20 days. Admission chest radiographs showed perihilar egg-shell calci-





**Fig. 2.** Case 2. A 59-year-old woman with a 5-year history of recurrent hemoptysis. (a), (b), and (c), demonstrate selective angiography of 3 bronchial arteries supplying left lung: a common bronchial trunk, a left intercostobronchial trunk, and inferior left bronchial artery. Enlarged bronchial vasculature and hypervascularity are secondary angiographic signs of abnormality. (d), (e), (f) Post embolization angiograms following injection of PVA particles. Total occlusion of the arteries are achieved followed by control of hemoptysis.

## Embolization of Bronchial Artery

fications, right lower lobe fibrotic strands, and peripheral amorphous calcifications mostly compatible with residual pulmonary tuberculosis. Bilateral bronchography showed mild fusiform bronchiectasis in right lower lobe segmental branches. Bronchoscopy demonstrated diffuse bleeding at the right lower lobe. Selective bronchial angiography revealed an enlarged right bronchial artery trunk at T4-T5 level with peripheral hypervascularization and extravasation of contrast material into the adjacent bronchus due to active bleeding (Fig. 1). The artery was then embolized by Ivalon (PVA) particles. Postembolization angiogram of the bronchial artery showed complete occlusion of the distal portion of the artery. During a search for other sources of bleeding the catheter tip intercostal artery near the level of T5, and 4 cc Urografin 60% was injected into the vessel, producing severe back pain. The catheter was then removed without further manipulation or intervention. Neurological symptoms gradually appeared 4 hours later. They became manifested within 24 hours as paralysis of the right leg, sensory disturbances at a T5 level, and urinary retention. Right leg paralysis and sensory disturbances persisted for 10 days and then gradually subsided. After two weeks sensory and sphincter disturbances disappeared, but slight right leg paresis was still present 3 months later.

### Case Report 2

A 59-year-old woman was referred to the radiologic department for angiographic evaluation of a recent episode of massive hemoptysis. The patient had a 5-year history of chronic hemoptysis. Numerous bronchoscopies revealed no pathologic finding. Bronchial washing did not show any abnormal cells. Hemoptysis was mostly from the left side but occasionally from the right side. Serial chest radiographs showed diffuse progressive reticulonodular opacities more prominent on the left side. Selective angiography of bronchial and intercostal arteries demonstrated four abnormal feeding arteries with marked hypervascularization especially on the left side (Fig. 2). Abnormal arteries included a common bronchial artery trunk, a right intercostobronchial trunk, a left intercostobronchial trunk, and a second left bronchial artery. These arteries were successfully embolized with PVA particles in three different sessions and in a period of two weeks. Hemoptysis was completely stopped, and the patient had no recurrence during a 2-year follow-up.

## DISCUSSION

Bronchial artery embolization has become an accepted method to control massive and recurrent hemoptysis by most authors.<sup>1-3</sup> Although surgery re-

mains the treatment of choice, there are some patients who are poor candidates for immediate thoracotomy. The bronchial artery embolization procedure should be considered early in the evolution of massive hemoptysis. Massive hemoptysis is a major problem, with a high mortality, usually not because of hypovolemia but because of asphyxiation. Any massive acute episode of bleeding threatens acute asphyxiation, especially in those patients with impaired pulmonary function. Experience from different studies has shown that postponing the procedure for too long may be life-threatening. It is therefore advisable to perform the procedure as soon as possible. Fortunately most acute episodes are small in volume, last less than 24 hours, and gradually subside without treatment. Massive hemoptysis has a much worse prognosis, with a mortality rate reported from 50% to 60%.<sup>5</sup>

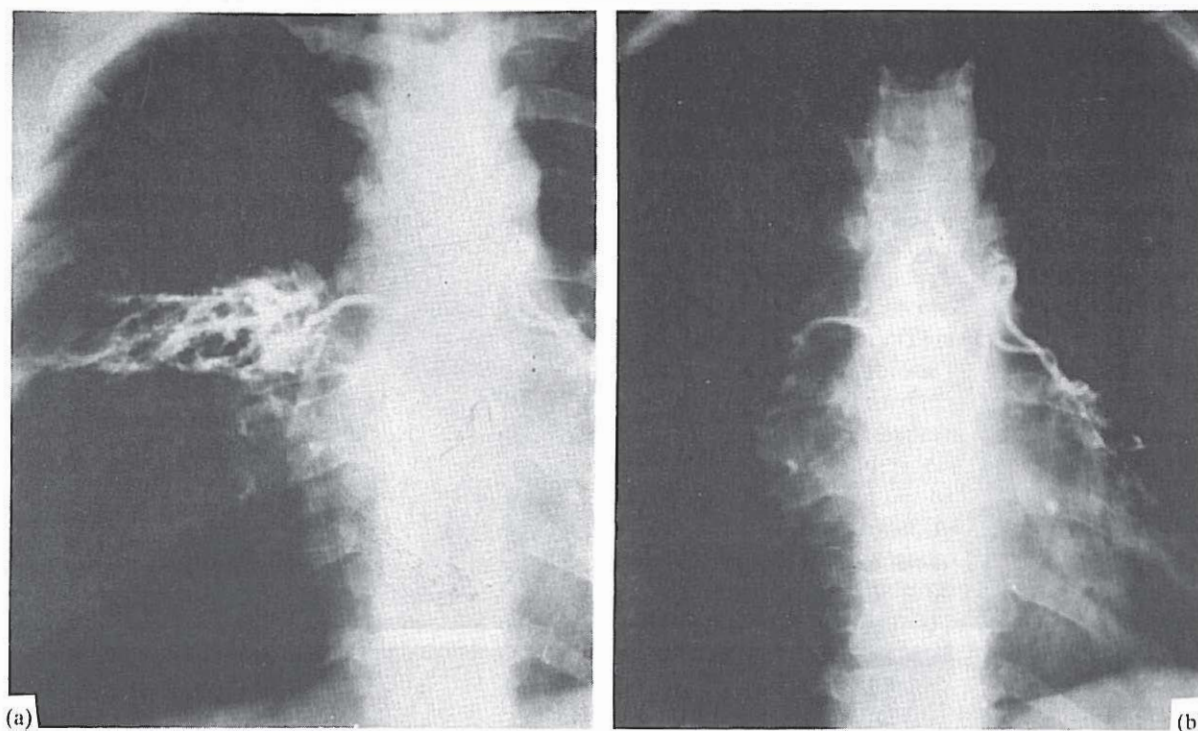
The most common causes of massive hemoptysis include tuberculosis, bronchiectasis, pneumoconiosis, aspergilosis, and bronchial carcinoma (Fig. 3). Tuberculosis was the most frequent pulmonary lesion in my study which included 17 of 27 cases (63%). Other lesions were not common. There was a patient with a 12-month history of recurrent bleeding following pulmonary contusion in the Iran-Iraq war.

Chest radiograph showed a missile fragment, which was adjacent to the left lower bronchial artery in the following bronchial arteriography. The hemoptysis was healed after embolization with no recurrence. In 3 patients (11%) no pathologic lesions were found in pre-embolization evaluation.

Mortality due to hemoptysis will greatly be reduced by using bronchial artery embolization, both in patients who undergo surgery and in those who do not. It is demonstrated that the mortality for pulmonary hemorrhage may be decreased 3 to 5 times compared with that achieved with surgical methods of treatment alone.<sup>2,3</sup> My results in producing hemostasis with transcatheter embolization are comparable to those of other researchers. The immediate hemostasis was achieved in 85% of the patients. 16 patients were followed at least for six months, and recurrent hemoptysis developed in 18.75% of them in the study presented by Uflacker et al. The technique was very effective in the management of life-threatening hemoptysis, and recurrence of bleeding occurred in 21.4% of the cases in a follow-up from one to 47 months. They concluded that recurrence of bleeding may be greatly reduced by bronchial artery embolization alone, and even more by additional use of anti-tuberculosis chemotherapy in patients with active tuberculosis, and surgery in patients with preserved pulmonary function and localized disease.

An understanding of the bronchial and intercostal arteries is essential in percutaneous treatment of hemoptysis. Uflacker et al. evaluated the bronchial





**Fig. 3.** A forty-year-old woman with history of recurrent hemoptysis. (a) Selective angiogram shows a common trunk of bronchial arteries supplying both sides, associated with inflammatory hyper-vascularity of the anterior segment of right upper lobe. (b) Post embolization arteriogram demonstrates complete occlusion of right bronchial artery.

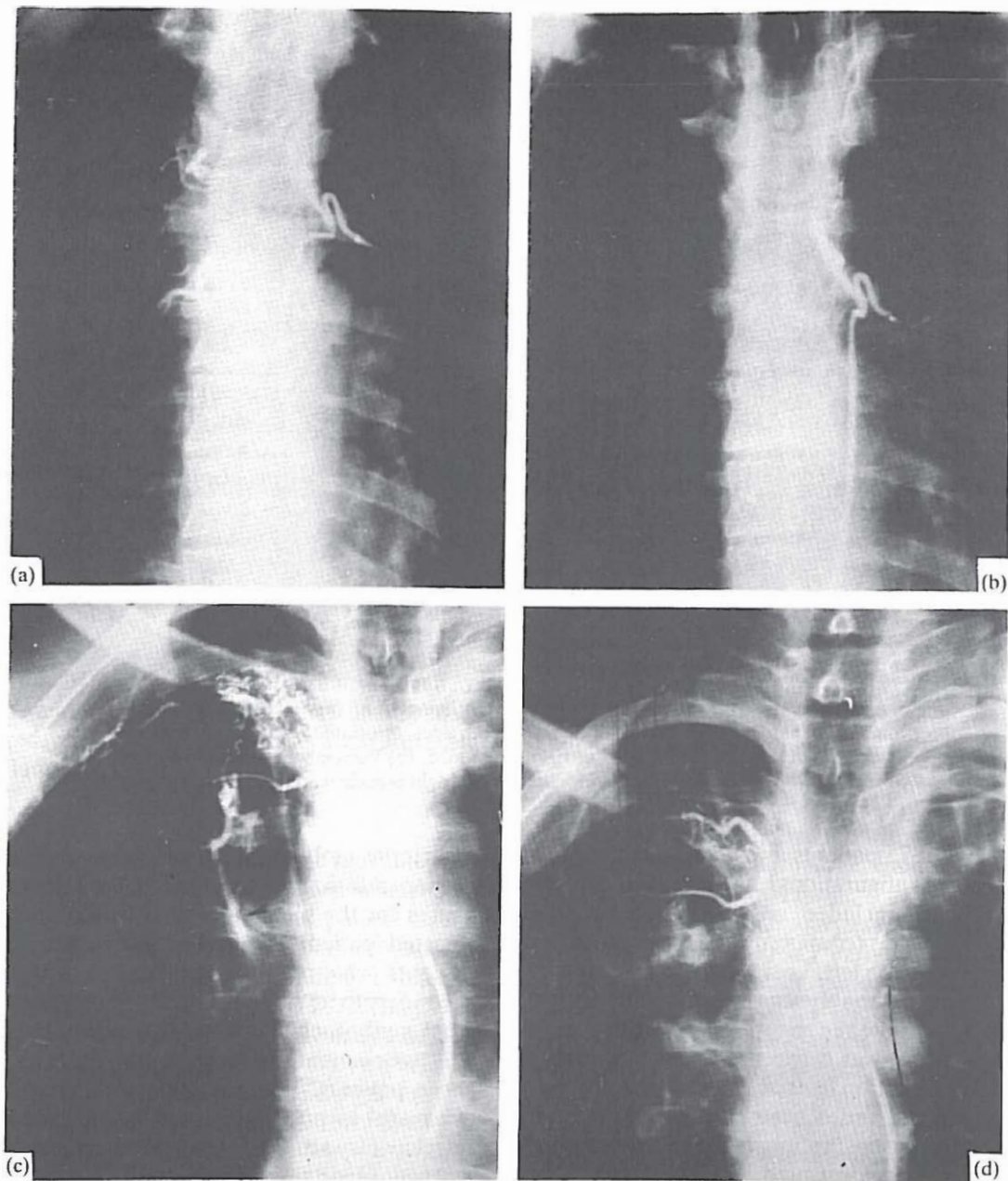
artery anatomy of 75 patients and described 10 different anatomic configurations, the most common (30.5%) of which included an intercostobronchial trunk on the right side (commonly at T5) and a single bronchial artery on the left. Lesions in the right upper lobe were almost invariably supplied by intercostobronchial trunk. Despite the reported rare incidence of common trunk that gives origin to bronchial arteries, they found this condition to exist in about one third of the patients. In the series presented here common trunk was found to be the most frequent anatomic pattern, and was demonstrated in 13 of 27 patients (48%). An intercostal artery was often connected to the right branch of the common trunk.

Hemoptysis in the vast majority of patients originates from systemic arteries.<sup>3,6</sup> The bronchial arteries are almost universally involved. When diffuse pulmonary disease is present, embolization should be extended to all of the bronchial arteries that can be catheterized, but the result is usually poor.<sup>7</sup> Wherever bronchial artery angiography is unable to detect the lesion, the examination should be extended to other systemic arteries which contribute to the perfusion of the lesions (Fig. 4). These arteries change greatly with bronchopulmonary disease and mostly originate from phrenic, intercostal, internal mammary, thyrocervical, and subclavian arteries. In my group of patients, 13 of

47 arteries embolized were intercostal (27.6%). Pulmonary arteriography very rarely will show additional causes for the bleeding, but should be performed in selected patients to find a Rasmussen aneurysm.<sup>7</sup> Patients who require embolization for hemoptysis secondary to tuberculosis have significant contribution from nonbronchial collateral arteries (Fig. 3) Therefore, assessment of collateral arteries are necessary in these patients. The method is believed to be less successful in preventing hemoptysis in patients with intracavitary aspergilloma. These lesions can receive a systemic blood supply from the axillary and the subclavian arteries via pleural adhesions.<sup>1</sup> Embolization of all of these collaterals are usually difficult and time-consuming. Angiographic signs to determine which arteries to be embolized can be primary or secondary. Primary angiographic sign (extravasation of contrast material into bronchi) is an unusual finding. In my group of patients it was present in 2 cases (7.4%). In angiographic evaluation of 20 patients for massive hemoptysis, Keller et al. observed it in only three of patients (15%). Therefore, secondary angiographic signs are more important. These secondary signs are localized hyperemic areas, abnormal hypervascularity, abnormally increased arterial lumen, and interarterial bronchopulmonary shunts (Figs. 2, 4).

Different embolization materials have been used by

## Embolization of Bronchial Artery



**Fig. 4.** (a) Bronchial arteriogram in a patient with residual tuberculosis in the RUL shows the common bronchial trunk. (b) Same artery after successful occlusion with gelfoam particles. (c) Selective injection of the right intercostal artery shows peripheral hypervascularity due to pleural adhesions. A prominent systemic to pulmonary artery shunt is also visualized (arrows). (d) Postembolization image shows occlusion of peripheral branches as well as disappearance of the shunt.

different investigators. Since the goal of embolization in my patients was occlusion of peripheral branches supplying the pathologic lesions with least possibility of complications, small particles of gelfoam or Ivalon were used. To avoid regurgitation of embolization material into the aorta, it is necessary to introduce the catheter precisely into the artery chosen. Gelfoam particles are probably the easiest to handle and are very efficient for bronchial artery embolization. I used this

material in 18 patients (66%). Embolization should start with small fragments and the size of the fragments should increase according to the size of the vessel to be occluded. Gelfoam provides long-lasting occlusion of the bronchial arteries, and when recanalization occurs it is only partial. Polyvinyl alcohol foam (Ivalon), which was used in 9 patients (34%) probably would provide efficient permanent peripheral occlusion.

Bucrylate, Gianturco coil springs, detachable bal-



loons, absolute ethanol, sclerosing agents, and other materials were used by other investigators. Bucrylate has already been used with good results; however, the difficulties in usage and its general inavailability reduce its usefulness.<sup>4</sup> Steel coils and detachable balloons produce only proximal occlusion, and there is some problem in delivering such material into small bronchial arteries. Eventhough absolute alcohol has been used successfully, it is not recommended because of its potential complications such as bronchial necrosis and spinal cord lesions.

Bronchial artery embolization has risks, not only because of the condition of the patient, but also because of the vascular anatomy involved. Most authors agree that the main risk of bronchial and intercostal artery angiography and embolization is ischemic injury to the spinal cord.<sup>4,5,8</sup> This relates directly to the potential anastomotic connections between bronchial circulation and the anterior spinal artery. Radiculomedullary arteries frequently communicate with bronchial arteries through a common intercostobronchial trunk.<sup>4</sup> In the upper and mid-thoracic regions, only one or two of these medullary arteries anastomose with the anterior spinal artery. Consequently, this part of the spinal cord is more vulnerable to ischemic injury. Uflacker et al. demonstrated that radiculomedullary arteries originating from the intercostobronchial trunk were observed in two-thirds of the patients, but the anterior spinal artery was never demonstrated by intercostobronchial trunk or bronchial artery injection. They concluded that the presence of anterior and posterior radicular arteries and posterior spinal arteries on the angiogram is not an absolute contraindication to the bronchial artery embolization. However, when the anterior spinal artery is demonstrated, embolization should be avoided.

There is commonly a conjoined intercostobronchial trunk more often on the right side than on the left, and the right bronchial artery is involved in spinal cord accidents during bronchial artery embolization more often than the left.<sup>2</sup> There have been no reported cases of spinal ischemia following embolization of an isolated left bronchial artery or a common right and left bronchial trunk. Following bronchial and intercostal angiography by Kardjiev et al, all lesions of the spinal cord appeared following the introduction of contrast material into the fifth right intercostal artery. The

neurological symptoms appeared about 2 to 3 hours after completion of the investigation and resembled transverse myelitis. All the patients recovered completely within days or months.

The mechanisms responsible for such changes are not clear, but proposed mechanisms include direct ischemia from catheter occlusion of the spinal artery supply, and neurotoxicity of the contrast agent.<sup>2,8</sup> In case report 1 neurologic symptoms occurred following injection of 60% hyperosmolar Urografin in the fifth right intercostal artery. Therefore, the second mechanism is more acceptable as a toxic factor in ischemic injury to the spinal cord in this special patient. Fortunately the more toxic hyperosmolar contrast agents are off market, and modern classes of contrast media are less likely to produce neurotoxicity.

Even though many authors agree that digital subtraction angiography should be performed prior to embolization to exclude spinal artery supply, in some cases vital cord supply may not be visualized. Recently somatosensory evoked potential (SSEP) have been used to monitor ischemic cord changes following bronchial angiography.<sup>5</sup> This new procedure needs further investigation.

## REFERENCES

- 1- Remy J, Arnaud A, Fardou H, Giraud R, Voisin C: Treatment of hemoptysis by embolization of bronchial arteries. *Radiology* 122: 33-37, 1977.
- 2- Uflacker R, Kammerer A, Neves C, Picon PD: Management of massive hemoptysis by bronchial artery embolization. *Radiology* 146: 627-634, 1983.
- 3- Rabkin JE, Astafjev VI, Gotmal LN, Grigorjev YG: Transcatheter embolization in the management of pulmonary hemorrhage. *Radiology* 163: 361-365, 1985.
- 4- Uflacker R, Kammerer A, Picon PD, et al: Bronchial artery embolization in the management of hemoptysis: technical aspects and long-term results. *Radiology* 157: 637-644, 1985.
- 5- Schrodt JF, Becker GJ, Scott JA, Carroll HW, Benenati SV: Bronchial artery embolization: Monitoring with somatosensory evoked potential. *Radiology* 164: 135-139, 1987.
- 6- Keller FS, Rosch J, Loflin TG, Nath PH, McElvin RB: Nonbronchial systemic collateral arteries: significance in percutaneous embolotherapy for hemoptysis. *Radiology* 164: 687-692, 1987.
- 7- Jardin M, Remy J: Control of hemoptysis: systemic angiography and anastomoses of the internal mammary artery. *Radiology* 168: 377-383, 1988.
- 8- Kardjiev V, Symeonev A, Chankov I: Etiology, pathogenesis, and prevention of spinal cord lesions in selective angiography of the bronchial and intercostal arteries. *Radiology* 112: 81-83, 1974.