

HEMIFACIAL SPASM: A RERORT OF 100 CASES TREATED BY MICROVASCULAR DECOMPRESSION

M. FARAJI, M.D. , B. HERMANS, M.D., AND M. SAMII, M.D.

From the Department of Neurosurgery, Ghaem Hospital, Mashad University of Medical Sciences, Mashad, Islamic Republic of Iran, and the Department of Neurosurgery, Nordstadt Hospital, University of Hannover, Hannover, Germany.

ABSTRACT

100 patients with hemifacial spasm treated by microvascular decompression are presented. There were 60 females and 40 males. Their ages ranged from 29 to 75 years with a median age of 54 years, and the left side was involved predominantly. The common focal signs were facial nerve palsy in 41 cases, diminished hearing in 14 cases, trigeminal neuralgia in 11 cases, and homolateral trigeminal neuralgia in four cases.

All of the patients underwent a lateral suboccipital craniectomy. In 96 cases of manifest vascular compression, the vessels were released and isolated from the facial nerve using muscle. In those cases where veins, adhesions, arachnoidal bridging or A.V.M. were responsible, the etiological factor was approached.

The results of our patients are comparable with those reported by other authors. The mortality rate was 2%.

MJIRI, Vol.5, No. 1,2, 15-18, 1991

INTRODUCTION

Based upon the original observations of Dandy and Janetta as well as the works of several other authors, microvascular decompression of the facial nerve at the root-entry zone in the cerebello-pontine angle is the treatment of choice for hemifacial spasm.^{4,5,12,13} This procedure thus affords not only the opportunity to relieve the spasm without an intentional neurologic deficit, but also allows us to deal directly with the etiologic factor (i.e. removing a small neoplasm or obviating structural abnormalities).^{9,10} However, the operative technique, although now part of the neurosurgical routine, requires proficiency with microsurgical techniques.^{6,12,14} According to the initial results of Janetta reported between 1966 and 1970, we started to perform the microvascular decompression operation for cranial rhizopathies. This report is our experience during the period from 1979-1990 and comprises 319 patients treated by this procedure; 100 suffering from hemifacial spasm.^{3,15,16}

MATERIAL AND METHODS

We analyzed 100 patients who had sustained hemifacial spasm and were treated in our neurosurgical clinic. All these patients underwent an intensive neurological and paraclinical screening exam to rule out other causes of hemifacial spasm. A review of the patient population and clinical presentation is summarized in Tables I and II.

Table I. Hemifacial spasm treated by microvascular decompression

Patient population (n=100)			
Sex	Female	Male	
	60	40	
median age	54.95 years	53.60 years	
maximum age		75	
minimum age		29	
average duration of symptoms:	6.5 years		Max. 25 Yr Min. 1 Yr
distribution of involved side:		Left 57 Right 41 Both 2	

Hemifacial Spasm

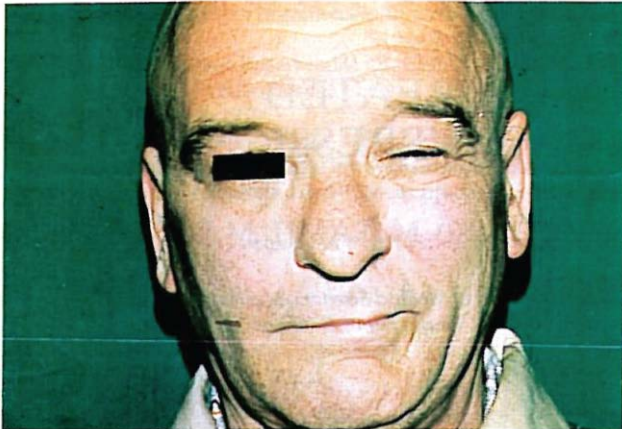


Fig. 1. Hemifacial spasm of the left side of the face.

Table II. Clinical presentation

paresis of the facial nerve	41
diminished hearing	29
trigeminal hypoesthesia	14
tinnitus	11
trigeminal neuralgia	4

Our patient population included 60 females and 40 males with ages ranging from 29-75 years and a median age of 54 years. The left side was the predominantly involved side (Fig. 1). The other major accompanying neurological defects were 41 facial nerve palsies, 29 cases of diminished hearing, 14 cases of trigeminal hypoesthesias, 11 cases of tinnitus, and four cases of homolateral trigeminal neuralgia.

All of the patients underwent a lateral suboccipital craniectomy of approximately 2.5×3.5 cm in diameter. Exploration of the cerebello-pontine angle and the root-entry zone of the facial nerve was carried out. The exploratory findings are summarized in Table III.

Except in those cases where a venous component was also involved in the compression (in which case the vessel was coagulated), those with adhesions, arach-

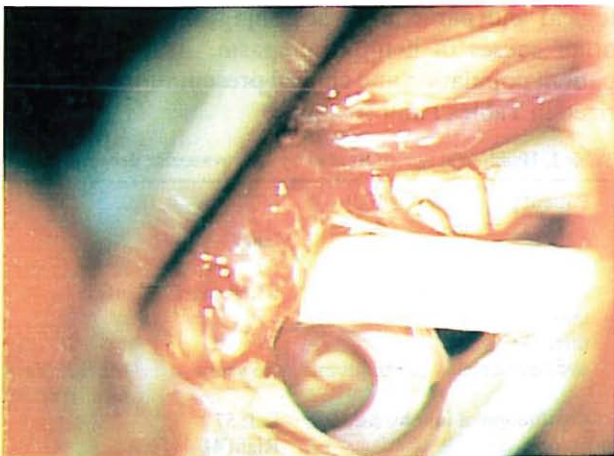


Fig. 2. Facial nerve compressed by AICA.

Table III. Operative findings (n=100): compressing factors

AICA	52
PICA	15
AICA & PICA	5
AICA & Vertebral Artery	12
PICA & Vertebral Artery	6
AICA & PICA & Vert.Ar.	1
Vertebral Artery	4
Vein	1
AVM	1
Arachnoidal Adhesions	3

noidal bridging or arm, the etiological factor was approached.

RESULTS

The results are summarized in Tables IV and V.

In the 96 cases of manifest vascular compression, we released the vessels and isolated them from the facial nerve with a piece of muscle (Fig. 2-3).

As seen, the results were divided into early-and late post-operative results. The early post-operative results encompass the time from operation until the hospital discharge. For the late post-operative results, we evaluated the follow-up information of 83 patients during a follow-up time ranging from two months to 10 years (mean 4.12 years). 17 patients could not be contacted for follow-up at the time of review and four were excluded due to incorrect responses to questions of the information sheets.

Upon discharge, 57 of the 100 operated patients

Table IV. Early post-operative results

excellent	57
good	41
poor	2
n=100	

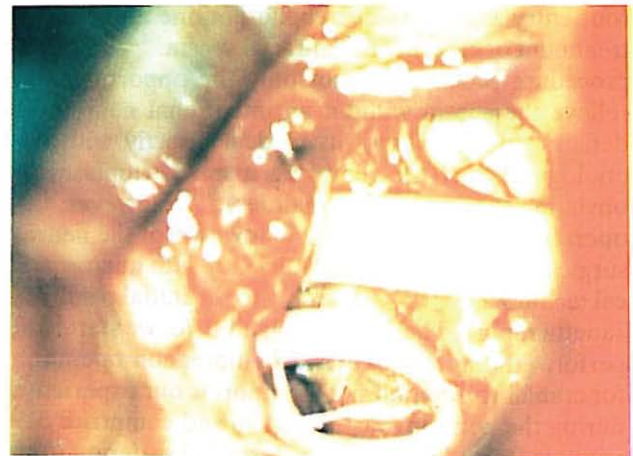

Fig. 3. Facial nerve separated from AICA by a piece of muscle.

Table V. Late post-operative results (n=83)

Follow-up possible in 83 cases (2 months-10 years)			
Average time of follow-up 4.12 years			
excellent	65	78.31%	
good	11	13.25%	
poor	3	3.61%	
no correct answer	4	4.82%	
29 patients with a progression post-op: good :excellent (28 weeks, 3 cases within 1 year)			
Patients with recurrence:	minor recurrence	8	9.63%
	major recurrence	1	1.20%

had complete relief of the hemifacial spasm, 41 patients had an objective and subjective acceptable improvement of the spasm. In two cases, there was no change in the clinical picture.

In the long term follow-up observations and collected information of 83 patients, there were 65 patients (78.31%) with complete relief of hemifacial spasm, 11 patients (13.25%) still referred with hemifacial spasm though less than before the operation, and in three cases (3.61%) the operation failed. During the follow-up interval, 29 patients had a progression from good to excellent in a period from 2-8 weeks after discharge (three cases within one year). There was a recurrence of the spasm compared with the direct post-operative result in 10.83% of the cases. In eight patients, the recurrence was minor and one patient developed a complete recurrence.

Our mortality rate was 2%. One patient died due to pulmonary complications 30 days after operation and in one case, the cause remained obscure, even after autopsy.

As far as morbidity is concerned, we have summarized our findings in Table VI. Regarding hearing function, we must mention that due to the anatomic relations of the VIII cranial nerve, post-operative hearing deficits may occur frequently including deafness.

DISCUSSION

Hemifacial spasm is one of the so-called hyperactive dysfunction syndromes of the cranial nerves. Based upon the original observations of Dandy and Janetta and later clinical and experimental work by others, the pathogenesis of these hyperactive dysfunction syndromes is accepted to be compression of these nerves at the root-entry zone in the cerebello-pontine angle. The leading cause of compression is vascular, mostly arterial loops. Nevertheless, compression is also possible in the case of malformations, tumors, arachnoidal bridgings, etc.^{1,3,4}

Compared to the observations first noted by Saun-

Table VI. Post-operative complications

	Initial	Permanent
Wound healing	6	0
Aseptic meningitis	2	0
CSF leak	11 (operative revision in 2 cases)	0
Trigeminal hypoesthesia	4	0
Facial paresis	4	0
Tinnitus	17	13
Diminished hearing	26/deafness ⁷	17
Vestibular & cerebellar symptoms	25	6
Cerebellar haemorrhage	2	
Cerebellar infarction	1	
Torticollis	1	
Mortality	2 ^{1 case 30 days post-op pneumonia}	1 case cause unclear

ders, et al, in all these syndromes, a loss of function may gradually supervene in the prolonged course of the illness so that the early hyperfunction is accompanied by and later changed by a hypofunction of the pertinent cranial nerve. This is certainly true for the facial nerve, when careful neurological examination showed a mild peripheral facial weakness. Pre-operative EMG data in our patients showed evidence of denervation as well as changes due to overactivity.^{7,8}

The EMG results gradually returned to normal after operation in the majority of our patients where a pre-op facial palsy could be observed. In about 100 patients with hemifacial spasm presented and treated in our clinic, in 96 cases we found the compression to be of vascular origin. After pre-operative screening, these patients underwent a micro-vascular decompression via a posterior fossa craniectomy.

The results of our patients shown in Tables IV and V are comparable with series reported by other authors. In the immediate results, we had a complete response in 57% (Janetta 58%), a partial response in 41% (J 39%), and no response in 2% (J 3%). In the late follow-up we had a complete response in 78.31% (J 84%), a partial response in 13.25% (J 5%) and no response in 3.61% (J 6%). Considering the results achieved by microvascular decompression techniques as well as the positive subjective feedback regarding the operative procedure from the patients in our series (82%), we consider the decompressive procedure the indicated therapy after corresponding screening in patients suffering from this socially isolating picture.

REFERENCES

- 1- Apfelbaum RI: A Comparison of percutaneous radiofrequency trigeminal neurolysis and microvascular decompression of the trigeminal nerve for the treatment of tic douloureux. *Neurosurgery* 1:16-21, 1977.
- 2- Brackmann DE: Bell's palsy: incidence, etiology and results of medical treatment. *Otolaryngol Clin North Am* 7:357-368, 1974.

Hemifacial Spasm

- 3- Campbell E, Keedy D: Hemifacial Spasm: a note of the etiology in two cases. *J Neurosurg* 4:342-347, 1944.
- 4- Dandy WE : The treatment of trigeminal neuralgia by the cerebellar route. *Ann Surg* 96:787, 1962.
- 5- Dandy WE : Concerning the cause of trigeminal neuralgia. *Am J Surg* 24:447-455, 1934.
- 6- Dandy WE : Trigeminal neuralgia and trigeminal tic douloureux. In: Walters W, Ellis EH Jr, eds. *Lewis Practice of Surgery*. Hagerstown MD, WFPrior Co, pp. 167-187, 1963.
- 7- Gardner WJ : Concerning the mechanism of trigeminal neuralgia and hemifacial spasm. *J Neurosurg* 19:947-957, 1962.
- 8- Grundy BL , Jannetta PJ, Lina A, et al : BAEP monitoring during cerebellopontine angle surgery. *Anesthesiology* 55:A 127, 1981.
- 9- Hankinson HL, Wilson CB : Microsurgical treatment of hemifacial spasm. *West J Med* 124:191-193, 1976.
- 10- Jannetta PJ : Microsurgical exploration and decompression of the facial nerve in hemifacial spasm. *Curr Top Surg Res* 2:217-220, 1970.
11. Jannetta PJ: Neurovascular compression of the facial nerve in hemifacial spasm: relief by microsurgical technique. In Meri FT, ed *Reconstructive Surgery of Brain Arteries*. Budapest. Publishing House of the Hungarian Academy of Science. pp: 193-199, 1974.
- 12- Jannetta PJ : Observations on the etiology of trigeminal neuralgia, hemifacial spasm, acoustic nerve dysfunction and glossopharyngeal neuralgia: definitive microsurgical treatment and results in 117 patients. *Neurochirurgia* 20: 145-154, 1977.
- 13- Jannetta PJ : Neurovascular compression in cranial nerve and systemic disease. *Ann Surg* 192:518-528, 1980.
- 14- Jannetta PJ , Abbasy M, Maroon JC , Morales Ramos F, Albin M S: Hemifacial spasm: etiology and definitive microsurgical treatment. Operative techniques and results in forty-seven patients. *J Neurosurg* 47: 321-328, 1977.
- 15- Moller AR, Jannetta PJ : Microvascular decompression in hemifacial spasm: intraoperative electrophysiological observations. *Neurosurgery* 16:612-615, 1985.
- 16- Petty PG, Southby R: Vascular compression of lower cranial nerves: observations using microsurgery with particular reference to trigeminal neuralgia. *Aust N Z J Surg* 47:317-320, 1977.