



## Original Articles

# VASCULAR ACCESS FOR HEMODIALYSIS: OUR EXPERIENCE WITH 3337 CASES

MOHAMMADREZA KALANTAR MOTAMEDI, MD, FACS

*From the Department of Surgery, Shohada Medical Center, Shahid Beheshti University of Medical Sciences, Tehran, Islamic Republic of Iran.*

### ABSTRACT

Over a seven year period from 1982 to 1989, 3337 conduits were created in 3137 patients with end stage renal disease (ESRD) as access for chronic dialysis. These included 2690 side-to-side arteriovenous fistulae (AVF), 168 end-to-side AVFs, 10 autogenous vein grafts, 51 homogenous frozen vein grafts, 109 polytetrafluoroethylene (PTFE) grafts, 209 emergency external arteriovenous shunts, three dual-lumen catheter placements with dacron felt cuff in the superior vena cava and 13 miscellaneous vascular access procedures.

Our favorite site for creation of AVFs along with satisfactory patency rates for as long as seven years are demonstrated for all types of fistulae and PTFE grafts by life-table analysis.

Early failure of AVFs usually occurred in the postoperative period due to hypotension, and late failures were due to improper use of the vein during dialysis.

Thrombosis was the cause of the majority of the PTFE graft failures, even though we had four cases of infection more than one year later and one case of seroma formation due to weeping of the graft. False aneurysm formation and secondary bleeding requiring repair were the major complications of PTFE grafts.

Autogenous or frozen banked homogenous vein graft failures were mainly due to gradual fibrosis and narrowing and eventual thrombosis, while we did not have infection or false aneurysm formation or any other complication with them.

*MJIRI, Vol. 4, No. 4, 241-246, 1990*

### INTRODUCTION

The introduction of extracorporeal dialysis in 1943 by Kolff, et al and introduction of the external A.V.

shunt by Quinton, Scribner, et al in 1960 and the endogenous fistula by Brescia, Cimino, et al in 1966 provided the means whereby patients with ESRD could survive.

#### *Editor's note:*

*This article is probably one of the most complete reviews ever published on the different methods and means of creation of vascular access for chronic dialysis.*

*The author has made an effort to present all the technical hints and do's and don'ts which will enable the reader to have a thorough understanding for successful creation of a proper vascular access for chronic dialysis.*

Approaches which permitted repeated and routine access to the circulation were not limited to these and the introduction of synthetic vascular prostheses and autogenous grafts brought about a greater choice of procedures, especially for use in long-term patients who have exhausted peripheral venous sites or in some patients with systemic diseases like lupus erythematosus who do not have proper veins to begin with.<sup>1,2</sup>

The recent use of frozen homogenous vein grafts and double lumen catheters with dacron felt cuff have tremendously improved our choice of procedures.<sup>9</sup>

If the distal arm vessels of an individual being initiated on hemodialysis are satisfactory, our first choice is creation of an endogenous AVF at the *navicular fossa*, followed in decreasing order of preference by the wrist, forearm, antecubital fossa, and knee (distal sapheno-popliteal artery fistula).

If the patient's own vessels are unsatisfactory or have been exhausted, a synthetic prosthesis or a frozen banked vein graft is used.

For emergency situations or while waiting for a fistula or graft to become ready for use, an external A-V shunt is used if satisfactory veins are available, otherwise a double-lumen catheter with dacron felt cuff is placed in the superior vena cava via the jugular vein.<sup>4</sup> This is also used when the patient is hypotensive and a fistula may not remain patent.

This report summarizes our experience with different vascular access procedures in dialysis performed over the past seven years at the Shahid Hasheminejad hospital on patients with ESRD. The natural history of each type of access considering the site of creation of each, the causes of failure, and result of revisions performed on failed accesses are examined.

## MATERIAL AND METHODS

Between March 1982 and Sep. 1989, 3337 arteriovenous conduits were created in 3137 patients with ESRD as access for chronic dialysis. The procedures included establishment of 2690 side-to-side AVFs, 168 end-to-side AVFs, 10 autogenous vein grafts, 51 homogenous frozen vein grafts, 109 PTFE grafts, 209 emergency external A.V. shunts and 13 miscellaneous procedures.

The 209 external shunts were used mainly in emergency cases during the time interval required for maturation of the fistulae or PTFE and vein grafts to become ready for use (maximum four weeks).

There were 135 revisions for reversed fistulae due to thrombosis of the proximal veins and 24 thrombectomies from clotted PTFE grafts.

There were 1511 males and 1626 females, with age ranging from four to 76 years (mean 43±15) in our

series.

The type of graft used or techniques of placements and the site of creation of fistulae were almost independent of the patients' age, sex or presence of underlying disease and the only determining factors were the size and presence of proper vein and arteries in the proper site. The exceptions were patients with SLE and technique of placement of PTFE grafts in children. For patients in the growing age we did not use PTFE grafts in straight fashion, such as from the groin to the popliteal region or from the elbow to the axilla to allow for the extremity to grow. In patients with SLE we rarely used AVFs, and in the few cases they were rarely at the navicular fossa, wrist or forearm region. These patients were mainly managed by insertion of a vein graft preferentially to PTFE. The arterial end of the graft was anastomosed to the brachial or femoral artery and the venous end to the axillary or popliteal vein.

Since we were the major referral hospital in the country, all the failures of other centers were sent to us, and since most of these patients had multiple previous procedures which had failed, we were very limited in the choice of available sites for creation of the fistulae.

All vascular access procedures were performed by the author either primarily or assisting a surgical resident or fellow. The techniques used and the philosophy of placement (the most distal insertion in the arm, for as long as possible in the most accessible and comfortable location for the patient) were relatively standard and similar in all cases.

## DISCUSSION

In general, side-to-side A.V. fistulae were created at the navicular fossa, wrist and antecubital fossa, in order of priority, under local anesthesia (except in very small children who would not cooperate). Synthetic grafts were placed under epidural, spinal, general or local anesthesia at more proximal levels, usually from the antecubital fossa to the axilla or the popliteal fossa to the groin or in the form of a «U» (loop configuration) at the antecubital, groin or thigh region.

General anesthesia was necessary in cases who failed to achieve adequate sensory loss with regional anesthesia.

The non-dominant upper extremity was used preferentially. Fistula placement in the lower extremity was avoided mainly for the patients' convenience.

Table 1: patency rate of AVFs, one month after placement.

| Side-to-side: 2690<br>End-to-side: 168 | total failures | patency rate |
|--|----------------|--------------|
| Total 2858                             | 12             | %99.6        |



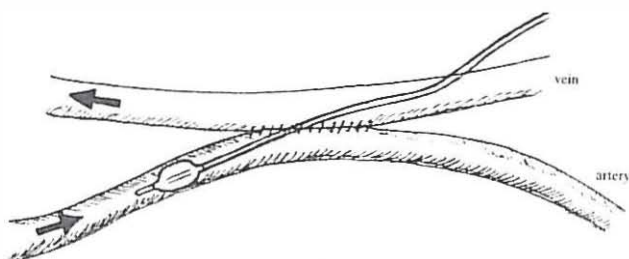


Fig. 1. Simple thrombectomy via distal limb venotomy.

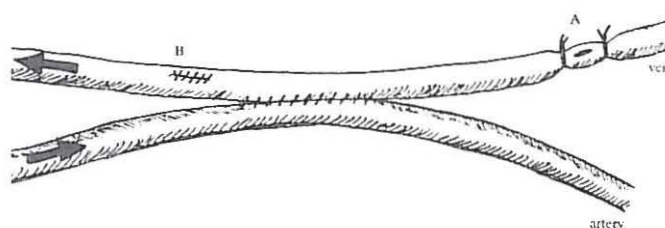


Fig. 2. Ligation of distal limb on both sides of venotomy (A) or repair of proximal venotomy site (B).

whereas for the sapheno-popliteal anastomosis or PTFE grafts this was the main site due to unavailability of proper sized veins in the antecubital region.

Patency rates for all vascular accesses were analyzed by life table analysis. Access failure was defined as replacement of a failed access by a new one.

#### A. V. fistulae

The overall patency rates for 2858 AVFs are shown in Table I.

There was significant immediate filling of the veins and a short time period required for maturation when fistulae were created in the navicular fossa in comparison to cases in which the fistula was created at the wrist or the antecubital fossa. The longest time period required for maturation was for those fistulae created in the antecubital fossa, in which as long as several months were required in some of the patients for maturation.

There was no difference in the patency rates of endogenous fistulae placed at the navicular fossa, wrist or antecubital fossa which were followed for 3-60 months. Most failures occurred within the first few days due to hypotension. In the later months, the failures encountered were mainly due to injury to the vein during dialysis.

Generally it was necessary to replace a failed cimino A.V. fistula with a new fistula in the other extremity or at a more proximal location. However, 44 fistulae which were clotted due to hypotension or unknown reasons successfully underwent thrombectomy when attended to within 48 hours. In cases in which the cause of failure was the unusually small size of the artery or vein (less than 1mm in diameter), no attempt was made for thrombectomy or revision (one case).

We did not use grafts unless all efforts had failed and sites for creation of fistulae were exhausted.

Post-dialysis hypotension and a constant low blood pressure causing a low-flow state and peripheral vasoconstriction were the cause of the majority of the thromboses of the fistulae. Simple thrombectomy using a small venotomy (preferably in the distal limb of a side-to-side AVF) was usually all that was needed in these patients (Fig. 1). This was followed by 24-48 hrs of anticoagulant therapy with heparin. The vein was

either repaired in case the venotomy was done over the proximal limb or ligated in case of distal limb venotomy (Fig. 2).

Localized aneurysmal dilatations of the veins or discrete areas of venous stenosis accounted for a more proximal placement of the fistula. Similarly if an aneurysm of a fistula became bothersome due to enlargement or incipient skin breakdown due to pressure necrosis, the feeding vessel to the aneurysm was ligated and a new fistula fashioned more proximally or in the other arm.

We had no case of postoperative infection with the cimino fistulae.<sup>3</sup> Subsequent localized infections at the dialysis needle site were treated with antibiotics and local care.

The cumulative patency rate of cimino fistulae that had successfully undergone thrombectomy or revision was equal to that of unrevised fistulae.

#### PTFE grafts

The long-term patency rate of PTFE grafts was significantly less than that for endogenous fistulas,<sup>5,6</sup> even though we had only one postoperative failure with PTFE grafts due to hypotension after dialysis (99.1% patency). Since most of these grafts were placed between the femoral artery and femoral vein in a loop fashion<sup>7</sup> or between the popliteal artery and femoral vein in a straight fashion, the cause of failure could not be attributed to inadequacy of venous drainage or arterial inflow.

Patients in this category invariably represented a group in which several previously created accesses had failed and there was no possible means of creation of a new cimino fistula.

Table II. Complications of PTFE grafts

| Complication                | No. | Percentage |
|-----------------------------|-----|------------|
| Thrombosis                  | 18  | 62.1%      |
| Infection                   | 4   | 13.8%      |
| Pseudoaneurysm and bleeding | 5   | 17.2%      |
| Weeping                     | 1   | 3.4%       |
| Stenosis                    | 1   | 3.4%       |

**Complication of PTFE grafts**

There were 29 instances of complications occurring in 20 patients of the 109 grafts implanted (Table II).

**Thrombosis:**

This was responsible for 62.1% of the complications. Patency was reestablished at least temporarily in 75% of these cases by simple thrombectomy through a transverse incision made over the graft, but recurrent thrombosis was common.

**Infection:**

We had four cases of graft infection. One was associated with massive bleeding and thus was counted in both complications. In case of infection the graft should be excised in its entire length and the artery and vein should be repaired. In all cases, another PTFE graft or a homogenous frozen vein graft was used in the other limb.

**Pseudoaneurysm and bleeding:**

This was the second most common complication (five cases). Two of these finally ended in graft failure or massive hemorrhage. The graft was salvaged by repair of the hole (with 6-0 prolene to stop the bleeding) and approximation of the skin.

**Graft weeping:**

An amazing complication not so far reported was seen in one case. The graft was weeping plasma which was coagulating around the graft under the skin. We removed this collection once but since it formed again, we had to remove the graft and replace it with another PTFE graft.

**Stenosis of the arterial anastomosis:**

This was the cause of one of our graft failures.

**Operative technique and choice of operation**

Our philosophy for selection of the fistula site is:

- 1) priority of upper extremity over the lower extremity.
- 2) priority of non-dominant hand over the dominant one.
- 3) staying as distal as possible for as long as possible.

**Technical hints**

- 1) We should see or feel a vein which is not obstructed proximally close enough to the artery to perform an anastomosis without tension.
- 2) The arterial pulse at the site of anastomosis should be palpable by hand.
- 3) Mobilization of the vein should be kept to a minimum in order to maintain vasa vasora to the vein wall. This will preserve secretion of prostacycline from the intima and will enable us to make successful fistulae in vessels as small as 1mm in diameter.

The best place which meets all the requirements mentioned above is the *navicular fossa*, which is our recommended first choice, since there is no need for mobilization of the vein at all. After making a longitudinal incision over the skin at the navicular fossa, we approach the artery from the medial (ulnar) side of the vein.

The artery is then exposed for a length of 1cm, preserving all of its branches. Control of the vein, artery and its branches is with silk # 0 or # 1 going around them twice, or an atraumatic microvascular clamp (we prefer clamps for radial artery and silk for the arterial branches and the cephalic vein itself).

Here the artery rests exactly under the vein so we make the venotomy on the under surface of the vein and arteriotomy over the superior surface of the artery. The arteriotomy and venotomy are 5-7 mm in length longitudinally. A side-to-side anastomosis is fashioned with # 7-0 prolene with an 8mm needle. While making the anastomosis the intima of the artery or vein should not be grasped with forceps to prevent intimal injury. This is especially important when dealing with smaller vessels (size 1-2 mm diam).

No local or systemic anticoagulation is required and after removing the clamps, there is immediate filling of the vein and there should be no displacement of the vein at the anastomotic site.

When there is no palpable pulse at the navicular fossa or the size of the vein is less than 1mm or has been thrombosed, the next choice is just above the wrist.

The incision is made over the cephalic vein longitudinally. From the ulnar side of the vein, we approach the artery (radial), retracting all the soft tissues away and up, and approach the lateral side of the radial artery, thus decreasing the distance between the artery and vein to a minimum. This will decrease the amount of mobilization of artery and vein for having a side-to-side anastomosis without tension.

If the distance between the vein and artery does not allow a side-to-side anastomosis without tension, an end-to-side anastomosis is our next choice (Fig. 3.A). We prefer this to H-vein graft using a short segment of vein graft between radial artery and cephalic vein (Fig. 3.B).<sup>8</sup>

We also do not recommend anastomosing the end of the artery to the side of the vein because it sacrifices the artery and failure of the procedure will cause thrombosis of the artery thus making a more proximal fistula impossible.

If there is no usable vein or artery up to the mid-forearm, our next choice is creation of a fistula at the antecubital fossa. Through an oblique incision where the artery and vein are the closest, the communicating vein or basilic or cephalic vein (which ever is closer) is adequately mobilized and a side-to-side anastomosis is fashioned. The valves of the superficial



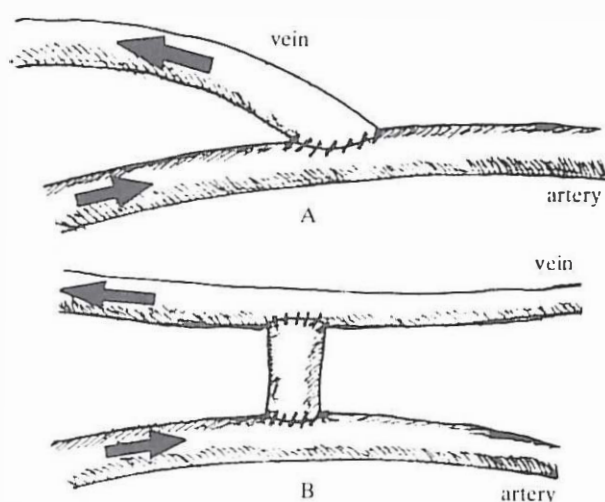


Fig.3.A. end-to-side anastomosis of vein to artery. B.H-vein graft.

veins distal to the anastomosis should be destroyed to allow retrograde flow and earlier maturation of the fistula. This is not necessary and even dangerous if we have to make the anastomosis between the brachial artery and brachial vein in cases in which none of the above-mentioned veins are available.

When the distance between the vein and artery does not allow a side-to-side anastomosis without tension, then an end-to-side anastomosis should be fashioned. After destroying the distal valves, the distal end of the vein is anastomosed to the side of the artery, allowing retrograde filling of the veins.

If all the superficial veins are thrombosed, then we do not recommend creation of fistula between brachial vein and artery since it will take a very long time to develop usable veins for dialysis and sometimes arm edema or blue discoloration (cyanosis) of the fingers occur, forcing you to close the fistula, otherwise gangrene of the fingers will follow.

When there is no way of creation of fistula in the upper extremity, our next choice is creation of an A-V fistula between the saphenous vein and popliteal artery. The saphenous vein is transected slightly below the knee and its proximal end is anastomosed to the side of the popliteal artery.

We do not recommend creation of AVF below the knee or in the ankle region.

In cases in which no available site for creation of cimino fistula is present, we then consider using a homogenous frozen vein graft or PTFE graft. In these instances since there is no vein available at the antecubital region (otherwise we would have fistula) loop configuration of graft is impossible. Therefore for upper extremity, we almost always use homogenous frozen saphenous vein graft harvested during vein ligation and stripping of patients with varicose veins.

There has been no rejection of the graft since it has lost its antigenicity during ordinary freezing.

is anastomosed end-to-side to the brachial artery at the antecubital fossa then is routed through a very superficial tunnel under the skin to the distal portion of the axillary vein. These vein grafts are ready for use within a one month period. The size is much smaller than PTFE grafts and cosmetically better accepted by women and it feels like the patients' own veins.

In cases who do not have a good brachial artery or axillary vein or distal pulses are absent and if brachial artery is used for vein graft it may cause distal ischemia, our next choice is PTFE graft at the thigh.

We have used this between popliteal artery and femoral vein or in a loop configuration between femoral artery and vein. The latter is especially suitable for growing children because it does not cause any problem as the child grows. The straight graft can be placed between femoral artery and popliteal vein even though the latter sometimes causes a transient edema of the leg. The technique is exactly like femoropopliteal bypass used for ischemic legs except that it is passed through a very superficial tunnel just beneath the skin.

#### Double lumen catheter

In patients with low blood pressure in whom no vascular access can remain patent or in cases whom we have to wait long to have matured fistula, we have used double lumen catheters with Dacron cuff. This is placed in the right atrium or superior vena cava via the external or internal jugular vein. The exact positioning of the tip is checked at the time of operation by fluoroscopy. The Dacron cuff should be about 1cm from the skin opening which should be below the clavicle over the anterior chest wall.

#### Scribner shunt

This was used only temporarily while awaiting for an internal fistula to mature or for temporary hemodialysis in patients with acute tubular necrosis. This was mainly placed between the posterior tibial artery and saphenous vein at the ankle or between the anterior tibial artery and saphenous vein. In children with small arteries this was done between a branch of the deep femoral artery and saphenous vein at the groin region.

We hope that some day we can do without this external Scribner shunt because we have to sacrifice an artery and a good vein which are both valuable in the future for the patient.

#### REFERENCES

- 1- Landmann J: Arteriovenous fistula for chronic hemodialysis. *Helv Chir Feb*; 54 (5): 603-10, 1988.
- 2- Palder SB, et al: Vascular access for hemodialysis. Patency rates and results of revision. *Ann Surg Aug*; 202 (2): 233-9, 1985.

## Vascular Access

- 3- Porter JA, et al: Complications of vascular access in a dialysis population. *Curr Surg Jul-Aug*; 42 (4): 298-300, 1985.
- 4- Schwab SJ, et al: Prospective evaluation of a Dacron-cuffed hemodialysis catheter for prolonged use. *Am J Kid Dis Feb*; 11 (2): 166-9, 1988.
- 5- Rizzuti RP, et al: Extended patency of expanded PTFE grafts for vascular access using optimal configuration and revisions. *Surg Gynecol Obstet Jan*; 166 (1): 23-7, 1988.
- 6- Reju S: PTFE grafts for hemodialysis access. Techniques for insertion and management of complications. *Ann Surg Sep*: 123 (9): 1169-72, 1987.
- 7- Slater ND, et al: An evaluation of expanded PTFE loop grafts in the thigh as vascular access for hemodialysis in patients with access problems. *Ann R Coll Surg Eng Jul*; 70 (4): 243-5, 1988.
- 8- Hylander B, et al: Interposition graft fistulas for hemodialysis. *Acta Chir Scand Feb*; 154 (2): 107-10, 1988.
- 9- Halevy A, et al: Frozen saphenous vein allograft for constructing vascular access for hemodialysis. *Isr J Med Sci Jan*; 24 (1): 13-4, 1988.