

## TRANSURETERAL LITHOTRIPSY

ABBAS BASIRI, M.D., NASSER SIMFOROOSH, M.D., AND  
S. VAHIDI, M.D.

*From the Dept. of Urology, Labbafi-Nejad Medical Center, Shahid Beheshti University of Medical Sciences, Tehran,  
Islamic Republic of Iran.*

### ABSTRACT

From Sep. 1984 to Aug. 1990, 99 patients were treated for ureteral stone using the ureteroscope.

In five patients ureteroscopy was repeated for a second stone. In one patient the procedure was diagnostic in nature and in the rest of the patients it had a curative value. In 60 patients the stone was removed by electrohydraulic and basket combination and in 25 cases, dilatation alone was enough.

Rate of success was 84.6%, with a 10% rate of complications. We conclude that TUL is the treatment of choice for ESWL-resistant stones or in patients with ureteral anomalies.

*MJIRI, Vol. 4, No. 4, 247-252, 1990*

### INTRODUCTION

The ureter is a common place for stone presentation, and is usually accompanied with severe clinical symptoms. There has been little progress in medical prevention, and surgical treatment has always had its own complications which are worse on second operation. Non-surgical treatment has always been the aim and eventually in 1929, Young and McKay managed to introduce a pediatric cystoscope into the ureter in a boy with posterior urethral valve.<sup>1</sup> They pioneered the idea that one can extract a ureteral stone using a small cystoscope. Although for 55 years ureteroscopy had a common use in female patients, it was not until 1979 after developing the ureteroscope that the first ureteric stone was removed via endoscopy and TUL took shape.<sup>2</sup>

### MATERIAL AND METHODS

In the past six years, 99 patients, 67 male and 32 female, were treated by TUL, the main complaint being flank pain with duration of one week to three years. In 24 patients, the stone was above the pelvic rim and in 75, the stone was placed below the pelvic rim. The average size of the stones was 17×7mm.

All those who developed complications were admitted, and the rest were discharged after the procedure.

All patients received 1g IV cephalothin which was continued for the following two days postoperatively. The procedure was carried out under general anesthesia. A number 21 Fr cystoscope was used to locate the ureteric orifice and then a number 0.38 inch guidewire was passed and dilator balloon was fed in over the guidewire. Ureteric orifice was dilated up to 18 Fr (6mm). It was made sure that the whole length of the balloon (4 cm) was inserted, and then inflated by injecting fluid so that the entire length of the intramural ureter, the orifice and hiatus are properly dilated. Although some reports indicate that dilatation should be gradual to avoid submucosal hemorrhage and stricture in the long run, the ureter in this study was dilated in one setting. After two minutes, balloon and cystoscope are retracted and ureteroscope of 11.5 Fr is passed, making sure that all the bends in the ureter are carefully passed through until the tip of the instrument is against the stone. If the stone is close to the orifice of the ureter or is embedded in the ureteric wall dilatation becomes very difficult.

If the instrument is not handled delicately, it can damage the wall of the ureter and even form a false passage. In five patients we were not able to dilate and therefore we had a problem in passing the ureteroscope and eventually we managed to remove only three of the five stones by ureteroscopy alone.

After reaching the stone, depending on its size, location, and nature, basketing, forceps and breaking

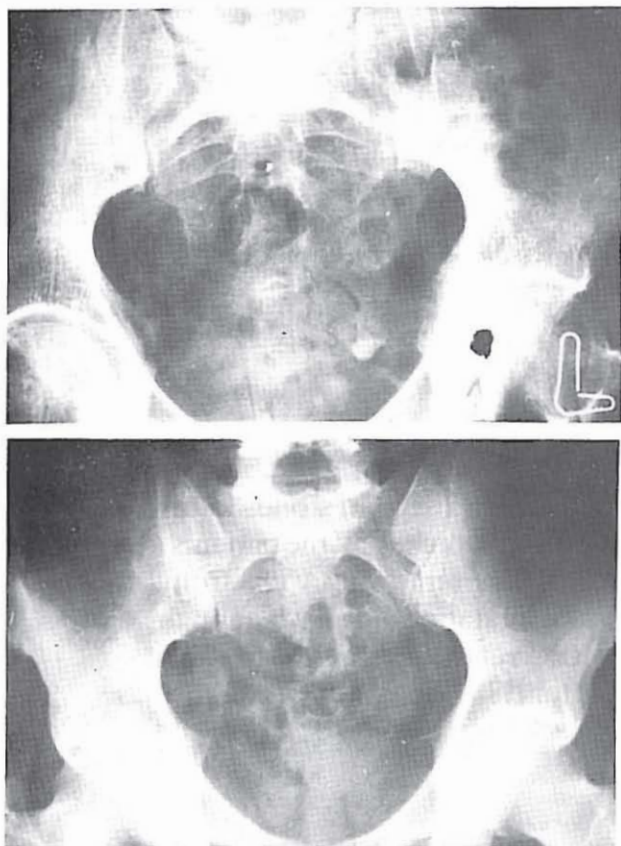


Fig. 1. A, pelvic radiograph demonstrating left lower ureteral stone. Arrow points to stone which was removed en bloc.

the stone using an external energy source are used until the stones are removed. Our first choice is the basket. It removes the stone in one piece, preventing the ureter from shock waves, hence bleeding and possibly stricture. If the stone is too large for basket or is situated high in the ureter, the basket can rupture the ureter. We have managed to extract stones up to 15×10 mm from the lower ureter with no complications, such as tear, bleeding or urinary leak. In cases of larger stones which the basket could not bypass, electrohydraulic waves were used to break the stone to smaller pieces and then the basket was used to remove the pieces.

On using the electrohydraulic, the probe is held 5 mm from the stone and the lens at least 5 mm from the probe, and the smallest shock should be given. This will ensure that the lens is not damaged by the shock wave or flying pieces of stone. At the end of the procedure, if bleeding or rupture of the ureter is suspected, a ureteric catheter is kept in place for 2-7 days.

Patients were seen on the third and seventh day and second and fourth month postoperatively, and a KUB film, urinalysis, and ultrasound study of kidneys were carried out. Attention was paid for presence of hematuria, remnants of stone, or hydronephrosis. In cases of fever without hydronephrosis and persistent urinary

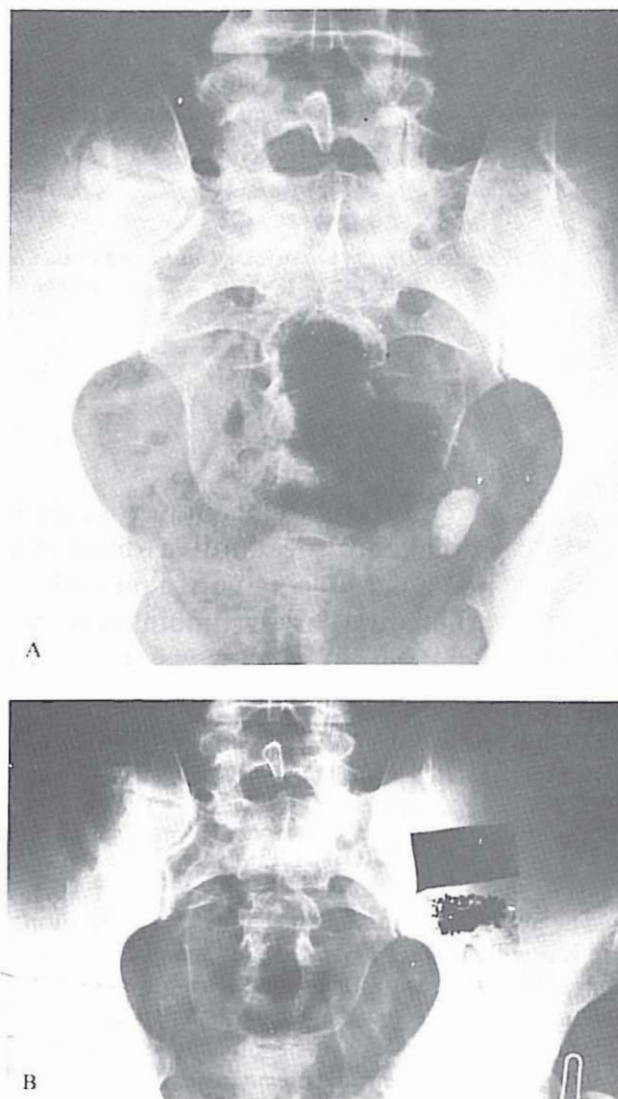


Fig. 2. A, KUB demonstrating left lower ureteral stone. B, control film showing absence of stone. Arrow points to stone fragments which were extracted following electrohydraulic treatment.

infection, VCUG was carried out to exclude V-U reflux. No IVU was carried out in any of the patients for evaluation of ureteral leakage. Figures 1-6 demonstrate the radiographs of patients with lower, middle and upper ureteral stones before and after TUL.

## RESULTS

In 104 procedures for stone removal, in 24 cases, the stone was above and in 80 cases below the pelvic brim. Overall success rate was 84.7%.

It needs to be said that in a previous report of 61 cases, the success rate in 18 cases of stones above the pelvic brim was 78% and in 46 cases below the brim it was 86%.<sup>3</sup> In the present 43 cases with stones below the

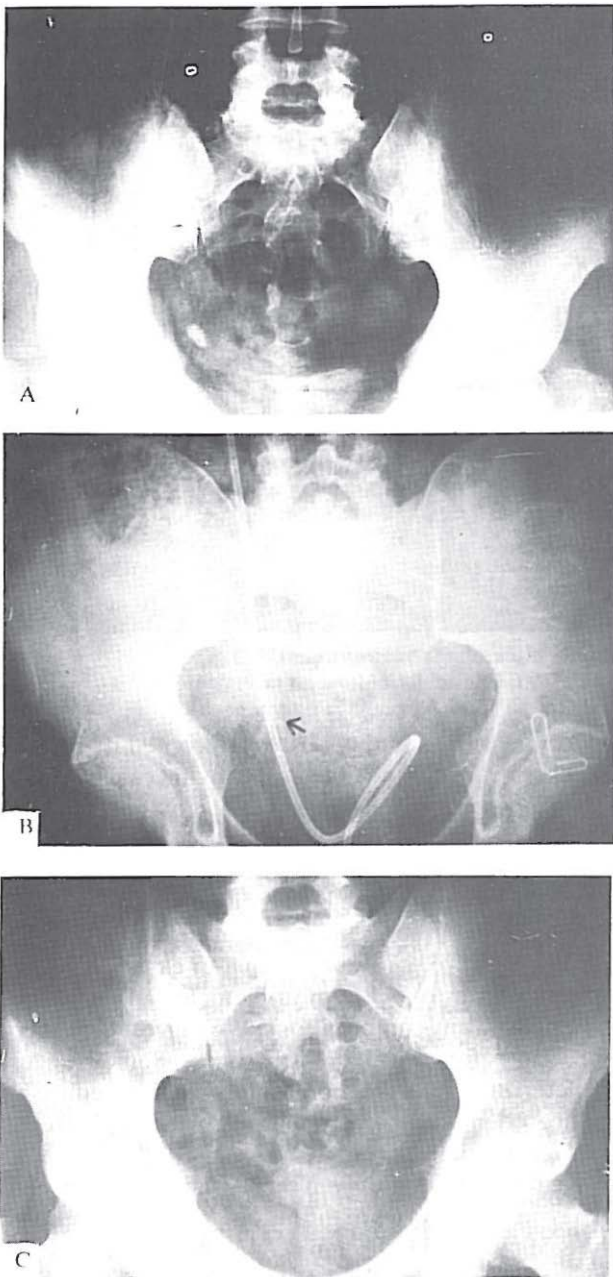


Fig.3. A, right lower ureter stone. B, pelvic radiograph following stone fragmentation (arrow). Ureteral catheter is in place. C, control film one week after TUL with catheter removed and no evidence of stone in ureter.

pelvic brim the success rate is 87.5% and in six cases with stones above the pelvic brim, the success rate is 100%. While the number of cases in these groups are not similar, it still shows the degree of mastery in TUL. In 24 cases of the aforementioned cases, after dilatation of the ureteric orifice, the stone was removed using a basket and in 60 cases, the stone was first broken using electrohydraulic treatment and then the basket was used to extract the pieces, or after being sure that the pieces were small, they were allowed to pass

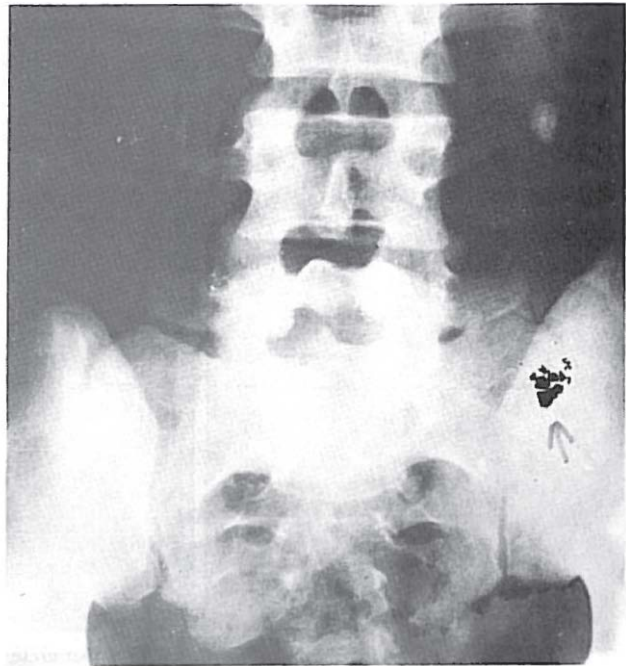

Fig.4. KUB demonstrating left mid-ureteral stone. Arrow points to stone fragments after fragmentation and extraction.

spontaneously. In this 60 cases, only in two patients after three months were remnants of stone detected in the ureter. In the rest of the patients, the stone fragments were passed within one week. In two patients after dilatation of ureter, the stone was removed using a biopsy forceps and in two patients, during cystoscopy it was found that the ureteric orifices are placed in an abnormal position, and there is a stricture. After dilatation, a size 8 ureteric catheter was left in situ for 48 hours. After removing the catheter, the stone passed spontaneously with ease. In one patient with left flank pain, an IVP showed nephroureteric dilatation but plain abdominal X-ray failed to show any stone. In this patient, diagnostic ureteroscopy was carried out and after seeing a small stone midway in the ureter, it was removed using a basket. In five female patients due to lens opacity, pediatric cystoscope was used trying to enter the ureter and only in three cases we managed to extract the stones using a basket.

## DISCUSSION

80% of ureteric stones are passed spontaneously and only 20% need surgical manipulation.<sup>4</sup> Up to 1970, only limited cases of ureteric stones were handled by cystoscopy or basketing and those that did not pass were removed surgically. Although basketing under fluoroscopy has been reported to have a 60-70% success rate,<sup>5</sup> it does have its own limitations which include the size of stones (< 1cm in diameter), lower ureteric stone, lack of ureteric stricture distal to the

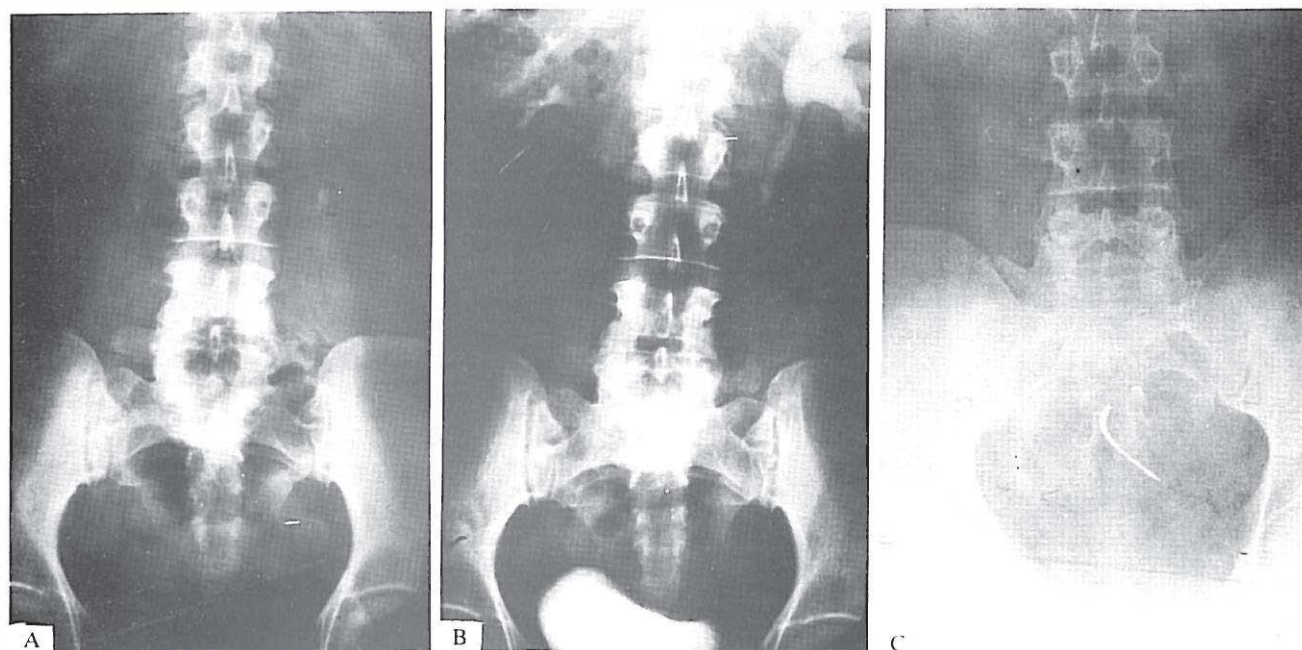


Fig.5. A. KUB showing left upper ureteral stone. B. IVU revealing renal and ureteral dilatation up to point of stone. C. control film after TUL with no sign of stone.

stone or adhesion to ureteric wall. By the mid-1970s, TUL and mid-1980s, ESWL became popular. Because of its simplicity and high success rate, ESWL received the attention it deserved and it is regarded as the treatment of choice in kidney and ureteric stones.<sup>6,7</sup> Therefore, TUL is the method to be used:

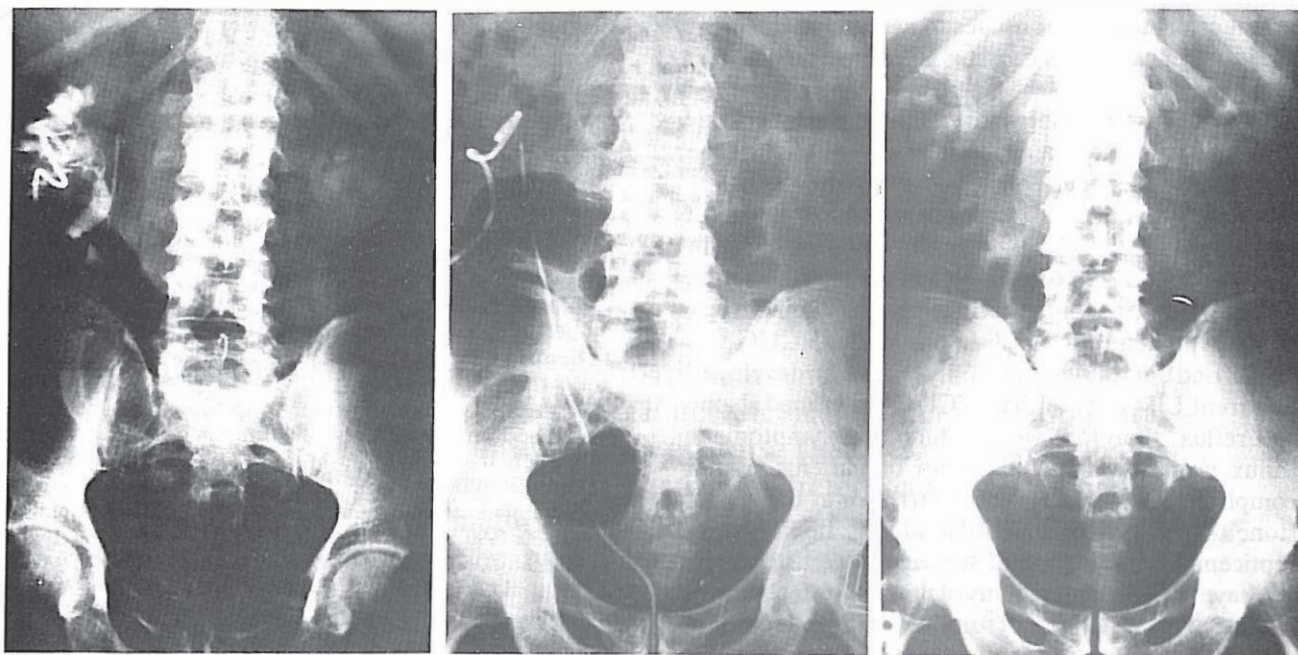
- 1- when ESWL fails,
- 2- when larger stones are broken to pieces by ESWL and fragments are lodged lower in the ureter and do not pass spontaneously (steinstrasse),
- 3- when ESWL is not applicable (eg, overweight, height of the patient, coagulation defect, obstruction distal to the stone),<sup>6,8,9</sup>
- 4- when stones are not impacted in the ureter. Some authors report a success rate of 95%<sup>4</sup> but in the majority of studies, the reports are less successful.<sup>10,12</sup> Therefore, in some cases, TUL is a complementary procedure to ESWL and in some, TUL is a priority to ESWL. Success in TUL depends on the size of the stone, place where it has lodged, nature of the stone, size and type of ureteroscope, and expertise of the surgeon.<sup>11,1</sup> Success rate with unmanouvable ureteroscope for the lower ureter and upper ureter is 97% and 72%, respectively.<sup>13</sup> Success with manouverable ureteroscope for stones of distal ureter is the same as the nonmanuverable ureteroscope and for the proximal ureter is 85 to 95%.<sup>11</sup> Therefore some surgeons suggest that the nonmanouverable instrument is for the distal ureter and the manouverable instrument for the proximal ureter.<sup>1</sup> Surgeons' expertise is of great importance. Ansong reports an initial success rate of 71% increasing to 92% in the later years.<sup>13,14</sup> Nature of stones is also

important and as far as TUL is concerned its success increases from cystine brochite, struvite, calcium, oxalate monohydrate, calcium oxalate hydrate to uric acid.<sup>8</sup>

It has been suggested that for stones larger than 6mm, the best approach is to break the stone first and then to use a basket. This is to prevent damage to the ureter. We have used a basket in four cases with distal ureteric stones of 8-10mm in diameter and have not experienced any complications. We suggest the procedure only for distal ureter stones. Some suggest catheterization for 48 hours after the procedure to reduce edema and hydronephrosis and to help the passage of small stones.<sup>2,13,15</sup>

We used catheter only in those who were suspected of having had injuries to the ureter. With availability of the 8.5Fr and 9.5 Fr ureteroscope, there is no need for dilatation and an increased success rate,<sup>1</sup> and their use in children has become possible.<sup>16</sup>

In our patients the nature of the stones have not been analysed. All the procedures have been carried out using a 11.5 Fr and 12.5 Fr ureteroscope and the success rate in the first six months was 82.5%. The difference may not be significant but in the long run may prove to be operator-dependent. The causes of failure in extracting stone can be divided into two groups: first, failure in passing the ureteroscope up to the stone and includes hemorrhage, false passage and difficulty in passing the ureteroscope over the curves, especially where the ureter passes over the iliac vessels. Sometimes it is difficult to penetrate and dilate the ureter. This is why some centers advocate dilatation under



**Fig.6.** A. nephrostogram of a patient who presented with a creatinine level of 10 mg/dL and a history of surgery for removal of a right-sided staghorn calculus three months previously. He had a nephrostomy done due to hydronephrosis of the right kidney. As seen in the radiograph, he has a staghorn calculus in the left kidney and the nephrostogram demonstrates an obstruction at the right mid-ureter. Ureteroscopic evaluation revealed a right mid-ureteral stone which was extracted. B. KUB of the patient after TUL with ureteral catheter in place. C. IVU of the patient after nephrostomy and catheter removal and normal serum creatinine. Excretion of dye by the right kidney is demonstrated.

fluoroscopy.

Marberges suggests leaving the dilator in situ for 48 hrs and then passing the ureteroscope.<sup>17</sup> In our experience, 10% of complications were of this nature. The second reason of failure is due to either resistance of the stone to the waves or movement of the stone proximally during the maneuver, which consisted of 6% in our group.

The rate of complications differ in different reports and seems to depend on the size, location, nature of stone and also on the kind of instrument used, the experience of the surgeon, and the interval between the procedure and control IVP performed. In one study, IVP was performed right after TUL and the rate of ureteric perforation was reported to be 17%,<sup>18</sup> while in another series where control IVP was not performed routinely, the perforation rate was 4.5%.<sup>8</sup> In the study where electrohydraulic was used no perforation was reported.<sup>11</sup> Blute reports no vesicoureteric reflux, because his patients did not have VCUG after TUL,<sup>13</sup> while others report 9.6% reflux in those undergoing VCUG.<sup>1</sup>

According to Weinberg, the rate of complications directly relates to the size of the stone<sup>14</sup> and also the location- the more proximal, the greater the chance of complication.<sup>1</sup> The kind of energy source used is also important. Electrohydraulic produces 6 to 25 times more heat than laser, and therefore causes more

damage to the ureter and the lens.<sup>12,15</sup> To reduce the rate of complications when electrohydraulic is used, one should be contented with passable stone sizes, the tip of the probe should be kept 5 mm away from the lens, and one must make sure that the probe does not touch the wall of the ureter.

In summary, complications of TUL consisted of:

1- Fever: some report this in up to 6.5%,<sup>13</sup> but we have had a rate of 1%.

2- Repeating the procedure: we have experienced a rate of 2% while others have had more difficulty and a rate of 5% has been reported previously.<sup>1</sup>

3- Urinoma: this forms the most common complication in our series while in other series up to 5% has been reported.<sup>13</sup>

4- Perforation of ureter: perforation occurs mainly in the distal ureter and is due to the angle and also fixed nature of this part of the ureter. The major cause is rough handling of the ureteroscope. Although Dretler suggests the laser in impacted stones and believes that electrohydraulic may cause perforation, but by reviewing the literature it seems that the experience of the operator plays a more important role than the kind of instrument used.<sup>3</sup>

5- Stricture: stricture of ureteric orifice varies according to the length of follow up and has been reported in 1.5 to 5%. This complication is the result of damage to the ureteric meatus and is not related to the

extent of dilatation but relates to aggressive treatment of the ureter by the ureteroscope. We have not had any case yet.

6- Vesicoureteric reflux: to explore the extent of this complication, all patients should have VCUG. The highest rate has been 9.6%.<sup>1</sup> The experience of the surgeon involved plays a major part in development of this complication. In two groups of children, those in whom an 11.5 Fr ureteroscope was used had no reflux while 50% of the group where an 8.5 Fr instrument was used developed reflux.<sup>16,20</sup> In our study, VCUG was not carried out routinely and only those who developed recurrent UTI or fever had VCUG performed. None had reflux, therefore we conclude that symptomatic reflux was absent in our group of patients. Other complications include ureteric stricture at the site of stone, tear and detachment of ureter, hemorrhage, septicemia or impaction of stone or basket in ureter. We have not encountered any of them. Dretler believes that electrohydraulic is not suitable for impacted stones and will cause stricture.<sup>12</sup> We agree with Senstedt that electrohydraulic if used properly, is the method of choice in breaking ureteric stones.<sup>3</sup>

In summary, the following points are in favour of TUL. In five cases where we had to repeat ureteroscopy, in three, ureteric meatus did not need to be dilated and the stone was removed with no difficulty. One can conclude that after the first ureteroscopy, the ureteric meatus remains dilated which makes the passage of other stones possible. In two of our patients, stones were of 3×6mm size which after six months still were in situ and in ureteroscopy, we noticed the abnormality of the ureteric meatus and after dilatation the stones passed spontaneously. We believe that in these situations one must think of anomalies, and the method of choice for diagnosis and treatment is ureteroscopy and TUL. In situations with obstruction without certain etiology, ureteroscopy for diagnosis is mandatory. We have had patients with flank pain and hydronephrosis whom after ureteroscopy, had their non-opaque stone removed. Therefore TUL is the method of choice when ESWL is not feasible and also when laser as a source of energy is not available, use of electrohydraulic or ultrasound in the hand of experts is a safe and effective procedure. In general, TUL with its

short stay in hospital,<sup>1,10</sup> and lower morbidity in comparison to open surgery, is preferable and also TUL and other endourological procedures are complementary to ESWL and has been reported in up to 33% of ESWL cases.<sup>7</sup>

### REFERENCES

- 1- Daniels GF Jr, Garnett JE, Carter MF: Ureteroscopic results and complications: experience with 130 cases. *J Urol* 139: 710-13, 1988.
- 2- Higashihara E, Aso Y: Flexible ultrasonic lithotripter. *J Urol* 142: 40-42, 1989.
- 3- Bassiri A, Simforoosh N, Vahidi S: TUL. Abstract book of the second International Urological Seminar. Tabriz, Islamic Republic of Iran.
- 4- Berkhoff WB, Meiger F: Percutaneous antegrade fiberoptic ureterorenoscopic treatment of ureteral calculi. *J Urol* 144: 628-30, 1990.
- 5- Tanagho E, McAninch JW: Urinary Stones. In: Smith Dr (ed), *General Urology*. East Norwalk: Appleton and Lange, 293-95, 1990.
- 6- Wilson WT, Preminger GM: Extracorporeal shock wave lithotripsy. An update. *Urol Clin N Amer* 17: 1, 1990.
- 7- Geert GG: Experience with the Dornier HM4 and MPL lithotriptors in urinary stone treatment. *J Urol* 144: 622-27, 1990.
- 8- Metola LA, Smith AD: Therapeutic options for the management of upper tract calculi. *Urol Clin N Amer* 17: 1, 1990.
- 9- Segura JW: Role of percutaneous procedures in the management of renal calculi. *Urol Clin N Amer* 17: 1, 1990.
- 10- Govier FE, Gibbons RP: Pulsed dye laser fragmentation of ureteral calculi. *J Urol* 143: 685-6, 1990.
- 11- Denstedt JD, Clayman RJ: Electrohydraulic lithotripsy of renal and ureteral calculi. *J Urol* 143: 13-17, 1990.
- 12- Dretler SP: Ureteral stone disease. *Urol Clin N Amer* 17: 1, 1990.
- 13- Blute ML, Segura JW, Patterson DE: Ureteroscopy. *J Urol* 139: 510-12, 1988.
- 14- Weinberg JG, Ansong K, Smith AD: Complications of ureteroscopy in relation to experience. *J Urol* 137: 384, 1987.
- 15- Morgentaler A: Management of the impacted ureteral calculus. *J Urol* 143: 263-6, 1990.
- 16- Caione MP, De Gennaro M: Endoscopic manipulation of ureteral calculi in children. *J Urol* 144 (2): 484-5, 1990.
- 17- Stacki W, Marberger M: Late sequelae of the management of ureteral calculi with the ureterorenoscope. *J Urol* 136: 386, 1986.
- 18- Kramolowsky EV: Ureteral perforation during ureteroscopy. *J Urol* 138: 36-8, 1987.
- 19- Dretler SP: An evaluation of ureteral laser lithotripsy. *J Urol* 143: 267-72, 1990.
- 20- ●ne Y: Long-term results of transurethral lithotripsy with the rigid ureteroscope. *J Urol* 142: 958-60, 1989.
- 21- Hill DE, Segura JW: Ureteroscopy in children. *J Urol* 144 (2): 481-3, 1990.