

URETEROSCOPY IN 104 PATIENTS

M.S. ILBEIGI, M.D.

From the Department of Urology, Air Force Medical Center, Tehran, Islamic Republic of Iran.

ABSTRACT

From July, 1987 to Oct, 1989, 104 patients underwent 111 transurethral ureteroscopy procedures at the Air Force Medical Center. All intramural ureters were dilated by flexible metal dilators. The overall success rate for ureteral stone removal was 95.8 per cent. Ureteroscopy was done for evaluation of gross hematuria, strictures, ureteral stent, and ureteral and pyelocalyceal tumors. The overall mean hospital stay was 2.5 days with no important complications.

MJIRI, Vol. 4, No. 4, 253-255, 1990

INTRODUCTION

With the development of medical technology, especially in endourology, ureteroscopy is of increasing importance in the diagnosis and management of upper tract urological problems such as ureteral stones, tumors of the ureter or pyelocalyces, ureteral strictures, placement or replacement of ureteral stents, and in evaluation of gross hematuria. It is easy, safe and useful, especially with preureteral dilatation. The following is my report of technique, success, and complications.

PATIENTS AND TECHNIQUE

From July, 1987 to Oct, 1989, 104 patients underwent 111 transurethral ureteroscopy procedures (T.U.P.). There were 98 male and six female patients between 20 to 65 years old, with a mean age of 35.41 years. Table I depicts the variety of operations performed on these patients.

The most common procedure was stone manipula-

Table I. Rigid ureteroscopy procedures (1987-1989)

Procedure	No.
Stone basket	31
Diagnostic examination	2
Basket/electrohydraulic lithotripsy	42
Electrohydraulic lithotripsy	25
Ureteral stricture	2
Ureteral and pyelocalyceal tumors	2
Total	104

tion in 96 patients with 111 ureteral stones (92%). The overall mean hospital stay was 2.5 days, and the procedure was done with or without anaesthesia (Table II).

Technique

The technique of T.U.P. was the same as other descriptions.¹⁻⁴ All patients were hospitalized the night before, and preoperative antibiotherapy was performed. Most of the patients underwent general anaesthesia (Table II). We used droperidol (0.33 mg/kg) and fentanyl (7µg/kg) for neurolept anaesthesia. Routine cystoscopy was performed and in some cases a flexible-tipped guide wire² was passed under vision into the ureteral orifice beyond the stone or lesion or to the renal pelvis. In all patients ureteral dilatation was done with flexible metal dilators up to No. 14 FR. over a guide wire (Fig.1). The guide wire and dilators were then removed, and the rigid ureteroscope was passed from the urethra to the ureter up to the stone or lesion under direct vision with low pressure and with normal saline as an irrigant (Fig 2). The size of the ureteroscope used varies from 10 to 13.5 FR.⁵ and depends on instrument availability and the reason for ureteroscopy, but we use 10.5 FR. and 11.5 FR.

Table II

Anaesthesia	No.
General anaesthesia	83
Neurolept anaesthesia	20
No anaesthesia	1
Total	104

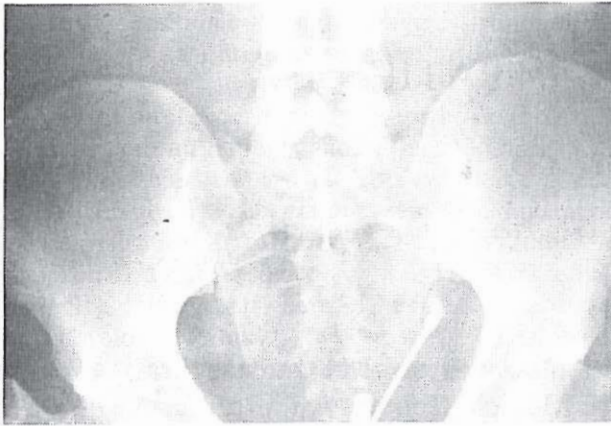

Fig. 1. Ureteral dilatation with flexible metal dilator.

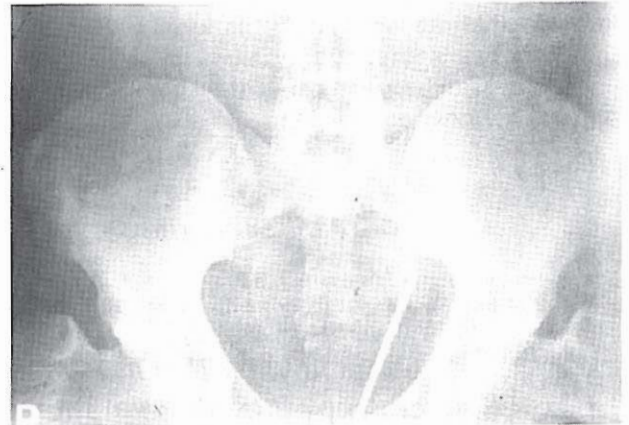


Fig. 2. Passing the rigid ureteroscope up to the stone.

Stone removal

Once the stone is visualized, determination is made as to the best means of removal. Small stones were removed by basket manipulation.² For the larger ones we used electrohydraulic power for fragmentation and then for bigger fragments we used basket or mechanical instruments.⁷ For the finer fragments we did not use any mechanical instruments because they pass spontaneously with urine. At the conclusion of the lithotripsy, the ureter is inspected for residual fragments. We used ureteroscopy for diagnosis of ureteral pyelocalyceal tumors, ureteral strictures and ureteral stent removal.

tumor and biopsy was taken. Two ureteral strictures were dilated ureteroscopically and two unilateral hematuria cases were evaluated by ureteroscopy. We also removed three residual ureteral stents ureteroscopically.

Complications

There were a total of 13 complications in 111 procedures (11%). Five patients underwent procedures twice and in one case, thrice. The other complications were high fever in one and mild hematuria in five cases and complete ureteral avulsion in one case.

RESULTS

Stone manipulation

A total of 96 patients underwent 105 TUL procedures in 26 months. There were 92 males and four females. Stones were on the right side in 42 cases, on the left in 54 and bilateral in two patients. 18% were in the upper, 30% in the mid, and 61% in the lower third of the ureters. Duration of procedures varied between 15 min. and 90 min. (mean 25 min) due to the stones' size (5mm to 25mm) and composition of stones. Destruction of some stones was difficult (like Ca-oxalate monohydrate), and we attempted twice in five cases and thrice in one case. We succeeded in 92 cases (95.8%) and had four failures because of undisintegrated stone in one case (Ca-oxalate monohydrate), non-visualized stone in two, and complete ureteral avulsion in one patient. All the patients were followed at the end of the procedure with sonography, VCUG, (and IVU in some cases) three months and one year after the procedure.

Filling defect

Three patients underwent T.U.P. because of filling defects on IVP and in one case it was due to ureteral

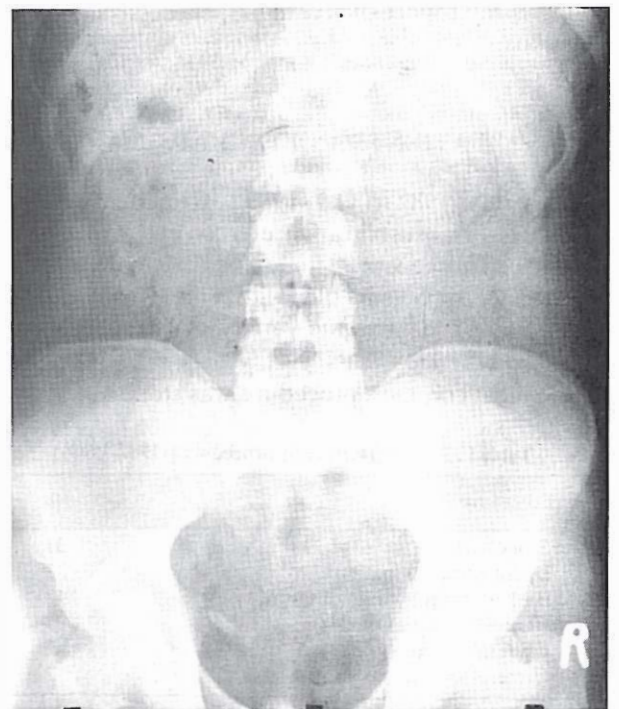

Fig.3. Plain film of one of the patients with ureteral stone (lower third).

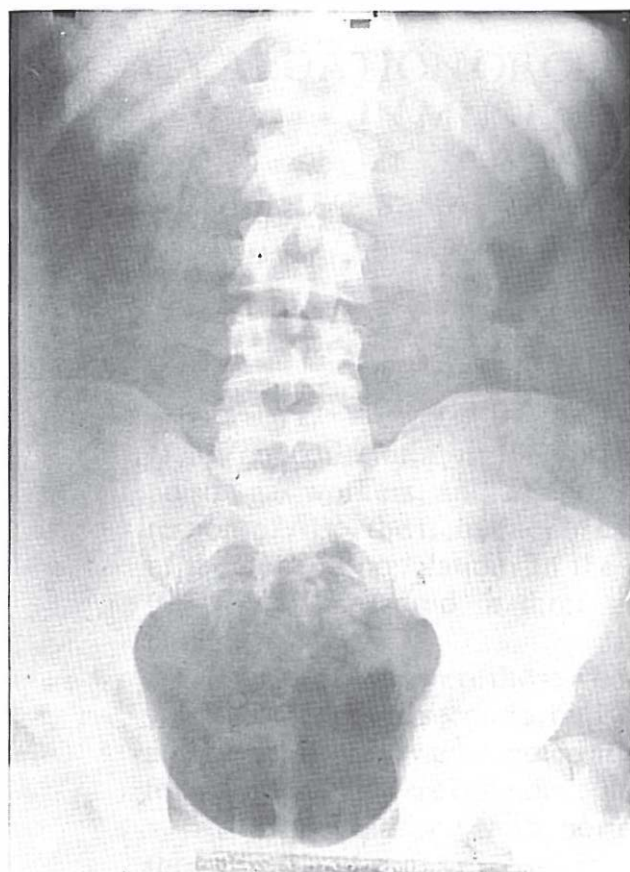


Fig. 4. Plain film showing fragmentation of stone with electrohydraulic shock wave.

DISCUSSION

Blind manipulation with basket for stone was used several years ago by Drach (1978) with a 30% success rate and Flynn (1980) with 90% success.² We had 75.8% success under fluoroscopic control. The above

rates are for lower ureteral small stones. All impacted stones or ureteral stones located in the mid or upper third of the ureter underwent surgical procedures with high morbidity, and major complications (such as ureteral strictures, fistula, and difficulty in second or third operation). Since the original reports by Lyon⁶ and associates, Prez-Castero and Martinez-Pineiro, T.U.P. has been recognised as a major addition to the urological armamentarium. It is currently the procedure of choice in the management of ureteral stones. Our overall 95.8% success rate is comparable with other reports, but our complication rate is less. We had no ureteral perforation seen in other series (except one complete ureteral avulsion that required emergency surgery). We used electrohydraulic shockwave in several cases, having no early or late complications (26 months follow-up).

REFERENCES

- 1- Huffman JL, Morse MJ, Herr HW, Sofani PC, Whitmore WC, Jr., Fair WR: Ureteropyeloscopy. *World J Urol* 3:58- 63, 1985.
- 2- Ford TF, Waston GM, Wickham JEA: Transurethral ureteroscopic retrieval of ureteral stones. *British J Urol* 55:626- 628, 1983.
- 3- Lyon ES, Huffman JL, Bag Ley DH: Ureteroscopy and Uretero- Pyeloscopy. *Urol suppl* 5:23-29, 1984.
- 4- Green DF, Lytton B : Early experience with direct vision electrohydraulic lithotripsy of ureteral calculi. *J Urol* 133:767, 1985.
- 5- Ford TF, Payne SR, Wickham JEA: The impact of transurethral ureteroscopy on the management of ureteric calculi. *British J Urol* 56: 602-3, 1984.
- 6- Lyon ES , Kyker JS, Scheen- Berg HW : Transurethral ureteroscopy in women: a ready addition to the urological armamentarium. *J Urol* 119:35, 1978.
- 7- Webb DR, Fitzpatrick JM: Experimental ureterolithotripsy. *World J Urol* 3: 33-35, 1985.