

THE DIAGNOSTIC YIELD OF TRANSBRONCHIAL LUNG BIOPSY IN DIFFUSE INFILTRATIVE PULMONARY DISEASES BY PLAIN CUP FORCEPS. A STUDY OF 54 CASES IN IRAN

PARVIZ VAHEDI, M.D.

From the Department of Internal Medicine, Imam Reza Medical Center, Mashad University of Medical Sciences, Mashad, Islamic Republic of Iran.

ABSTRACT

The technique of transbronchial lung biopsy (TBLB) has expanded the diagnostic yield of bronchoscopy. In this article we are presenting 54 patients with diffuse pulmonary parenchymal involvement who underwent this procedure during six years between June 1980 and December 1989. The diagnostic yield of this technique in diffuse pulmonary parenchymal disease is great and was 66 percent excluding nonspecific pulmonary fibrosis. Compared with other literature this is a good way of diagnosing interstitial lung disease which obviates the need for transcutaneous lung biopsy and thoracotomy.

MJIRI, Vol. 4, No.2, 87-91, 1990

INTRODUCTION

Fiberoptic bronchoscopy has greatly expanded the diagnostic capability of bronchoscopy over that provided by the rigid bronchoscope. Much of this expansion has been related to the ability to use transbronchial sampling with greater precision and safety. For many years now, transbronchial forceps biopsy, first pioneered as a technique for rigid bronchoscopy¹ and as a radiologic technique, has been a standard diagnostic procedure. More recently, a number of aspiration needles have become available for use through the fiberoptic bronchoscope, which has further expanded the diagnostic range of bronchoscopy, providing enhanced access to peripheral as well as to submucosal and mediastinal lesions.

Although diagnosis of cancer is perhaps the most common application of these techniques, they can be applied to a wide range of pathologic processes. In many situations, bronchoscopy with transbronchial biopsy can play an important role in the diagnosis of infections. Application to non-infectious benign diseases is also possible, although it may be more limited depending on the experience of the cytopathologist. In these above situations they usually use TBLB with the guidance of fluoroscopy to accurately reach the lesion;

however when they use it for diffuse infiltrative diseases of the lung the need of fluoroscopy is definitely decreased due to the random accessibility of the lesion wherever it is.

This review covers the instrumentation we used for transbronchial sampling, the technique employed in transbronchial biopsy, and the results of application of this procedure in 54 patients with diffuse infiltrative pulmonary diseases at the Imam Reza Hospital Medical Center.

MATERIALS AND METHODS

We studied the results of transbronchial lung biopsy in 54 cases who had diffuse infiltrative involvement on the chest X-ray. The Olympus FB and the plain cup forceps #19 and #20 were used in this study.

As usual local anesthesia with a 2% xylocaine solution was used and the fiberoptic was advanced through the nostrils into the bronchial tree. We used the wedge technique in our procedure. It means that we advanced the bronchoscope as far as possible towards the segment or subsegment from which the biopsy was intended. The purpose of this method is to remain close to the segment or subsegment from which the biopsy is

Transbronchial Lung Biopsy

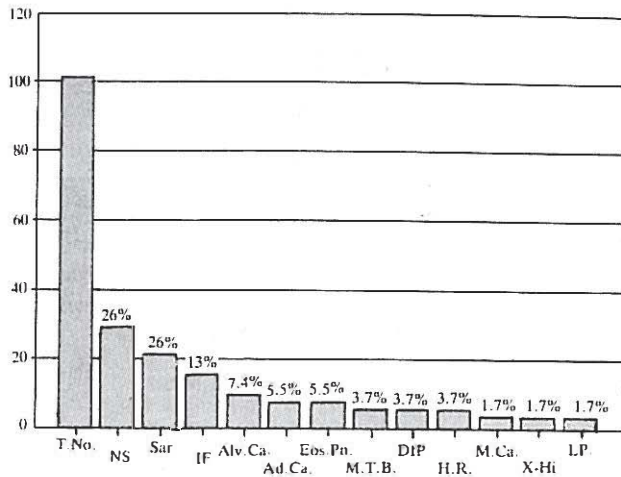


Figure 1. The result of TBLB on cases of interstitial pulmonary disease.

taken to control potential bleeding. We did not use fluoroscopy to take the biopsy specimens. After wedging the fiberopticwe advanced the forceps slightly from the end of the bronchoscope so that they could accurately be placed in the segmental or subsegmental bronchus of choice. They are then passed further until the forceps go into the lung parenchyma.

When the tissue of the lung was reached we used the timing technique to take our specimen from the lung.

The number of specimens we obtained from each patient was four to five pieces. We obtained most of our specimens from the base of the lungs; however in some instances which we failed to do so we preferred to take it from the apices.

For every patient undergoing this technique we performed pulmonary function testing. Vital capacity was equal or more than 1.5 liters in all of our patients and obviated morbidity and mortality after the procedure.

For every patient we ordered an immediate chest x-ray after completing the procedure to check for evidence of traumatic pneumothorax.

RESULTS

The results of study on 54 patients are summarized in Table I and reflected in Fig. 1. 47 of these patients had definite diffuse interstitial pattern on chest x-ray; however three cases with suspected sarcoidosis presented with stage I of the disease, i.e. bilateral hilar lymph node enlargement without parenchymal involvement but with erythema nodosum and apparent healthy condition. All of these patients had the common complaint of dyspnea either at rest or during exercise. Pulmonary function testing in these patients showed a definite decline in VC and FEV₁ prop-

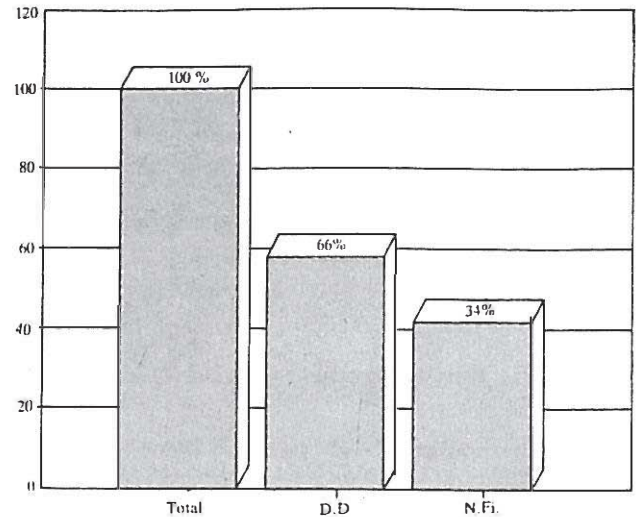


Figure 2

ortionally consistent with a restrictive pattern. Along with x-ray findings some of the patients presented with some other clinical or laboratory manifestations of their underlying pathology like erythema nodosum in sarcoidosis, severe dyspnea or clubbing in Hamman-Rich syndrome, abundant sputum production or weight loss in alveolar cell carcinoma, peripheral eosinophilia in PIE syndrome, diabetes insipidus in histiocytosis, and a fever of unknown origin in miliary tuberculosis.

14 cases showed an almost normal or nonspecific finding in the pathological specimen and seven cases revealed interstitial pulmonary fibrosis which is not pathognomonic of any specific pathology. So, if we include these later cases in our statistics, the diagnostic yield of our study comes to 80 percent. However, due to nonspecificity of pulmonary fibrosis we did not consider these seven cases as proven cases and as a result our diagnostic yield declined to 66 percent (Fig. 2).

Fourteen of these 54 patients (28%) had pulmonary sarcoidosis, with lymph node enlargement without parenchymal involvement on x-ray, hilar node enlargement and diffuse parenchymal involvement and diffuse interstitial pattern without hilar adenopathy. All of these cases had a noncaseating interstitial pattern without hilar adenopathy. All of these cases had noncaseating granuloma as diagnostic hallmark of sarcoidosis.

Alveolar cell carcinoma was found in four of the patients. Again when these patients referred to our clinic they already had a diffuse interstitial pattern on x-ray.

Metastatic adenocarcinoma most probably from a primary focus in the lung itself was found in three of our patients. Interestingly enough they were all women and didn't show evidence of primary involvement

Table I. Results of TBLB in 54 patients with diffuse infiltrative disease of the lung* (interstitial fibrosis is included).

Diagnosis	Number of patients	Percent of patients
Nonspecific	14	26
Sarcoidosis	14	26
Interstitial Fibrosis	7	13
Alveolar Cell Carcinoma	4	7.4
Adenocarcinoma	3	5.5
PIE Syndrome	3	5.5
Miliary Tuberculosis	2	3.7
Desquamative Pneumonitis	2	3.7
Hamman-Rich Syndrome	2	3.7
Metastatic Carcinoma	1	1.7
Histiocytosis X	1	1.7
Lymphocytic Pneumonitis	1	1.7

* Three cases of sarcoidosis are included and presented with hilar adenopathy without apparent parenchymal infiltrates.

elsewhere in the body, upon routine evaluation.

Pulmonary infiltrates with eosinophilia (PIE syndrome) was found in three of our patients. We already had the diagnosis of these patients before TBLB on the basis of peripheral eosinophilia and diffuse patchy infiltrates on the chest x-ray.

Miliary tuberculosis was found only in two of our patients. If we would have performed TBLB in all patients with a miliary pattern on x-ray, fever and a clinical suspicion of tuberculosis, we probably would have found more cases of caseating granuloma in the specimens. However, we performed TBLB only in those patients with diffuse micronodules on the chest x-ray with borderline symptoms and signs of tuberculosis. TBLB specimens in these patients showed acid-alcohol resistant bacilli in preparations.

Desquamative interstitial pneumonitis was found in two of our patients who were related to each other. The same was true for two cases of Hamman Rich's syndrome. These cases were reported previously in the Medical Journal of the Islamic Republic of Iran.² Metastatic carcinoma, two histiocytosis X and lymphocytic pneumonitis were found in three of our patients. The case of histiocytosis had diabetes insipidus clinically and was found to have a honeycomb appearance on chest x-ray.

DISCUSSION

Equipment

Forceps: Bronchoscopic forceps have changed only slightly since their introduction almost 20 years ago.³ They are hinged cups with either a cutting edge or a serrated edge (alligator forceps). In our study we used plain cup forceps which have a window in each cup to limit crushing the specimen, although it has never been demonstrated that this modification is effective in

limiting crush artifact. While these forceps have a cutting edge, in practice tissue is often torn rather than cleanly cut in the course of transbronchial biopsy. This tearing action does not appear to have any clinically deleterious effect. Accuracy in sampling the lesion and the number of samples taken appear to be more important than the actual sample size. As a result, plain cup forceps of either size are appropriate instruments for transbronchial biopsy. Alligator forceps are mostly useful for grasping foreign bodies and although they can also be used for transbronchial lung biopsy, they were not used in this study.

Techniques and Complications

Transbronchial biopsy is a simple procedure. It is helpful to advance the forceps slightly from the end of the bronchoscope so that they can be accurately placed in the segmental or subsegmental bronchus of choice. They are then passed until beyond view, after which fluoroscopy is used to guide the forceps into the lesion. For mass lesions, the position of the forceps in the lesion can be confirmed by biplane fluoroscopy, rotating the arm of the C-arm fluoroscope or moving the patient. For the latter two techniques, one looks to see if the forceps move with or away from the lesion. If the forceps and the lesion move together, they are in the same plane.

Once in the lesion, the forceps can be opened, advanced slightly depending on the lesion size, closed, and withdrawn. Sufficient tissue is pushed into the forcep cups by advancing the forceps in the lesion. A technique of timing the biopsy to the respiratory cycle has been advocated.⁴ In this technique, the forceps are opened, the patient inhales and exhales deeply, and the forceps are closed at end-expiration. The concept of this technique is that tissue will invaginate into the forceps cups during exhalation, producing a large tissue sample. This was the method that we used in our patients in all of our cases. However, in a study of transbronchial lung biopsies done during inhalation and exhalation timing the biopsy to exhalation made no difference in the number of alveoli obtained or in the overall specimen size.⁵

If the bronchoscope tip is flexed during the biopsy, it should be straightened before removing the forceps to avoid damage to the bronchoscope. It is important however for the bronchoscope to remain close to the segment or subsegment from which the biopsy was taken to control potential bleeding. Wedging the bronchoscope in the bronchus will serve this purpose, but it is probably not necessary to actually wedge the bronchoscope as long as the distal tip can effectively be moved to block the bronchus if necessary.

The use of fluoroscopy in transbronchial biopsy is the subject of occasional controversy. Fluoroscopic guidance clearly increases the diagnostic yield in focal

Transbronchial Lung Biopsy

lesions,⁶ but transbronchial biopsy can be performed without fluoroscopic guidance in diffuse lung disease. A careful technique is necessary though, with blind transbronchial biopsy. The forceps are passed with the cup closed until resistance is met or the patient expresses pain, which indicates that the pleura has been reached. The forceps are then withdrawn 1 to 2 cm, the cups opened, and the forceps advanced slightly and closed.¹ We obtained all our specimens without fluoroscopic guidance and whenever the patients expressed pain we withdrew the forceps slightly and the biopsies were taken.

In many studies, fluoroscopic guidance appears to be associated with a lower incidence of pneumothorax. In one large survey, performing transbronchial biopsy without fluoroscopic guidance resulted in a 60 percent greater incidence of pneumothorax.⁷ More recently, it has been suggested that fluoroscopy is not necessary in diffuse disease and that the incidence of pneumothorax is the same with or without fluoroscopy. One such study had a particularly high incidence of pneumothorax both with or without fluoroscopy,⁸ which makes the conclusions difficult to evaluate.

Since the risk of blind TBLB has been variable, it is probably safest to use fluoroscopic guidance. If fluoroscopy is not available, the technique should be used only by operators who are comfortable with the approach and have acceptable complication rates. It should also probably be limited to biopsy of the lower lobes, since blind transbronchial biopsy of other areas appears to have a higher incidence of pneumothorax. In this survey most of our specimens were obtained from the lower lobes, having in mind that nonspecific fibrosis is much more common in the lower lobes and that this will lower the diagnostic yield of our specimens.

TBLB does increase the risk of bronchoscopy. The major associated risks are bleeding and pneumothorax. In one study, TBLB tripled the mortality rate associated with bronchoscopy (from 0.04 to 0.12%) and increased the complication rate 22 fold⁷ (from 0.12 to 2.7 percent). While the morbidity and mortality remain low, it is important to recognize the increased risk in order to practice the necessary precautions. Fiberbronchoscopy performed at our institution was not associated with any cases of death or any other complications.

In general the risk of pneumothorax should be low and less than 3% during TBLB. Among the 54 patients that underwent TBLB with plain cup forceps we had 9 cases of pneumothorax: One with Hamman-Rich syndrome who had a moderate pneumothorax and due to previous severe decline in vital capacity obliged us to insert a chest tube; the other had a mild pneumothorax which was self-limited and did not need intervention. So the incidence of pneumothorax in this study was

about 2%. Mechanical ventilation, bullous emphysema and acquired immunodeficiency syndrome (AIDS) and *Pneumocystis carinii* pneumonia all increase the risk of pneumothorax when TBLB is done.^{8,9,10}

Life threatening bleeding is unusual with transbronchial biopsy. When it occurs in a patient without an underlying coagulation disorder, it usually results from the unpredictable biopsy of a sizable pulmonary artery or bronchial artery.¹ Small to moderate amounts of bleeding (less than 100 ml) are more common,⁴ and although controllable, bleeding is to be avoided if possible. With this idea in mind, mechanical ventilation, coagulation disorders and pulmonary hypertension all pose an increased risk of bleeding from transbronchial biopsy.^{9,12,13} All of our patients with bleeding in this series had less than 100 ml of hemopteic sputum and we didn't have any case of severe hemoptysis ending with an ominous complication or death.

Despite the increased risk of TBLB over simple bronchoscopy in patients without specific risk factors for bleeding or pneumothorax, it appears to be a safe procedure on an outpatient basis in many patients. Suitable patients should not have significant risk factors for bronchoscopy in general, and for bleeding and pneumothorax in particular. Additionally, such patients should be willing and able to be followed up closely on an outpatient basis and to return to the hospital if necessary.

Application

TBLB can be useful in the diagnosis of both primary and metastatic peripheral lung cancer and has been the mainstay of the bronchoscopic diagnosis of peripheral masses, although its limitations are well known. The diagnostic yield of TBLB has been variable (30 to 80%),^{14,15} averaging about 50%.

The role of TBLB in infectious processes has varied greatly, apparently related to the acuteness of the process and the patient population reflecting the incidence of different infectious processes. In general TBLB has a higher yield in acute infectious processes excluding bacterial pneumonia.¹⁶ Several studies have found it to be helpful in the diagnosis of sputum-negative tuberculosis (when cultured up to 95%) and coccidioidomycosis. However, TBLB has a low diagnostic yield in invasive aspergillosis and cytomegalovirus pneumonia.¹³⁻¹⁸ The diagnostic yield of TBLB in *Pneumocystis carinii* pneumonia is 90 to 95%.

TBLB is also useful in several non-infectious chronic interstitial diseases. It is capable of detecting sarcoidosis, lymphangitic carcinoma, pulmonary alveolar proteinosis, Goodpasture's disease,^{1,21} Wegener's granulomatosis, Hamman-Rich syndrome, desquamative interstitial pneumonitis, lymphocytic pneumonitis, eosinophilic granuloma and some other interstitial

pulmonary diseases.

The overall role of TBLB and its relation to open lung biopsy have been disputed in chronic interstitial diseases as in acute infiltrative processes. Again, the reported yields of TBLB and open lung biopsy have varied.^{22,23} Much of the variation relates to the underlying disease processes in a given population and to the reporting of non-specific interstitial inflammation as positive diagnosis. To summarize a great deal of controversy, TBLB appears to be a reasonable procedure in detecting the diseases mentioned above. It is less reliable in accurately categorizing nonspecific pneumonitis or fibrotic processes (which are difficult to biopsy adequately).

A clinical case can be made for watching patients with nonspecific pneumonitis on TBLB or treating presumed interstitial pneumonia with a therapeutic drug trial without a specific diagnosis in an appropriate clinical setting. This approach is based on the finding that 75 percent of patients with diffuse disease without a specific diagnosis on TBLB have a benign course.²³ On the other hand, open lung biopsy can detect significant processes missed by TBLB. In one study such diseases as usual interstitial pneumonitis, eosinophilic granuloma, and sarcoidosis were missed by TBLB and detected on open lung biopsy.²² In practice, the choice of TBLB or open biopsy probably depends on the clinical setting as well as on local results with the procedure.

CONCLUSION

TBLB greatly increases the utility of bronchoscopy in the diagnosis of a variety of disease processes. Our finding in this article revealed that TBLB can be beneficial for diagnosis of diffuse interstitial diseases of the lung with a diagnostic yield of 66 percent. TBLB can obviate biopsy through thoracotomy and percutaneous needle biopsy of the lungs which is more invasive and associated with more complications and a greater mortality rate.

REFERENCES

- Anderson HA, Fontana RS, Harrison EG: Transbronchoscopic lung biopsy in diffuse pulmonary disease. *Dis chest* 48: 187-92, 1965.
- Vahedi P: Report of four cases of familial idiopathic pulmonary fibrosis. *Med J Islam Rep Iran* 2:4, 313-6, 1988.
- Shure D: Transbronchial biopsy and needle aspiration. *Chest* 95: 5, 1130-8, 1989.
- Zavala DC: Pulmonary hemorrhage in fiberoptic transbronchial biopsy. *Chest* 70: 584-86, 1976.
- Shure D, Abraham JL, Konopka R: How should transbronchial biopsies be performed and processed? *Am Rev Respir Dis* 126: 342-3, 1982.
- Anders GT, Johnson JE, Bush BA, Mathews JI: Transbronchial biopsy without fluoroscopy: a seven-year perspective. *Chest* 94: 557-60, 1988.
- Simpson FG, Arnold AG, Purvis A, et al: Postal survey of bronchoscopic practice by physicians in the United Kingdom. *Thorax*, 14: 311-7, 1989.
- Milligan SA, Luce JM, Golden J, et al: Transbronchial biopsy without fluoroscopy in patients with deficiency syndrome. *Am Rev Respir Disease* 137: 846-8, 1988.
- Papin TA, Grum CM, Weg IG: Transbronchial biopsy during mechanical ventilation. *Chest* 86: 167-70, 1986.
- Goodman PC, Daley C, Minagi H: Spontaneous pneumothorax in AIDS patients with *Pneumocystis carinii* pneumonia. *AIR* 147: 29-31, 1986.
- Fick MR, Wasson K, Dunn LJ, Block AJ: Fatal pulmonary hemorrhage after transbronchial lung biopsy through the fiberoptic bronchoscope. *Am Rev Respir Dis* 111: 853-6, 1975.
- Papin TA, Lynch IP III, Weg IG: Transbronchoscopy in the thrombocytopenic patient. *Chest* 88: 549-52, 1985.
- Schulman LL, Smith CR, Drusin R, et al: Utility of airway endoscopy in the diagnosis of respiratory complications of cardiac transplantation. *Chest* 93: 960-7, 1988.
- Ellis JH Jr: Transbronchial lung biopsy via the fiberoptic bronchoscope: experience with 107 consecutive cases and comparison with bronchial brushing. *Chest* 68: 524-32, 1975.
- Fletcher EC, Levin DC: Flexible fiberoptic bronchoscopy and fluoroscopically guided transbronchial biopsy in the management of solitary pulmonary nodules. *West J Med* 136: 477-83, 1982.
- Shure D, Moser KM, Konopka R: Transbronchial needle aspiration in the diagnosis of pneumonia. *Am Rev Respir Dis* 136: 565-9, 1987.
- Wallace J M, Cutanzaro A, Moser KM, et al: Flexible fiberoptic bronchoscopy for diagnosing pulmonary coccidioidomycosis. *Am Rev Respir Dis* 123: 286-90, 1981.
- Stover DE, Zaman MB, Hajdu S1, et al: Bronchoalveolar lavage in the diagnosis of diffuse pulmonary infiltrates in the immunocompromised host. *Ann Intern Med.* 101: 1-7, 1984.
- Koerner SK, Sakowitz AJ, Appelmann RI, et al: Transbronchial lung biopsy for diagnosis of sarcoidosis. *N Engl J Med* 293: 268-70, 1975.
- Gilman MJ, et al: Transbronchial lung biopsy in sarcoidosis: an approach to determine the optimal number of biopsies. *Am Rev Respir Dis*, 721-4, 1980.
- Joyner LR, Scheinborn DJ: Transbronchial forceps lung biopsy through fiberoptic bronchoscope: diagnosis of diffuse pulmonary disease. *Chest* 67: 532-5, 1975.
- Wall CP, Gaensler EA, Carrington CB, et al: Comparison of transbronchial and open lung biopsies in chronic infiltrative lung diseases. *Am Rev Respir Dis* 123: 280-5, 1981.
- Wilson RK, Rechner RE, Greenberg SD, (et al): Clinical implications of a "non-specific" transbronchial biopsy. *AM J Med* 65: 252-6, 1978.