

SACROCOCCYGEAL TERATOMA

M.H. KHERADPIR, AND K. MUELLER

From the Department of Pediatric Surgery, Children's Hospital Medical Center, University Clinic of Tehran and Zürich, Iran/Switzerland.

ABSTRACT

31 cases of sacrococcygeal teratoma from the Children's Hospital of Zürich and 25 cases from the Children's Hospital of Tehran are evaluated and compared. In seven cases the tumors were organized. They contained parts of organs or rudimentary extremities. According to general experience the malignancy of tumors is higher in children who are operated on after their second to fourth month of life (35% versus 4.5% in Zürich, 37% versus 0% in Tehran).

Our experience emphasizes the importance of an early extirpation of sacrococcygeal teratoma, even in cases with a relatively small looking external tumor. Because of the risk of a tumor recidive the coccyx should be removed in all cases.

MJIRI, Vol.3, No.3 & 4, 119-124, 1989

INTRODUCTION

From all the various teratomas that are diagnosed in children the tumors of the sacrococcygeal area account for more than 50% of the cases.^{1,5,15} Sacrococcygeal teratomas are rare malformations, accounting for only one case in 35,000 to 40,000 births.

MATERIAL AND METHODS

Between 1939 and 1971, 31 cases of sacrococcygeal teratomas were observed at the Zürich Children's Hospital (M. Grob), and between 1972 and 1984, 25 children with sacrococcygeal teratoma were identified at Tehran Children's Hospital. The purpose of this report is to give further information about our experience with sacrococcygeal teratoma. symptoms, signs, malignancy, cases with organized forms of teratoma and follow-up results.

RESULTS

31 Cases From the Children's Hospital of Zürich:

From 60000 admissions to the pediatric surgical department between 1939 and 1971, there were 31

cases of sacrococcygeal teratoma, amounting to one case in 2000 admissions. 19 cases were seen between 1961 and 1971. The male to female ratio was 2:3, with 12 boys and 19 girls (Table 1). This ratio is different compared to the 600 cases of teratoma reported in the literature, where a ratio of 26% males to 74% females (about 1:3) is shown.

The size of the external visible teratoma varied from 1-15 cm. One highly organized case showed an enormous size so that at first it was thought to be a Siamese twin. It weighed 2180 g. In one third of the cases the tumor developed unilaterally. The surface of the tumors showed no special characteristics. In seven cases we found a predominant growth of tumor onto the presacral and abdominal (retroperitoneal) space, with displacement of the colon and rectum (Fig. 1, a, b). Compression of the ureters or the bladder was noted in three cases. In five cases the tumor was organized, and three of these cases showed a high differentiation with development of rudimentary extremities. The macroscopic examination revealed parts of cystic and solid tumors, in some cases even parts of differentiated organs like bowel, liver, pancreas, brain, testicles, mandible with tongue, pelvis and lower extremity. The histological examination showed malignancy in four cases. Three of the children with malignant sacrococcygeal teratoma were 17, 20 and 36 months old. Two of

Table I. Incidence of 31 Cases of Sacrococcygeal Teratoma from Children's Hospital Medical Center, Zürich

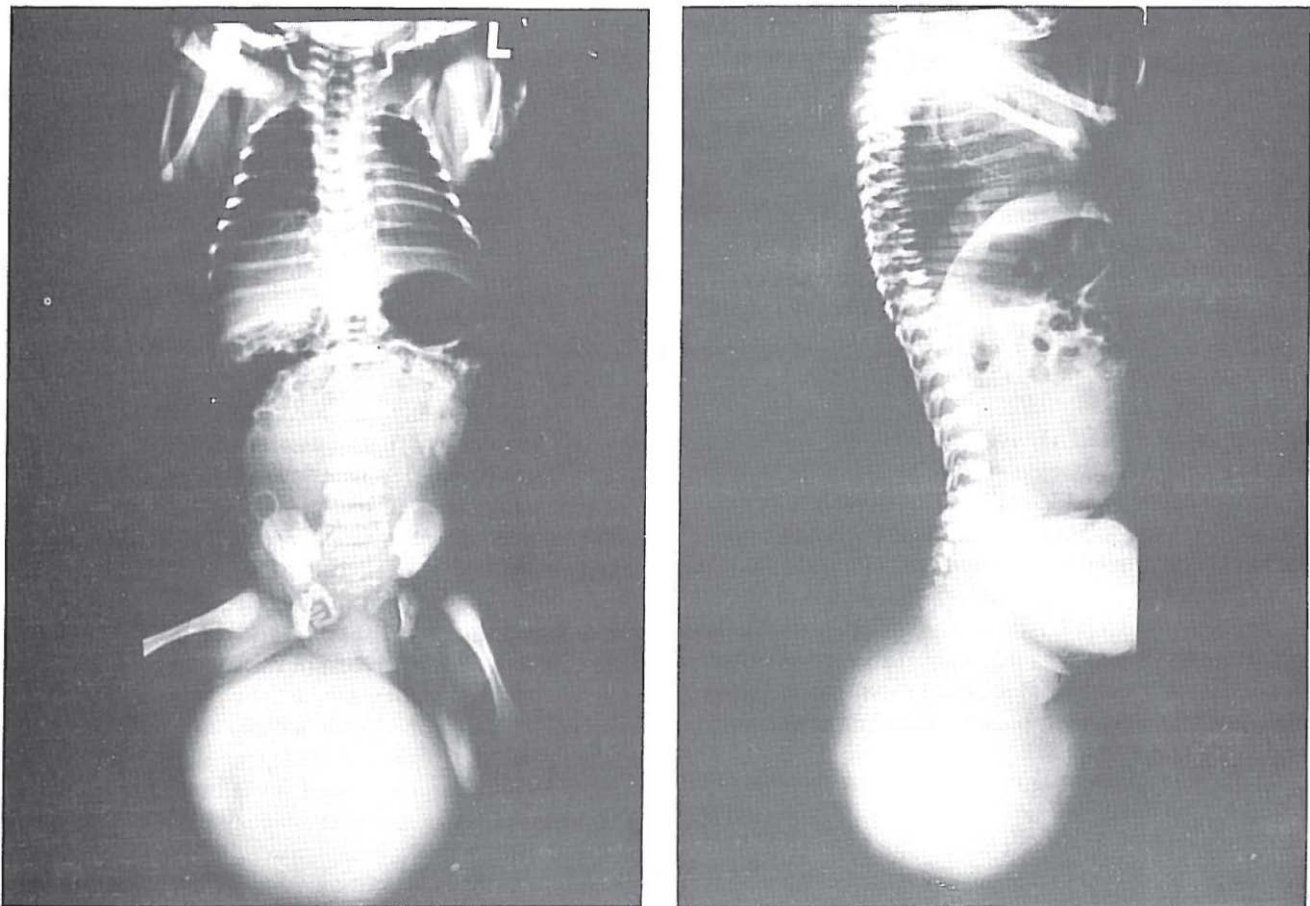
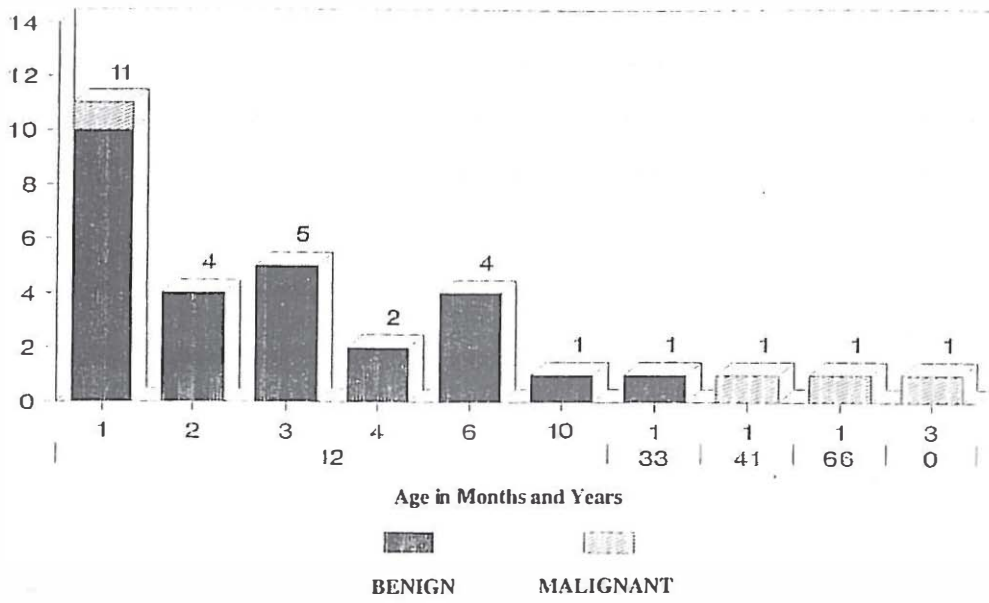


Fig. 1, a, b. Sacrococcygeal teratoma with intensive external and retroperitoneal (abdominal) growth, and upward displacement of the intestines and diaphragm.

Sacrococcygeal Teratoma

them had relatively small tumors and an early referral and treatment was unfortunately considered unnecessary. The histological diagnosis revealed adenocarcinoma in one case and malignant embryonal teratoma in the other. In all three cases we found metastasis in the regional lymph nodes, the liver and the lung and in one case in the spine also. The main clinical symptoms were caused by obstipation and urinary tract obstruction, as well as a feeling of pain while sitting or during defecation. The fourth case was a two-hour old newborn female who was very pale and anemic on admission. A solid superficial exulcerated tumor of about 10 cm was observed on her buttocks. The tumor, which was removed during an emergency operation, was an adenocarcinoma (Fig. 2, a,b).

Calcifications were seen in nine cases (29%). In five cases this was an amorphous calcification, and in four cases we found compact rudimentary bone structures like teeth, small, large and long tubular bones, parts of pelvis and base of the skull. Malignant cases showed no calcification.

The tumor could be removed radically in all the cases, except in one case with a malignant teratoma. In

this case the tumor could only be removed subtotally. In 27 cases the coccyx was completely removed, but in three cases only partially. The one case where the coccyx was not removed initially showed a tumor recidive after 22 years and had to be reoperated.

The mortality rate due to operation was very low. Of 30 operated patients only one baby with a large retroperitoneal tumor died of cerebral bleeding. 22 cases were seen for a follow-up in 1971. Two children suffered from a neurogenic bladder, but all the others were satisfactory.

25 Cases From Tehran Children's Hospital:

From 1972-1984, we observed 25 patients with sacrococcygeal teratoma at the Tehran Children's Hospital, seven boys and 18 girls, with a male-female ratio of 1:2.5 (Table II). The size of the externally visible tumors varied from 5-30 cm. In three cases the tumor was pedunculated (Fig. 3). The surface of the tumors was mostly reddened or cyanotic, and occasionally we found hemangiomas, hair, fistulas and ulcerations. In one newborn baby the tumor was ruptured during delivery and the child had to be operated on at the age of six hours. In one fourth of all cases the tumor was predominantly or completely unilateral. In two cases we found a well developed extremity. In six cases the tumor occupied mainly the presacral and retroperitoneal space; one of these tumors was practically invisible from the outside. In four cases we found compression of the lower urinary tract with development of hydronephrosis and hydroureter. In five cases an external and retroperitoneal growth of the tumor was observed. Most of the patients were admitted because of a visible tumor. Four cases were admitted

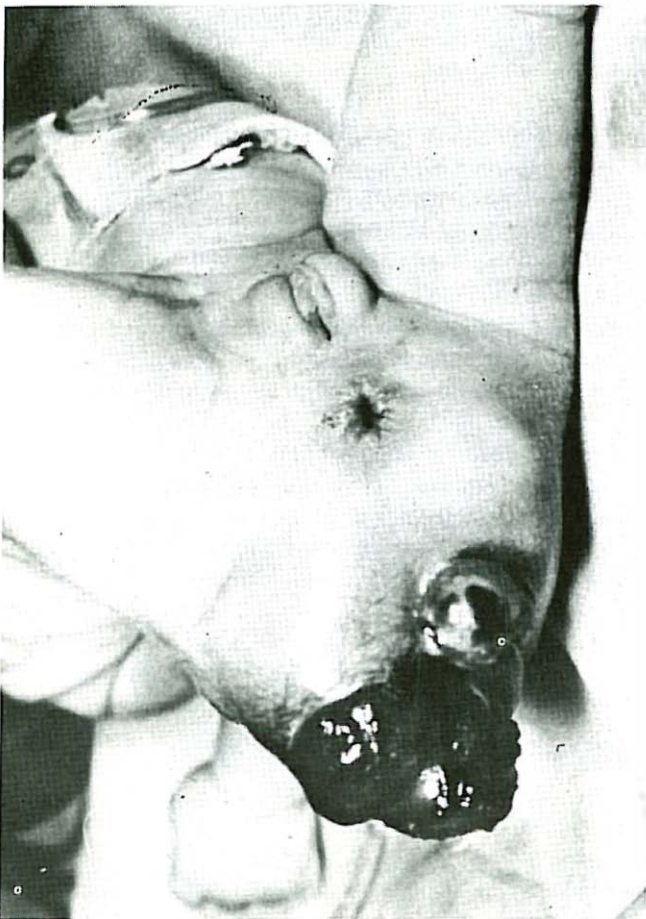

Fig. 2, a. Malignant sacrococcygeal teratoma in a newborn baby with exulceration and cyanosis on the external surface. The anus is typically anteriorly displaced by the tumor.

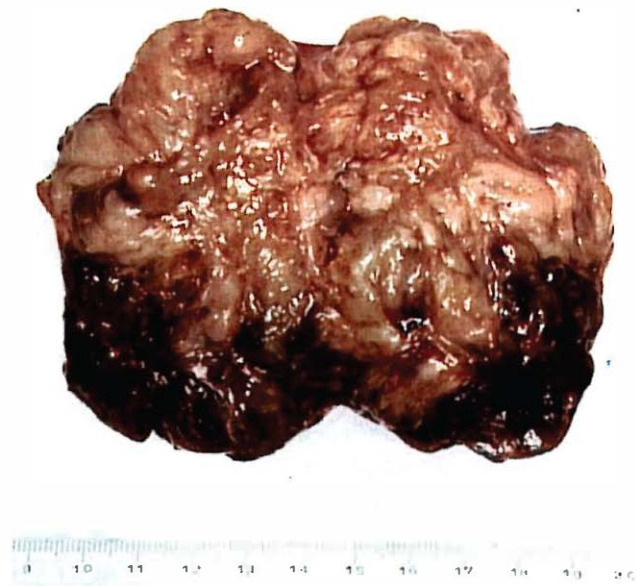


Fig. 2, b. Malignant sacrococcygeal teratoma. Cut surface of the solid tumor with cyanotic lower part.

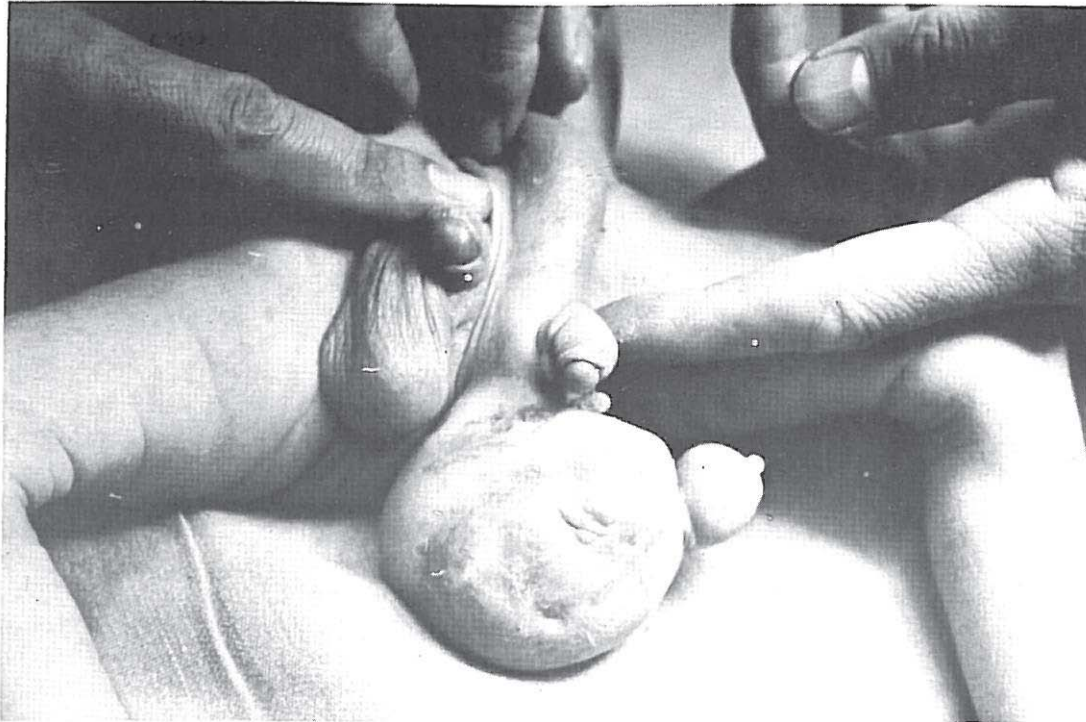


Fig. 3. Pedunculated sacrococcygeal teratoma with exposed penis, bifid scrotum and hypospadias. The penises are upheld with the fingers.

because of pain, obstipation, or obstruction of the urinary tract and one case because of an abdominal mass. The malignant cases were referred because of painful tumor on the buttocks (2), exulcerated tumor (1), and incontinence and pain while walking (1). All of

them showed presacral and retroperitoneal growth (Fig. 4).

Calcifications were seen in 11 cases (44%); in six cases they were amorphous and in five cases we found rudimentary bone structures like teeth, small and large

Table II. Incidence of 25 Cases with Sacrococcygeal Teratoma from Children's Hospital Medical Center, Tehran

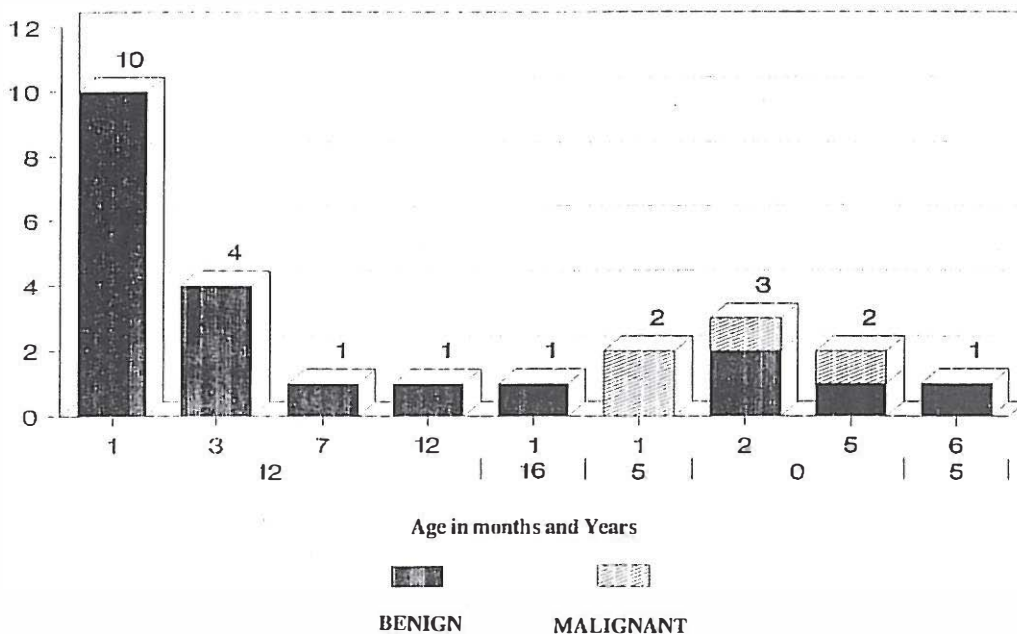

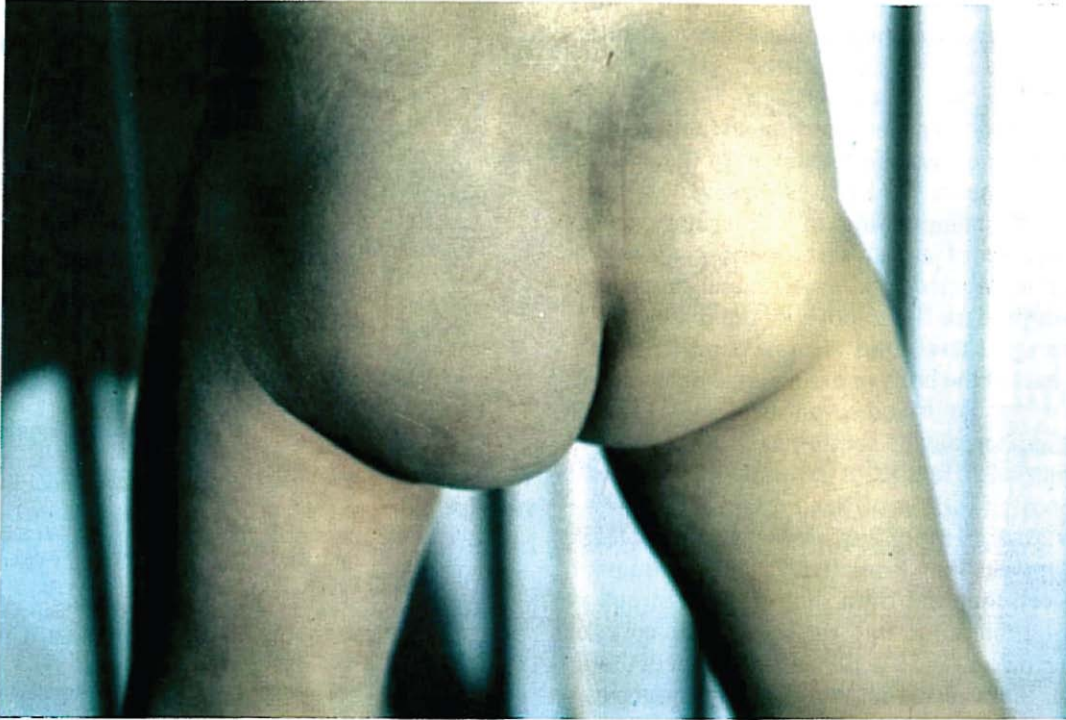


Fig. 4. Malignant sacrococcygeal teratoma in a five year old girl. The asymmetrical appearance of the buttocks is caused by growth of tumor on the right side. This asymmetry was overlooked for two years. On admission we found metastasis in the lymph nodes and the lungs.

long tubular bones, and parts of pelvis and skull.

In half of the cases the tumor and coccyx were radically removed. In one third of the cases only the tumor was removed. Three malignant cases with distant metastasis and extensive retroperitoneal growth were not operated. One patient died because of sepsis and another one because of aspiration pneumonia. In one case we found a recidive of the tumor because the coccyx was not removed initially. The tumor was again benign.

At the time of operation 14 patients were newborns or below the age of four months, 11 patients were older than four months, and the oldest was 6.5 years old. The patients with malignant teratoma were 17 months, one and a half, two and five years old, with three girls and one boy.

The macroscopic examination showed cystic and solid tumors, some with parts of differentiated organs like colon, adnexes, brain, kidneys, liver, pancreas and extremities. We found metastasis in the regional lymph nodes, lungs, spine and sacrum.

DISCUSSION

Sacrococcygeal teratomas are usually cystic-solid masses which histologically contain derivatives from all three germ layers, since theoretically they originate

from the pluripotent cells of Hensen's knot which shift to the coccyx region during their early embryonic development.^{3,5-7,9} Usually, they contain different tissues of irregular patterns. The pathologist Rindfleisch called this a histological *potpourri*. Histologically, they contain mature, immature and malignant tissues. Mature teratomas contain differentiated structures, which pathologists name adult teratomas. Immature teratomas, called embryonal teratoma, contain undifferentiated tissues and are potentially malignant, so that they tend towards malignancy. This applies particularly to recurrent cases, where the tumors were not completely removed. On the other hand, experience has shown that the frequency of malignant sacrococcygeal teratoma depends particularly on the age of the patient and the time of the operation. In children where the operation was performed before the age of two to four months, the malignancy was 6-10%, but after this age, the malignancy was more than 50%.^{1,3,5,7,8,13,15} Four months would appear to be a critical age for treatment, the incidence of malignancy rising sharply after this age. This was also confirmed in our material.

Malignancy usually appears in a solid tumor (malignant teratoma). The small tumors in the coccyx region in particular are more likely to develop malignancy, since these are neglected or overlooked by the parents as well as their doctors. Three of our patients appeared with a small external tumor, so that the examining

doctor thought that it is not necessary to provide treatment or admission to the hospital. On admission at a later stage they showed metastasis in the regional lymph nodes, lung and, in one of them, the liver and vertebrae. A presacral or retroperitoneal (abdominal) growth of the tumor with displacement of the rectum and colon was observed in 13 cases. In seven of these cases there was compression of the urinary tract. Obviously, in cases of intensive retroperitoneal growth of tumor a combined abdomino-sacral approach should be adopted for the removal of the tumor.

Sacrococcygeal teratomas are rarely organized to resemble a part of the body or extended to an aberrant extremity.^{4,5,12-15} We found seven such cases. One of these so called "organized teratomas," consisted of a double penis, one arising out of the tumor. No such case has been reported in the available literature until now.

For the rare organized form of sacrococcygeal teratoma we suppose that a relatively large amount of embryonal cell material from the primitive streak is shifted during migration into the area of the coccyx. This can lead on one hand to the development of tissue that contains the derivatives of the three different germ cells lying next to each other in an irregular pattern, and on the other, organized structures or well-developed organs or parts of organs. More difficult to explain is the formation of organized teratomas at ectopic places. In this case we could suppose that there must be a considerable amount of pluripotent cells, which shift away from the primitive streak during early embryonal development and start to form organized teratomas. To differentiate between twin malformations, Siamese twins, and organized sacrococcygeal teratoma one should consider the presence or absence of a spine.

ACKNOWLEDGMENT

We would like to thank Prof. U. Stauffer for permitting publication of the cases from the Children's Hospital of Zürich.

REFERENCES

1. Altman P R, Randolph J G, Lilly J R: Sacrococcygeal teratoma: American Academy of Pediatrics surgical section survey. *J Pediatr Surg* 9: 389-398, 1974.
2. Carney J A, Thompson D P, Johnson C L, Lynn H B: Teratomas in children: clinical and pathologic aspects. *J Pediatr Surg* 7: 271-282, 1972.
3. Donnellan W A, Swensons O: Benign and malignant sacrococcygeal teratoma. *Surg* 64: 834-846, 1968.
4. Dillard B M, Mayer J H, McAlister W H, McGavrin M, Strominger D B: Sacrococcygeal teratoma in children. *J Pediatr Surg* 5: 53-59, 1970.
5. Gross R E, Clatworthy W H, Meeker I A: Sacrococcygeal teratomas in infants and children; a report of 40 cases. *Surg Gynec Obstet* 92: 341-354, 1951.
6. Grob M: Steissteratom, *Lehrbuch der kinderchirurgie* 609, 1957, Verlag Thieme Stuttgart.
7. Hofmann V V: Das sacrococcygeal teratom. *Z. Kinderchir.* 3: 519-531, 1966.
8. Hunt P, Leeuwen G V, Bingham H, Sights W: Sacrococcygeal teratomas: a report of three cases and survey of present knowledge. *Chir Pediatr* 7: 165-169, 1968.
9. Hamilton W J, Boyd J D, Mossman H W: *Human Embryology*. 139-51, Cambridge, W. Heffer & Sons, Limited, 1959.
10. Mahour H G, Woolley M M, Trivedi S N, Landing B H: Sacrococcygeal teratoma: a 33-year experience. *J Pediatr Surg* 10: 183-188, 1975.
11. Noseworthy J, Lack E E, Kozakewich H P W, Vawter G F, Welch K J: Sacrococcygeal germ cell tumors in childhood: an updated experience with 118 patients. *J Pediatr Surg* 16: 358-364, 1981.
12. Nicholson G W: Studies on tumor formation; a sacrococcygeal teratoma with three metacarpal bones and digits. *Guy's Hosp Rep* 87: 46, 1937.
13. Lehner M, Rickham P P: Sacrococcygeal and spinal teratomas. *Neonatal Surgery*, p. 115-123, London, Butterworths.
14. Taniguchi K, Aoki Y, Kurimoto H, Okomura T: Baby with third leg. *J Pediatr Surg* 10: 143-144, 1975.
15. Vacz-Zadeh K, Sieber W K, Sherman F E, Kiesewetter W.B: Sacrococcygeal teratomas in children. *J Pediatr Surg* 7: 152-156, 1972.
16. White J J, Wexler H R: A baby with a tail. *J Pediatr Surg* 8: 833-834, 1973.