

NEUTROPHIL CHEMOTACTIC DEFECT IN 60 PATIENTS WITH RICKETS

A. FARHOUDI, M.D., MORADINEJAD, M.D., AND T. SEPEHRZAD

*From the Immunology and Allergy Dept., Children's Medical Center, Tehran University of Medical Sciences,
Tehran, Islamic Republic of Iran.*

ABSTRACT

Neutrophil mobility in 60 patients with vitamin D-deficient rickets is studied, and the patients are followed after therapy by 600,000 units vitamin D. 28 of 60 patients (46%), had low chemotaxis for neutrophils before vitamin D injection (migration), and 36 of 60 (60%) had low random mobility. The results showed a significant improvement after vitamin D therapy; furthermore, the level of calcium and phosphorus reached normal levels after treatment of the patients as well. We have previously studied neutrophil mobility in 10 patients with rickets.² This report serves to complement our previous preliminary report.

MJIRI, Vol.3, No.3 & 4, 169-173, 1989

INTRODUCTION

The clinical observation that recurrent respiratory infections are associated with vitamin D-deficient rickets led us to investigate the relationship between vitamin D deficiency and a defect in the immunological system.

In the review of the literature very few reports exist that describe a neutrophil chemotaxis defect in patients with vitamin D-deficient rickets.^{1,2}

The association of the chemotactic defect and recurrent infections could be primary or secondary to various diseases such as diabetes mellitus, hepatic cirrhosis, rheumatoid arthritis, and Down's syndrome.³

These facts prompted us to investigate neutrophil chemotaxis in 60 patients with rickets.

In this study, our aim was to determine the efficiency of the immune system, particularly neutrophil mobility, in children with vitamin D-deficient rickets.

MATERIALS AND METHODS

Studies were performed on 60 children diagnosed clinically and paraclinically as having rickets in the

Department of Immunology and Allergy, Children's Medical Center, Tehran University of Medical Sciences during the year 1987-88. These patients were also radiologically diagnosed as having rickets.

The age of the patients ranged from 12 to 24 months. All children had a history of recurrent respiratory infections, convulsions, or gastrointestinal tract infections.

Serum IgG, IgA, IgM, C₃ and C₄ were measured by the Mancini (RID)⁴ Radial Immunodiffusion technique (Behring Manufacture).

Total hemolytic complement levels (CH₅₀) were detected by the method of Mayer,⁵ and the chemotaxis test for PMN was performed using the modified technique of Boyden.^{6,7}

To measure neutrophil mobility, PMN were separated from heparinized blood by 6% dextran sedimentation, washed in Hank's medium, and resuspended at 2 ml.

Chemotactic factor was generated from the serum of a healthy donor by *Escherichia coli* endotoxin (Difco) in Hank's medium.

The mobility of the PMN in 0.25 ml of this suspension through a millipore membrane of three microns pore size was measured by the method of Boyden, Agget, and Farhodi.^{6,8}

After three hours of incubation, the membrane

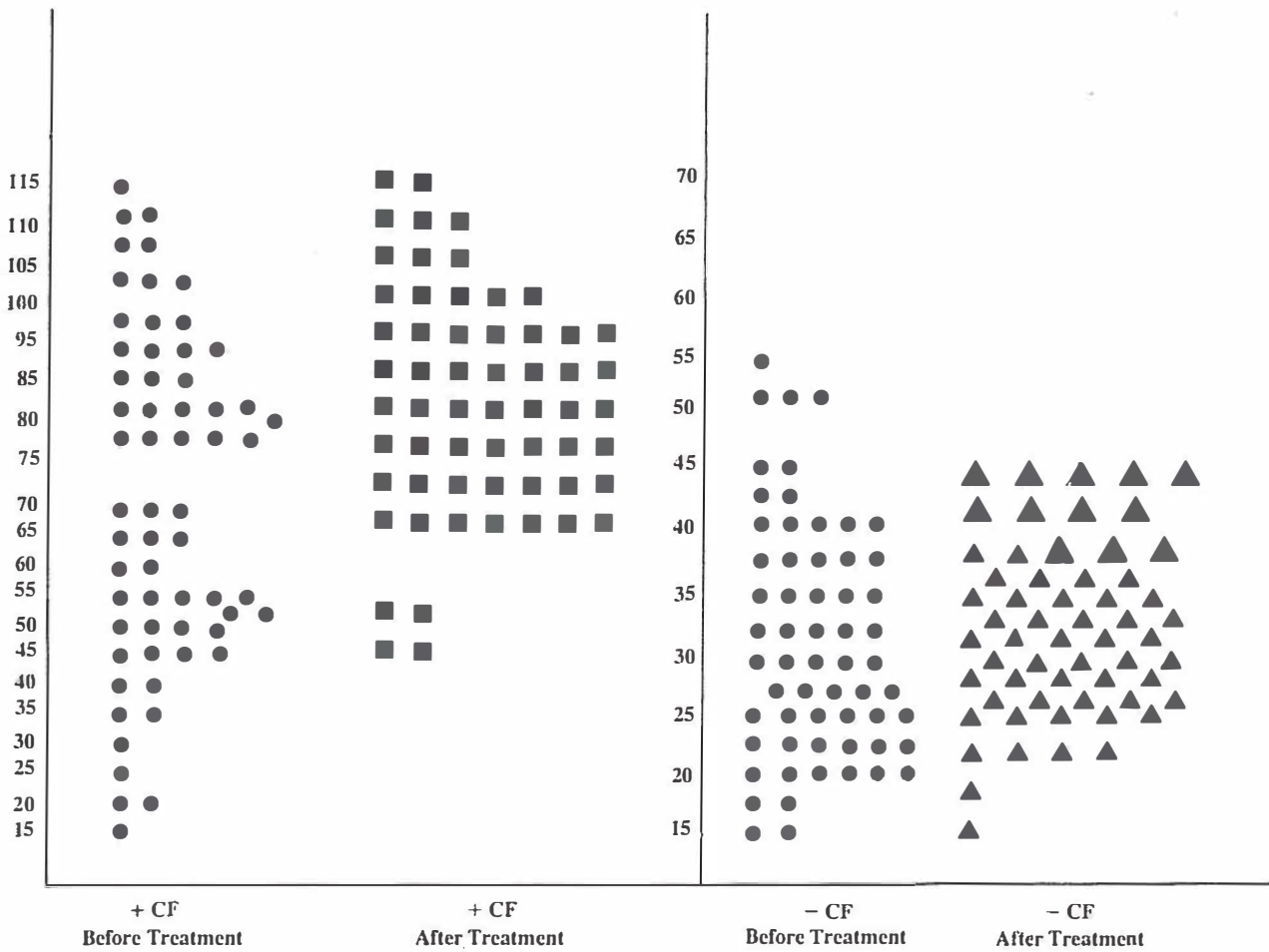


Fig.1. Immunological findings in 60 patients with rickets.

was separated, washed free of red cells stained with hematoxylin and mounted on slides. The values of 75 and 40 microns were chosen for determining defective mobility in migration and random mobility, respectively.⁷ Healthy age-matched children were used as controls (Fig. 1).

RESULTS

We have studied previously defective neutrophil mobility in 10 patients with rickets.² In this study we tried to evaluate this abnormality of the neutrophil chemotaxis in 60 patients with rickets and followed them before and after treatment by intramuscular administration of vitamin D.

We have looked at the level of calcium and phosphorus during this work. the results of which are as follow:

As shown in Table I and Fig. 1, 28 of 60 patients (+

CF) had low mobility (46%), while 36 of 60 had low random mobility (-CF) (60%). However, neutrophil mobility became approximately normal after therapy by intramuscular vitamin D.

On the other hand, P value was significant as follows:

Table I.

Neutrophil Chemotactic Defect (Before Treatment)		
+CF	28	46%
-CF	36	60%
Neutrophil mobility result (After treatment)		
+CF	35	92%
-CF	30	83%

Defective Neutrophil Mobility

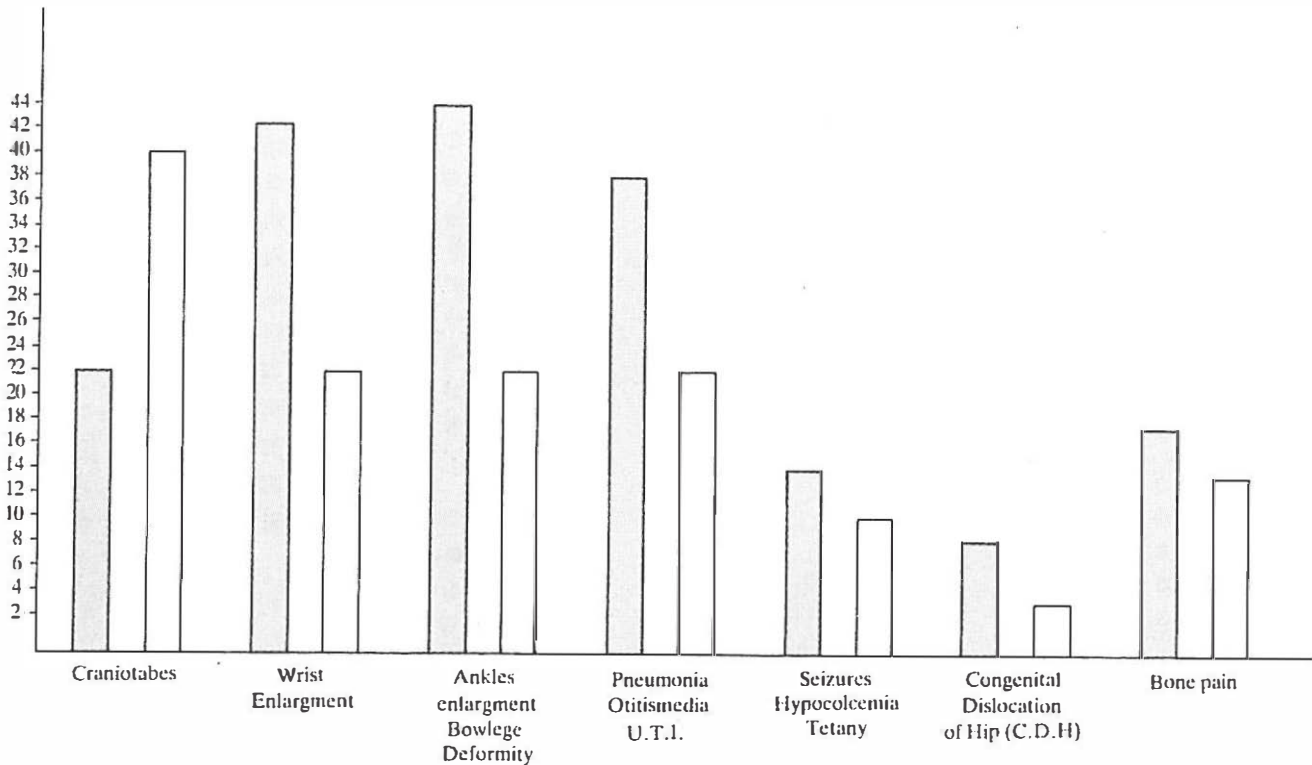


Fig.2. Clinical findings in 60 patients with rickets.

$$\begin{aligned}
 &+ \text{CF} = 73 \pm 7.5 \\
 &- \text{CF} = 34 \pm 1.7 \\
 &P < 0.0001
 \end{aligned}$$

The serum calcium and phosphorus levels are shown in Fig. 3 as follows: 28 of 60 patients had low levels of phosphorus (46%), three of which (5%) persisted after

Table II.

The age, sex, clinical manifestations, and non-immunological findings are shown in the following tables.

CLINICAL FINDINGS	NUMBER	MALE	FEMALE	AGE
Cranio-tabes	24(60%)	14	10	12 m
Wrist enlargement	39(65%)	24	15	12-24 m
Ankle enlargement Bow leg deformity	42(70%)	23	19	12-24 m
Pneumonia Otitis media U.T.I.	36(64%)	23	16	4-36 m
Seizures Hypocalcemia tetany	13(21%)	8	5	4-12 m
C.D.H.	8(13%)	6	2	2-3 m
Bone Pain	15(25%)	10	5	Over 3 years

vitamin D therapy.

Of 60 patients, 12 had low calcium levels before treatment and normal values were observed in all of them after vitamin D administration.

The results of the clinical features are shown in Table II as follows: cranio-tabes in 24 (60%), wrist enlargement in 39 (65%), pneumonia in 36 (65%), and convulsion in 13 (21%).

Neutrophil mobility was studied in 60 patients with vitamin D deficiency rickets before and after therapy. It was observed that the mobility of PMNs in the presence and absence of chemotactic factor was defective before treatment by vitamin D in 28 (46%) and 36 (60%) of the patients, respectively; and normal values were found after therapy:

$$\begin{aligned}
 &+ \text{CF} = 73 \pm 7.5 \\
 &- \text{CF} = 34 \pm 1.7 \\
 &p < 0.0001
 \end{aligned}$$

Serum calcium and phosphorus levels also changed as shown in the Tables in detail.

DISCUSSION

Due to a defect in neutrophil chemotaxis, a necessity of phagocytosis, patients with vitamin D-deficient

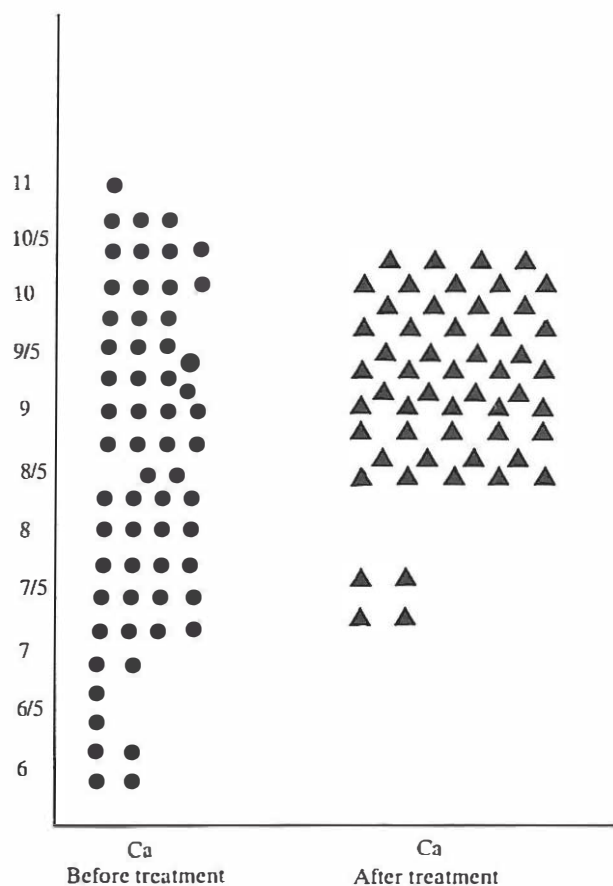


Fig.3. The level of calcium.




Fig.4. The level of phosphorus.

rickets are more susceptible to recurrent infections.²

A secondary neutrophil mobility defect has been described in various diseases such as diabetes mellitus, rheumatoid arthritis, and Down's syndrome.³

Our study as well as other reports indicate that there is a secondary neutrophil mobility defect in patients with vitamin D-deficient rickets. It is likely that this impairment is the main, if not the only, factor which explains the reason for recurrent infections in these patients. Although the precise mechanism of the neutrophil mobility defect in rickets has not been established, certain hypotheses exist in this regard.

There are a number of proteins such as actin and myosin that form filamentous and microtubulous structures in leukocytes. These proteins are structurally and enzymatically similar to the actin-myosin system in muscles.⁹ Neutrophil movement is therefore probably achieved by the contraction of these microfilaments.¹¹ The polymerization and depolymerization of the actin network, which has the tubulin skeletal system under control, appears to be essential for many functions of the neutrophil, including attachment to surfaces, phagocytosis, movement, and degranulation.^{13,14} It is

postulated that hypocalcemia and hypophosphoremia in vitamin D-deficient rickets may produce sufficient intracellular changes to interfere with normal contractility of the microfilaments and thus impair leukocyte mobility.

Since normal calcium and phosphorus metabolism is essential for the contraction of intracellular microfilaments, hypophosphatemia in vitamin D-deficient rickets can be considered as a responsible factor that interferes with the normal contractility of microfilaments resulting in impaired leukocyte mobility.

Recently, investigators have suggested a possible role for the calcium channels in the T-lymphocyte release of lymphokines and chemotactic factors which interfere with neutrophil mobility.

It is postulated that this role of calcium in patients with vitamin D-deficient rickets affects neutrophil chemotaxis and influences susceptibility to infections as well.

Additional investigations are necessary to clarify and elucidate the essential etiological role of vitamin D deficiency in defective neutrophil mobility.

Defective Neutrophil Mobility

REFERENCES

1. Lorie FG, et al: Defective neutrophil mobility in hypovitamin D rickets. *Acta Med Scand* 65: 695-9, 1976.
2. Farhoudi A: Defective neutrophil mobility in 10 patients with rickets, *Med J Islam Repub Iran* 2(1): 29-31, 1988.
3. Clark RA: *Disorders of Granulocyte Chemotaxis*. Raven Press, N.Y., Page: 329-356.
4. Mancini G, Carbonaro AO: Immunochemical quantitation of antigens by single radial immunodiffusion. *Immunochemistry* 2: 235, 1965.
5. Mayer MM: *Complement in Experimental Immunology*. Springfield III, Page 188-203, 1961.
6. Boyden SV: The chemotactic effect of mixtures of antibody and antigens on PMN. *J Exp Med* 115: 453-66, 1962.
7. Farhoudi A, Harvey BAM, Soothill JF: Clinicopathological findings in patients with primary and secondary defect on PMN. *Arch Dis Child* 53(8): 625-30, 1978.
8. Aggett PJ, Harris JT, Harvey BA, et al: An inherited defect of neutrophil mobility in Shwachman Syndrome. *J Pediatr* 94(3): 391-4, 1979.
9. Allison AC, Davies P, Depetris S: Role of contractile microfilaments in macrophage movement and endocytosis. *Nature (New Biol)* 232: 153-5, 1971.
10. Clerke M, Spudich JA: Non-muscle contractile proteins. The role of actin and myosin in cell mobility and shape determination. *Ann Rev Biochem* 16: 797-822, 1977.
11. Pollard, Greeg: Mechanism of active polymerization. *Trends Biochem Sci* 7: 55-8, 1982.
12. Burnside B: The form and arrangement of microtules: a historical, primarily morphological, review. *Ann NY Acad Sci* 253: 14-26, 1975.
13. Oliver JM: Cell biology of leukocyte abnormalities-Membrane and cytoskeletal function in normal and defective cell. *Am J Path* 93(1): 221-59, 1978.
14. Segal AW: Testing neutrophil function. *Clin Immunol Allergy* 5: 491-511, 1985.