

Management of tibial non-union using reamed interlocking intra-medullary nailing

Siroos Malekpoor, MD.¹, Mehdi Moghtadaei, MD.², Ehsan Akbarian, MD.³,
Soheil Hamedanchi, MD.⁴

Department of Orthopedic Surgery, Rasul-e-Akram Hospital, Tehran, Iran.

Abstract

Background: Reamed interlocking intramedullary nailing of the tibia is a procedure for the treatment of a non-infected tibial nonunion. The purpose of this clinical study was to evaluate the outcome of this method as a treatment of tibial nonunion.

Methods: Twenty-nine patients with nonunion after initial therapy for tibial fracture were retrospectively assessed after a reamed interlocking intramedullary nailing. The main measurements were derived from radiographic and clinical union as well as time from reamed nailing to union.

Results: Twenty-eight patients achieved union of their fracture (97%). The average time from reamed nailing to union was 7.6 months. Serious complications included one severe infection in the site of surgery (3%) and one tibial fracture distal to the nail (3%).

Conclusion: Reamed interlocking intramedullary nailing for nonunions of the tibia resulted in a high union rate and was associated with a low complication rate. This technique is recommended as a standard procedure for non-infected tibial nonunions.

Keywords: tibial fracture, tibial nonunion, tibial delayed union, reamed interlocking intramedullary nailing.

Introduction

Despite recent developments in fracture treatment and in spite of aggressive and uncomplicated initial stabilization, cases of failed union after a long bone fracture still are encountered. In many cases, it is difficult to determine at the time of initial treatment which fractures will unite and which will require additional procedures to achieve union. Nonunion of the tibial fractures is a serious complication prolonging patient morbidity, time lost from work, and economic hardship. Moreover, nonunion and re-

peated surgeries are a cause of considerable pain and disability in these patients because of stiffness of neighboring joints, deformity, and limb length discrepancy. Better understanding of the mechanics of fracture stabilization and of biologic requirements of fracture healing has improved the outcome in these difficult cases[1].

It is important to consider the possibility of infected versus non-infected cases, and the potential for healing whether it is hypertrophic (viable) or atrophic (nonviable) for planning the nonunion treatment. Broadly the principles of treatment can be outlined as provision of stabil-

1. Assistant Professor of Orthopedic Surgery, Rasool-e-Akram General Hospital, Iran University of Medical Sciences, Tehran, Iran.

2. **Corresponding author**, Assistant Professor of Orthopedic Surgery, Rasool-e-Akram General Hospital, Iran University of Medical Sciences, Tehran, Iran. Email: mmoghtadaei@gmail.com, Telefax: +9821 66507059

3. Researcher, Rasool-e-Akram General Hospital, Iran University of Medical Sciences.

4. Resident of Orthopedic Surgery, Rasool-e-Akram General Hospital, Iran University of Medical Sciences.

ity, osteogenic potential, and control of infection. Viable bone fragments, adequate autogenous bone grafts, and bone marrow surrounded by a well-vascularized soft tissue envelope can serve as a reservoir of mesenchymal cells, which are capable of transforming into cartilage and bone-forming cells. A successful outcome can be achieved by simple functional cast bracing [2], stable fixation with or without bone grafting [1,3-6], exchange nailing [7-9], external fixation [10], and two-stage procedures [10].

Intramedullary nailing is a standard procedure in the treatment of closed and open tibial shaft fractures. Favorable results have been achieved using both reamed and unreamed techniques, with recent reports noting a 90% union rate [11-13]. This implant is thought to provide adequate mechanical stability. However, non-reamed tibial nailing is not without complications: Implant failure, usually screw breakage, and delayed fracture consolidation often compromise clinical outcomes [11,14-16]. Furthermore, experimental investigations have shown that reaming increases periosteal circulation, which may benefit callus formation and union [17]. It has been shown that reamed intramedullary nailing of lower extremity long bone fractures significantly reduces rates of nonunion and implant failure in comparison with non-reamed nailing [18]. Unlocked nailing for tibial shaft fractures is a simple and valuable method especially in the treatment of middle-third fractures but cast immobilization is required due to its essentially poor control of rotation [19]. Interlocked nailing gives stable fixation without cast immobilization, which results in a greater ability for the patients to return to their previous work 6 months after surgery [20].

Our method to treat non-union and delayed union was to perform an interlocked intramedullary nailing with reaming. This method achieves the two basic principles of treatment: stable fixation of the fracture site and physiologic inter-fragmentary compression by early weight bearing. Experience with this technique

for the femur has shown it to be safe and effective [21]. However, its application for the tibia is more controversial, and there is much less experience than its use in the femur.

For these reasons, the indication, technique, and outcome of reamed interlocking intramedullary nailing in the tibia require further clarification. Therefore, the purpose of this clinical study was to evaluate the results of this technique.

Methods

From the 2003 to year 2005, 29 consecutive patients with a non-infected tibial delayed union or nonunion after initial therapy were admitted and treated by protocol using reamed interlocking intramedullary nail at our center. There were 27 male and 2 female with a mean age of 34 years old ranging from 18 to 64 years old.

Inclusion criteria were as follow: initial treatment of the tibial shaft fracture associated with a non-infected nonunion or delayed union of the tibial shaft. Exclusion criteria included infected nonunion or infected delayed union as determined by biochemical or clinical markers and inappropriate site of fracture for performed intramedullary nailing.

Terminology

A nonunion was considered to be established when there was no bridging cortical bone on at least three of four cortices using antero-posterior and lateral radiographs and the fracture site did not show any visible progressive signs of healing within 6 months on serial radiographs. Delayed union was also taken into account when the fracture site did not show any visible progressive signs of healing within 3 months after the fracture. Union was defined as painless full weight bearing combined with bridging cortical bone on at least three of four cortices on antero-posterior and lateral radiographs [22,23]. A malunion was defined as more than 5 degrees of varus/valgus; more than 10 degrees

Initial treatment	Cases	%
Plate and screw	2	7%
Close reduction and casting	3	10%
Intra-medullary nailing		
With reaming	1	3%
Without reaming	3	10%
External fixation	20	70%

Table 1. Initial treatments after the fractures.

of anterior/posterior angulation; more than 15 degrees of rotation; or shortening of more than 1 cm [23-25]. Malrotation was evaluated by comparing the amount of rotation with the uninjured lower extremity. After identification of the patients, a careful retrospective review of radiographs and medical records was performed to document mechanism of injury, associated injuries, associated soft-tissue damage, associated diseases, smoking habits, type of nonunion, additional procedures, and date of achieved union.

Initial presentation and treatment

Fracture sites were in 5 cases (17%) in the proximal one-third tibia, 18 cases (62%) in the middle one-third tibia, and 6 cases (21%) in the distal one-third tibia. Among all patients, 27 fractures (93%) were originally open injuries (Fig. 1.): type I (2 cases, 7%), type II (4 cases, 14%), and type III (21 cases, 72%): type IIIA (9 cases, 31%) and type IIIB (12 cases, 41%). The initial treatments of our cases are listed in table 1, while two patients (7%) had autogenous iliac crest bone grafting at the time of previous surgery. Among all 29 cases, 19 cases (66%) developed an atrophic....., whereas 10 cases (34%) presented with hypertrophic delayed or non union. Mean of the period between the previous treatment to admission in our center and perform the operation was 14 months ranging from 5 to 24 months.

Pre-operative infection workup

The presence of an infected nonunion was carefully scrutinized in all patients by protocol. Each patient was screened for clinical signs of

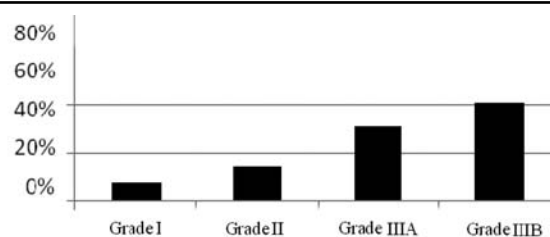


Fig. 1. Distribution of open fractures in types.

infection and biochemical markers including complete blood count, erythrocyte sedimentation rate, and C-reactive protein. In addition, intra-operative cultures were obtained from the fracture site or the intra-medullary canal and an immediate Gram's stain was performed on all patients. According to our protocol, patients who were not considered for performing reamed nailing if they had any screening marker suggested an infected nonunion. Patients with positive preoperative infection signs or positive intra-operative Gram's stains were managed with nail removal, reaming of the intramedullary canal, debridement, external fixation, 6 weeks of antibiotics, and eventually autogenous bone graft. Patients were not discharged from the hospital until the final results of the aerobic and anaerobic intra-operative cultures were obtained.

Treatment and procedures

Standardized methods for administrating prophylactic antibiotics (intravenously administrating 1 gram of cefazolin every six hours starting at the operation room and continued for 72 hours) were followed and the reamed interlocking IMN technique was performed for all patients. In all cases the fracture sites were appropriate for performing intramedullary nailing (from 4cm distal to the tibial tuberosity to 4cm above the plafond) and no infectious collections or drainage were seen in the place. According to the surgeon's preference, a fibulectomy was performed. The average operative time of the reamed nailing procedure was 85 minutes (range, 50–150 minutes) and the average approximate external blood loss was documented

	Cases	%
Age	Mean: 34 years Range: 18 – 64	
Sex		
Male	27	93%
Female	2	7%
Smoking	6	21%
The side of tibial fracture		
Right leg	18	62%
Left leg	11	38%
Background disease		
Hypertension	2	7%
Diabetes mellitus	1	3%
Mechanism of injury		
Motorcycle accident	14	48%
Pedestrian accident with car	12	41%
Falling from height	1	3%
Car crash	2	7%
Associated injury		
Fracture of the humerus	1	3%
Trauma to the chest	1	3%
Rupture of the spleen	1	3%

Table 2. General and demographic information.

as 210cc (range, 50cc–500cc). The postoperative protocol restricted the weight bearing in patients for 2 weeks after reamed nailing to allow for soft-tissue healing process. After 2 weeks, full weight bearing was permitted. The standard follow-up intervals were 2, 6, 10, and 16 weeks, and every 6 weeks thereafter until full recovery.

Results

The mean follow up was 2.9 years ranging from 1 to 4 years. General and demographic information of the patients are shown in Table 2. All 29 patients were interviewed and examined. The average length of time for fractures to achieve union was 7.6 months. Except one, all the patients (97%) had gradual improvement of their failed union and achieved union.

For 20 patients, the operation was done through a close fixation and the fracture surrounding remained intact. In this group, union achieved with the mean time of 7.1 months ranging from 5 to 11 months. The remaining 9 patients who had autogenous bone grafting

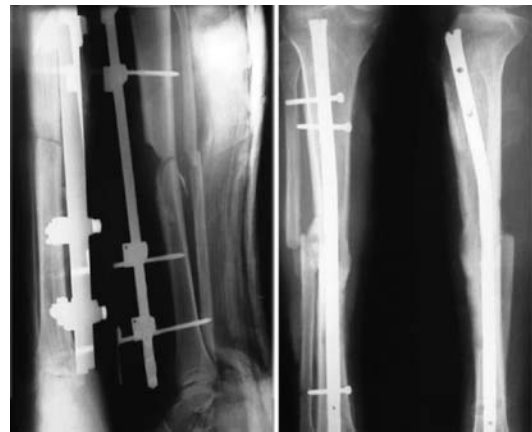


Fig. 3. The left picture shows a tibial non-union after using external fixation. The right one depicts union achievement after 8 months of the surgery by IMN and bone grafting.

from iliac crest due to their atrophic non-unions, achieved union with the mean time of 8.7 months ranging from 5 to 15 months. Nevertheless, fibular osteotomy was performed in 5 cases. Figures 3 and 4 depict two cases with non-union before and after the surgery.

The only patient with nonunion after our procedures, was a 42 year old man with an open fracture, type IIIB that had gone under external fixation on the previous operation. After 12 months, he was admitted to our center and after removing the EF, antibiotic therapy was performed for 2 weeks. Consequently, he underwent our procedure for close fixation of reamed

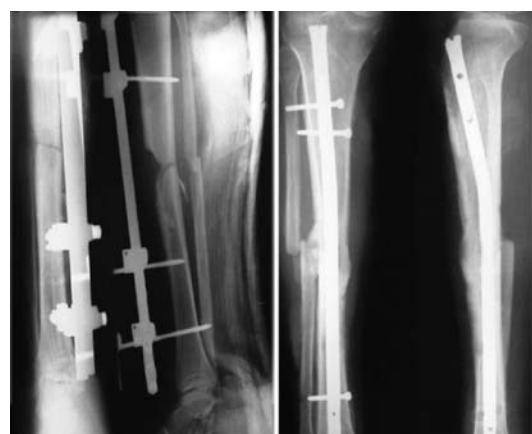


Fig. 4. The left picture shows a tibial non-union after using IMN as the primary treatment. The right one depicts union achievement after 9 months of the surgery by IMN exchange and bone grafting.

interlocking IMN, but a severe infection at the site was seen after 6 weeks; therefore, Ilizarov system was fixed as a treatment.

In 2 cases (6.8%), superficial infection was seen in the site of screws and was handled by removing the screws, irrigating, debriding, and antibiotic therapy. Checkrein deformity occurred in a 30 year old man who underwent the surgery for a distal fracture of tibia and was treated with lengthening of the flexor hallucis longus. In one patient, a fracture was noted at the distal to the nail which was taken care of with casting. Valgus deformity (15° and 12°) was also seen in 2 cases (6.8%) that was taken place in distal fractures. Bone shortening (2cm and 3cm) was noted in 2 cases which was treated with heel lifting. In 10 cases (34%), decreased range of motion (15° to 20°) was seen in ankle and was more often in the patients with history of burdening a long time external fixator. Six cases (20%) had a decreased range of motion (about 15°) in the knee joint. Moreover, two patients suffered from a discomfort where the graft was taken from and eight patients (28%) complained from a knee pain that was tolerable.

Discussion

The management of delayed union and nonunion of the tibia is one of the most challenging problems facing the orthopedic surgeon. Nonunion of the tibia is considered the most frequently observed long bone nonunion; and its importance as a weight-bearing bone underlies the need for predictable techniques in its treatment. Reasons for failure of bony healing at the fracture site include the amount of initial fracture displacement, the poor condition surrounding the soft tissue envelope, and the micro-vascular compromise at the fracture site. The vascularity of the nonunion (i.e., hypertrophic or atrophic) is also a determining factor in bone healing because vascular or hypertrophic nonunion presented less of a treatment problem than atrophic nonunion. The common

goals of treatment are to achieve union, prevent axial or rotational mal-alignment, prevent variability in limb lengths, prevent and treat established infection, and finally allow functional restoration of the limb.

Hypertrophic nonunion of bone typically reflects inadequate immobilization and simply requires stable fixation because nonunion is well-vascularized. Provision of stable skeletal fixation without disruption of the blood supply typically resulted in union in these patients. Atrophic nonunion reflected inadequate or poorly vascularized nonunion with a very poor potential for bone forming cells. In such a condition it is necessary to resect nonviable bone, inflammatory tissue, fibrous tissue, or synovial tissue and the generated defects must be grafted by autogenous bone grafts to ensure sufficient mesenchymal cells, which also provide scaffolding, growth and differentiating factors to promote early healing, in addition to skeletal stabilization [1].

Intramedullary nailing is a weight-bearing system with many advantages that afford enough stability to allow unrestricted motion at three months postoperatively, despite that the fracture may need many more months to heal. This and the avoidance of a large local dissection are important in preventing residual foot and ankle stiffness. An uncomplicated closed nailing causes a minimal insult to the leg. Avoidance of a six month period of non-weight bearing as may be required in some other treatments, has definite benefit to the active patient. Reaming provides better purchase for the nail in both fragments, resulting in much more stable fixation than use of non-reamed nails. In the absence of infection, over-reaming with insertion of a larger diameter nail provides stability and local osteogenic material produced by reaming [26]. As supported by experimental studies, extensive reaming stimulated periosteal vascularity and new bone formation [17,27-29].

All patients, except one have achieved union

after a few months using reamed interlocking intramedullary nailing. Most of the patients underwent this procedure through a close fixation of the fracture site. The patients who needed autogenous bone grafting, underwent an open fixation and the mean of their union time was a month more than the closed group.

The union rate obtained in this study compares favorably with previous clinical studies reviewing reamed nailing for treating nonunion [30-33]. The union rate in our study was 97% and there was no additional open bone grafting or exchange reamed nailing after the operative treatment in our cases; while Templeman et al. [32], Mercado et al. [31], Court-Brown et al. [30], and Wu et al. [33] respectively reported a union rate of 93%, 97%, 100%, and 100% considering additional open bone grafting or exchange reamed nailing at a later stage respectively for 14%, 6%, 12%, 4% of their patients. The reoperation rate and the need for additional open bone grafting are important variables in the evaluation of nonunion procedures, because osseous union cannot be considered solely as a result of reamed nailing if additional open bone grafting is performed at a later stage. From this perspective, we feel that the results obtained in this study are favorable. In infected tibial nonunions, intramedullary nailing resulted in union rates of between 50 and 89% [34-37]. Because of adverse outcomes, previous investigators have cautioned against the use of intramedullary nailing in infected tibial nonunions [34,36]. Previous authors investigating the safety and efficacy of reamed nailing in the treatment of non-infected tibial nonunion have pointed out that this patient population is at risk for postoperative infections [30,32,33]. Templeman et al. even cautioned against the use of this procedure in the treatment of patients with non-infected tibial nonunion after a type IIIB open fractures because of the potential risk of infection [32]. Wu et al. pointed out that before exchange reamed tibial nailing, all patients should be carefully screened for normal wounds,

intermittent fever, and elevated erythrocyte sedimentation rates, to rule out silent deep infections of the nonunion site [33]. These reports emphasize the importance of a careful infection screening, to identify deep infections of the affected nonunion site. Therefore, we recommend that all patients who undergo reamed nailing in a tibial nonunion be screened routinely for infection using clinical, biochemical, and microbiologic markers. It is not feasible to compare the infection rate in our series with previous series that used less strict screening criteria. Although we had carried out this strict plan to identify a silent infection in tibial nonunion specially after a type IIIB open fracture, a severe infection due to reamed nailing in one patient with this type was occurred. Most of the patients were satisfied after the treatment, especially because they could start normal life and return to work soon after the surgery.

Management of tibial nonunion and delayed union is a controversial topic among orthopedic surgeons and many procedures have been recommended for the treatment. In our study, even in difficult cases, satisfactory union with restoration of function by using reamed interlocking intramedullary nailing as a treatment for tibial nonunion was achieved. We suggest that using reamed interlocking intramedullary nailing in the treatment of non-infected tibial nonunion is a safe procedure with low morbidity and a high union rate. However, infections of the affected lower extremity have to be ruled out preoperatively. Although prior type IIIB open fracture is not a contraindication for reamed interlocking intramedullary nailing, but it should be evaluated more aggressively for silent infections before using this technique. The advantageous biomechanical and physiologic effects of reamed nailing for treatment of nonunion ensure high union rates. Consequently, using reamed interlocking intramedullary nailing should be considered preferentially in the treatment of non-infected nonunion of the tibia.

References

1. Ring D, Barrick WT, Jupiter JB. Recalcitrant nonunion. *Clin Orthop* 1997;340:181–189.
2. Sarmiento A, Burkhalter WE, Latta LL. Functional bracing in the treatment of delayed union and nonunion of the tibia. *Int Orthop* 2003;27:26–29.
3. Bellabarba C, Ricci WM, Bolhofner BR. Results of indirect reduction and plating of femoral shaft nonunions after intramedullary nailing. *J Orthop Trauma* 2001;15:254–263.
4. Bungaro P, Pascarella R, Colozza A, Zinghi GF. Rigid fixation with plate and bone graft in failures of intramedullary osteosynthesis for the treatment of diaphyseal nonunion of the femur. *Chir Organi Mov* 1999;84:263–267.
5. Crosby LA, Norris BL, Dao KD, et al. Humeral shaft nonunions treated with fibular allograft and compression plating. *Am J Orthop* 2000;29:45–47.
6. Segmonds JM, Alnot JY, Masmajejan E. Aseptic nonunion of humeral shaft fractures treated by plating and bone grafting. *Rev Chir Orthop Repar Appar Mot* 2003;89:107–114.
7. Zelle B, Gruen GS, Klatt B, et al. Exchange reamed nailing for aseptic nonunion of the tibia. *J Trauma* 2004;57:1053–1059.
8. Finkemeier CG, Chapman MW. Treatment of femoral diaphyseal nonunions. *Clin Orthop* 2002;398:223–234.
9. Hak DJ, Lee SS, Goulet JA: Success of exchanged reamed intramedullary nailing for femoral shaft nonunion or delayed union. *J Orthop Trauma* 2000;14:178–182.
10. Ueng SW, Wei FC, Shih CH. Management of femoral diaphyseal infected nonunion with antibiotic beads local therapy, external skeletal fixation, and staged bone grafting. *J Trauma* 1999;46:97–103.
11. Bone LB, Kassman S, Stegeman P, France J. Prospective study of nonunion rate of open tibial fractures treated with locked, unreamed intramedullary nails. *J Orthop Trauma* 1994;8:45–49.
12. Gaebler C, Berger U, Schandelmaier P, et al. Rates and odds ratios for complications in closed and open tibial fractures treated with unreamed, small diameter tibial nails: a multicenter analysis of 467 cases. *J Orthop Trauma* 2001;15:415–423.
13. Wiss DA, Stetson WB. Unstable fractures of the tibia treated with a reamed intramedullary interlocking nail. *Clin Orthop* 1995;315:56–63.
14. Rubinstein RA, Green JM, Duwelius P. Intramedullary interlocked tibial nailing. *J Trauma* 1992;6:90–95.
15. Velazco A, Whitesides Jr TF, Flemming LL. Open fractures of the tibia treated with the Lottes Nail. *J Bone Joint Surg* 1983;65(A):879–885.
16. Whittle AP, Russell TA, Taylor JC, et al. Treatment of open fractures of the tibia with the use of interlocking nailing without reaming. *J Bone Joint Surg* 1992;74:1162–1171.
17. Reichert ILH, McCarthy ID, Hughes SPF. The acute vascular response to intramedullary nailing. *J Bone Joint Surg Br* 1995;77:490–493.
18. Bhandari M, Guyatt GH, Tong D, et al. Reamed versus nonreamed intramedullary nailing of lower extremity long bone fractures: a systematic overview and meta-analysis. *J Orthop Trauma* 2000;14(1):2–9.
19. De La Fuente SFJ, Arevalo LR, Carrillo TC, et al. Intramedullary nailing and functional bracing of tibial shaft fractures: 167 cases followed for minimum 2 years. *Acta Orthop Scand* 1998;69:493–497.
20. Lee YS, Lo TY, Huang HL. Intramedullary fixation of tibial shaft fractures: a comparison of the unlocked and interlocked nail. *Int Orthop* 2006;10(6):264–271.
21. Webb LR, Winkquist RA, Hansen ST. Intramedullary nailing and reaming for delayed union or nonunion of the femoral shaft. *Clin Orthop* 1986;212:131–143.
22. Duwelius PJ, Schmidt AH, Rubinstein RA, et al. Nonreamed interlocked intramedullary tibial nailing. *Clin Orthop* 1995;315:104–113.
23. Keating JF, O'Brien PJ, Blachut PA, et al. Locking intramedullary nailing with and without reaming for open fractures of the tibial shaft. *J Bone Joint Surg Am* 1997;79:334–341.
24. Merchant TC, Dietz FR. Long-term follow-up after fractures of the tibial and fibular shafts. *J Bone Joint Surg Am* 1989;71:599–606.
25. Trafton PG. Closed unstable fractures of the tibia. *Clin Orthop* 1988;230:58–67.
26. Babhulkar S, Pande K, Babhulkar S. Nonunion of the Diaphysis of Long Bones. *Clin Orthop Relat Res* 2005;431:50–56.
27. Danckwardt-Lilliestrom G. Reaming of the medullary cavity and its effects on diaphyseal bone: a fluorochromic, microangiographic and histologic study on the rabbit tibia and dog femur. *Acta Orthop Scand* 1969;128(suppl):1–153.
28. Rhinelander FW. Tibial blood supply in relation to fracture healing. *Clin Orthop* 1974;105:34–81.
29. Utvag SE, Grundnes O, Reikeras O. Graded exchange reaming and nailing of non-unions: strength and mineralization in rat femoral bone. *Arch Orthop Trauma Surg* 1998;118:1–6.
30. Court-Brown CM, Keating JF, Christie J, et al. Exchange intramedullary nailing. *J Bone Joint Surg Br*

1995;77:407–411.

31. Mercado EM, Lim EVA, Stern PJ, et al. Exchange nailing for failure of initially rodded tibial shaft fractures. *Orthopedics* 2001;24:757–762.

32. Templeman D, Thomas M, Varecka T, et al. Exchange reamed intramedullary nailing for delayed union and nonunion of the tibia. *Clin Orthop* 1995;315:169–175.

33. Wu CC, Shih CH, Chen WJ, et al. High success rate with exchange nailing to treat a tibial shaft aseptic nonunion. *J Orthop Trauma* 1999;13:33–38.

34. Klemm K. Treatment of infected pseudarthrosis of the femur and tibia with an interlocking nail. *Clin Orthop* 1986;212:174–181.

35. Lidgren L, Onnerfalt R. Infected non-union of the tibial shaft treated by Kuntscher intramedullary reaming and nail fixation. *Acta Orthop Scand* 1982;53:669–674.

36. Meyer S, Weiland AJ, Willenegger H. The treatment of infected non-union of fractures of long bones. *J Bone Joint Surg Am* 1975;57:836–842.

37. Miller M, Ada JR, Webb LX. Treatment of infected nonunion and delayed union of tibia fractures with locking intramedullary nails. *Clin Orthop* 1989; 245: 233–238.