

## The LMA CTrach, a new approach for endotracheal intubation: a pilot study in 100 patients undergoing elective surgery

Valiollah Hassani<sup>1</sup>, Maryam Zafarghandi<sup>2</sup>, Mohammad Farhadi<sup>3</sup>

*Department of Anesthesiology, Hazrat Rasoul Hospital, Iran University of Medical Sciences, Tehran, Iran*

Received: 28 December 2009

Revised: 22 April 2010

Accepted: 29 April 2010

### Abstract

**Background:** The LMA CTrach system is a new device for airway management and endotracheal intubation under direct vision in both anticipated and unexpected difficult intubation situations.

**Methods:** We used this system in 100 patients undergoing general anesthesia for different types of elective surgeries. After randomly selecting the patients for intubation with this new device, the airway characteristics, height, weight, dental overbite and thyromental distance were all evaluated before induction. Our goal was to explore primarily the success rate of intubation with LMA CTrach.

**Results:** We were able to insert LMA CTrach and provide optimal ventilation in all 100 patients. Nonetheless, successful tracheal intubation was performed in 95 patients. Among our patients, 2 had Mallampati grade IV airways with short necks, body mass index (BMI) > 30, and without the capability to bite their upper lips. Amazingly both patients were intubated with this method, proving a device as an assuring approach in cases of difficulty with ventilation and intubation. Of all patients, 44 were females and 56 males. The mean age was  $34 \pm 2$  years. BMI measured for all patients was 20-25 except for two cases who had BMI > 30.

**Conclusion:** Since the LMA CTrach provided us with direct view of the larynx and vocal cords during intubation even in difficult cases, it can be assumed that this device is a precious aid as equal as fiberoptic bronchoscopy for the anesthesiologists.

**Keywords:** LMA CTrach, intubation, airway characteristics, Mallampati grade

### Introduction

Technical problems with tracheal intubation have been the most frequent causes of anesthetic death in the published analyses from all over the world [1, 2].

Most cases of unanticipated difficult intubation are managed satisfactorily, but associated problems with tracheal intubation can cause se-

rious soft tissue damage [3] and are the principle cause of hypoxemic anesthetic death and brain damage [1,2,4]. Management of these cases must therefore be focused on maintenance of oxygenation and prevention of airway trauma.

Among the devices used for airway management, difficult intubation using direct laryngoscopy may occur ubiquitously across the

1. Professor of Anesthesiology, Department of Anesthesiology, Hazrat Rasoul Hospital, Iran University of Medical Sciences, Tehran, Iran. Email: vhassani@yahoo.com

2. **Corresponding author**, Resident of Anesthesiology, Hazrat Rasoul Hospital, Iran University of Medical Sciences, Tehran, Iran, Address: Department of Anesthesiology, 4th floor, Hazrat-e-Rasoul Hospital, Nyiayesh St., Sattarkhan St., Tehran, Iran. Tel: +9821-22050406, email: leoanesthesia@yahoo.com

3. Professor of Otolaryngology, Department and Research Center of ENT and Head & Neck Surgery, Hazrat Rasoul Hospital, Iran University of Medical Sciences, Tehran, Iran. Email: farhadi28@gmail.com

Table 1. The 6-D method of airway assessment

Sign of difficulty	Description	Quantitative or qualitative findings	Acceptable findings not associated with difficulty
1. Disproportion	-increased size of tongue in relation to pharyngeal size	-Mallampati class III or IV	-Mallampati class I or II
2. Distortion	-airway swelling -airway trauma -neck mass -neck abscess or hematoma -arthritic changes in the neck joints -previous surgical airway	-possibly difficult to assess -blunt or penetrating -voice changes -crepitus or laryngeal immobility -non-palpable thyroid cartilage -nonpalpable cricoids cartilage	-midline trachea -no contractures of the neck No surgical airway scar -mobile laryngeal anatomy -easily palpated thyroid and cricoids cartilage
3. Decreased thyromental distance	-Anterior larynx and decreased mandibular space	-Thyromental distance < 7 cm ( < 3 finger breadths) measured from the superior aspect of the thyroid cartilage to the tip of the chin -Receding chin	-Thyromental distance > 7cm (3 finger breadths)  -No receding chin
4. Decreased interincisor gap	-Reduced mouth opening	-Distance between upper and lower incisors < 4 cm (2 finger breadths) -Mandibular condyle fracture -Rigid cervical spine collar	-Interincisor gap > 4 cm
5. Decreased motion in joints of the airway	-Limited head extension secondary to arthritis, diabetes, or other diseases -Previous neck irradiation or surgery -Neck contractures secondary to burns or trauma	-Head extension < 35° - Neck flexion < 35° - Short, thick neck -Cervical spine collar or cervical spine immobilization	-Head extension > 35° -Neck flexion > 35° _long, thin neck - No collar nor cervical immobilization
6. Dental overbite	-Large angled teeth disrupting the airway alignment	- Dental overbite	-No dental overbite

spectrum of health care [5] and is reported to occur with an incidence of approximately 6% in anesthesiology [6]; and thus, most tracheal intubations can be performed using direct laryngoscopy.

Owing to the difficulty in intubation with a laryngoscope, a number of devices have been developed for orotracheal intubation in the operating theater, at the bedside and also outside the hospital, such as the fiberscope, intubating laryngeal mask airway, lighted stylet, stylet

scope, and video-laryngoscope [7].

The LMA CTrach system is also a new system for airway management. Based on the intubating LMA, this new device comprises an LMA CTrach airway and a detachable liquid crystal display viewer. The system enables viewing the larynx and the process of endotracheal intubation through the laryngeal mask airway. The LMA CTrach system is indicated as a device for achieving and maintaining an airway in both anticipated and unexpected diffi-

Risk factor for difficult intubation(DI)	Number
Previous knowledge of DI	0
Clinical symptoms of airway pathology or sleep apnea	2
Inter-incisor gap < 4 cm	2
BMI > 30	2
Short thick neck	7
Thyromental distance< 7 cm	2
Head and neck movement < 35 degrees	5
Mallampati score III or IV	2
Inability to perform Dental overbiting	2
Receding chin	5

Table 2. Airway characteristics of the 100 patients treated with CTrach

cult intubation situations.

As a rule and in order to prevent any mismanagement, preanesthetic assessment of the airway is recommended in all patients. The Mallampati classification system was implemented as a method to predict difficult intubation. However, its reliability as a predictor of difficult intubation has been questioned [8], and it assesses only one aspect of the airway for difficulty (i.e., intraoral disproportion) [9](See also Fig. 1).

A comprehensive airway examination incorporates both quantitative and qualitative tests that together may increase the probability of predicting difficult intubation [10]. One such system, the "6-D" method, examines the airway for six separate signs, described in Table 1.

In this study we have also examined the Mallampati score, interincissor gap, thyromental distance, dental overbiting and also neck distortion and its range of motion. It is well known that morbid obesity can compromise the airway especially if the patients had symptoms of obstructive sleep apnea (OSA), the height and weight of the patients were also measured.

## Methods

The LMA CTrach device has two built-in fi-

breoptic channels, one to convey light from and the other to convey the image to the viewer. This fiberoptic system is sealed and robust, and the CTrach can be autoclaved. The CTrach has an epiglottis elevating bar, which elevates the epiglottis during passage of the endotracheal tube (ETT) through the CTrach into the larynx. This bar has an aperture through which the anatomy anterior to the bar is viewed. The CTrach's shape is based on magnetic resonance imaging of the human airway, that enable a close fit with the oropharyngeal curve and optimal alignment with the laryngeal inlet.

The magnetic latch connection at the top of the CTrach connects the detachable LMA CTrach viewer securely to the CTrach airway, ensuring correct alignment of the fiberoptic channels to the viewer. The viewer has a high resolution LCD color display. It provides the light source, and the keys for adjusting the image gain, brightness and color. It has a thumb-wheel for adjusting the focus and rechargeable battery for up to 30 minutes of continuous use. Also a charger cradle for recharging the viewer is included in the system.

*Patients:* After taking an informed consent from all patients for running this study, we ran-

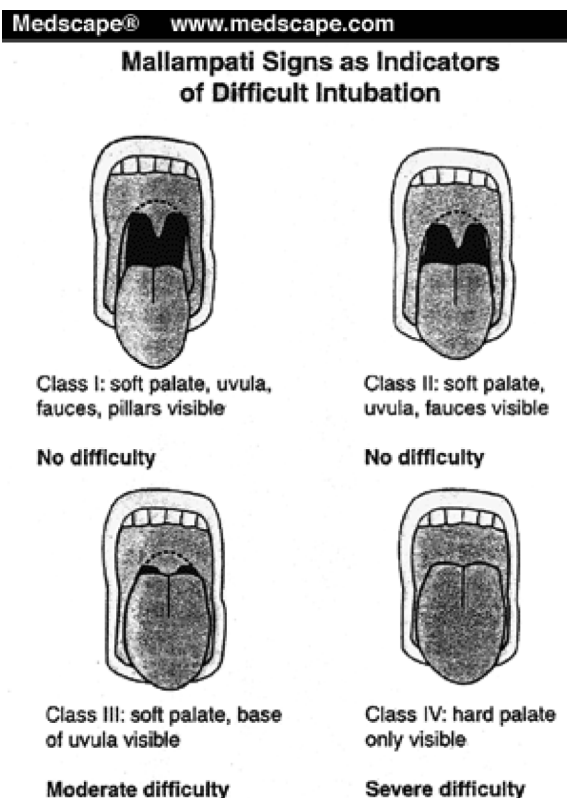


Fig. 1. Mallampati scoring for demonstrating oropharyngeal disproportion

domly recruited 100 patients with a mean age of  $34 \pm 2$  years old. 44 of them were females and 56 males. They all required general anesthesia with endotracheal intubation for elective surgery. Patients who were pregnant, non-fasted, morbidly obese ( $\text{BMI} > 40$ ), had gastroesophageal reflux, delayed gastric emptying or severe respiratory disease, were all excluded. Before starting anesthesia, we measured their height and weight for calculating BMI. They all had BMI between 20-25 but 2 patients had BMI  $> 30$ , and also Mallampati score IV in their physical examination.

The rest of our patients had Mallampati scores between I and III. Meanwhile, the thyromental distance, interincisor gap, dental overbiting, shape of the neck and its height were assessed, in physical examination.

They were also asked about clinical symptoms for airway problems, such as dyspnea re-

lated to compression of the airway, dysphonia, dysphagia and sleep apnea syndrome. This syndrome was suspected either in the case of snoring associated with two other major symptoms among sudden arousal with choking, excessive day-time sleepiness or unrefreshing sleep (Table 2).

**Preparation:** The CTrach size was selected according to the patient's weight, following the manufacturer's recommendations. We used cuffed, wire-reinforced silicone ETTs with inner diameter of 7 mm for CTrach size 3 and for patients with body weight  $< 50$  kg. Also, a size of 4 CTrach and 7.5 mm ETT were used for patients with 50-70 kg, and a size of 5 CTrach and 8 mm ETT for patients  $> 70$  kg. Before insertion of the CTrach, the viewer was attached and focused by obtaining a sharp image of a sheet of text held 1 cm in front of the fiberoptic.

**Anesthesia:** After preoxygenation, and premedication (Midazolam 0.05 mg/kg and Fentanyl 3-5 µg/kg) to patients, we induced general anesthesia with propofol 2 mg/kg and atracurium 0.5 mg/kg. Afterwards maintenance of anesthesia was held with propofol infusion (50-150 µg/kg) and 70% N<sub>2</sub>O in oxygen adjusted according to each patient's hemodynamic indices. Obviously, we tested adequate mask ventilation before inducing muscle relaxation. After inserting the CTrach into the oral cavity with minimal neck movement, the cuff was inflated and then ventilation was checked. If necessary, minimal manipulation was performed to obtain optimal ventilation with the least leak. Then the viewer was attached to see the larynx while ventilation was maintained throughout this time. After catching the best view, we passed the ETT through the CTrach into the trachea under vision and confirmation was performed with bilateral auscultation and capnography. Then the CTrach was removed after cuff deflation, removing the ETT connector, and with the aid of a stabilizer rod. We permitted a minimum of three attempts at oral insertion of the CTrach to achieve adequate ventilation and three attempts for intubation, either with the viewer or blindly. Otherwise, intubation was carried out using a laryngoscope or fiberoptic device.

**Data and analysis:** Our primary goal was to assess the rate of success for intubation and ventilation with this system. However, in the meanwhile height, weight, BMI, and the indices of airway evaluation were also measured, as mentioned.

## Results

Our patients had a mean age of  $34 \pm 2$  years (20-60 yrs) with a mean BMI of less than 25 (24.5). 56 of them were men and 44 women. We had only 2 patients with BMI of 30, and 32 who had also Mallampati score 4 in physical examination. The details of their airway evaluation is

demonstrated in Table 2.

The CTrach insertion into the oral cavity was successful at the first attempt in all 100 patients and we were able to ventilate all the patients including the obese ones. In 15 cases, we could not obtain a good view of the larynx despite manipulation, using Chandy maneuver (with lifting the epiglottis and playing with the device in different directions). A suction catheter was inserted through the CTrach; therefore blind intubations were tried which proved successful in 10 cases. Finally we were successful in intubating the trachea in 95 patients using the CTrach device. Also it is noteworthy to mention that intubation with the CTrach guidance was successful in those two cases with Mallampati score 4, obese, and unable to bite their upper lips. The remaining patients, in whom intubation with the CTrach was not achievable, had limited head and neck movement and receding chin, so that even with manipulation no optimal view of the larynx was obtained. Although, their ventilation was adequate for maintaining the oxygen saturation with high flow rates ( $\approx 10$  lit/min), we tried simple laryngoscopy with a Mackintosh blade for their intubation which was fortunately successful.

## Discussion

This investigation had a high success rate in ventilation and intubation of the patients with the aid of CTrach LMA. In the meanwhile, however we had difficulty in viewing the larynx in 5 patients in spite of their acceptable Mallampati scores and maximum manipulation of the device in every direction. Nonetheless, some of these patients had receding chin or were unable to fully rotate or flex their necks. Altogether, one can conclude that there is maybe a variable quality in viewing the larynx and the ability to intubate the patients with this new device.

In another study, held in Singapore 2006, a similar problem was encountered despite their high success rate of intubation (98.8%) [11]. In

their study also, there was no correlation between direct laryngoscopy grading and success of intubation as the failed cases were all successfully intubated with a Macintosh laryngoscope. In other study held in department of anesthesiology, Texas, USA [12], successful intubation was demonstrated via the CTrach LMA in four anticipated difficult to intubate cases under sedation and topical anesthesia. This investigation which was performed in Baylor university 2005, also showed the amazing capacity of this device in intubating the patients, in the awake state. There are also other studies all around the world using CTrach LMA as their device of choice for intubation [13,14, 15]. The device has advantages similar to the Fastrach when compared with a Macintosh laryngoscope. The CTrach enables nearly continuous ventilation and oxygenation of the patient during the intubation process [16]. Moreover, it does neither need extreme flexion nor extension of the head and neck in order to obtain an optimal view of the airway. This is in contrast to the conventional intubation, which requires alignment of the oral pharyngeal and laryngeal axes, not always possible. CTrach has another advantage even superior to the Fastrach- LMA or ILMA, and that is its capability to view the larynx while manipulating the device to achieve the best condition for intubation. This suggests that it may be worth trying CTrach instead of blind attempts for intubation which could traumatize the airway and distort its anatomy. Another positive point is its application for teaching the airway anatomy and the right way of intubation, which was also extremely helpful in our investigation and most of the junior residents became familiar with this method and could have a three-dimensional view of the path to the trachea.

Like any other new devices, further investigation is required in order to explore maximum capability, we think it maybe too soon have certain suggestions or theories about CTrach. It can be concluded that sometimes, the anes-

siologist would encounter unpredictable problems with this device in patients not suspected to have difficult airways and the ones who would be easily intubated, thereafter with a Macintosh or Miller laryngoscope. The reason was not clear for us and we hope our colleagues and us together will be able to clarify also this small problem with CTrach LMA in the future. In the meanwhile, however there have been suggestions by other investigators such as what pointed by the anesthesiologists again in Singapore [15]. They have claimed downfolding of the epiglottis as the most common cause of initial poor views with LMA CTrach. In their study, it was possible to ventilate the lungs in all patients despite these poor views and the presence of epiglottic downfolding.

In the majority of patients with poor initial views, full views of the glottis could be obtained after applying simple measures in the first attempt success rate of tracheal intubation was very high if the glottis could be seen, suggesting that it is worth the time and effort to achieve a full view when using the CTrach. Conversely, where failed views as a result of epiglottic obstruction were not corrected, 'blind' intubation had a low probability of success. In conclusion, they found high success rates of insertion, ventilation and tracheal intubation with the CTrach. However, they obtained a full view of the glottis in only 31% of patients immediately after insertion of the CTrach and attachment of the viewer. Although they could correct poor views with simple measures in most patients, they failed to correct epiglottic downfolding and failed in tracheal intubation in a small number of patients [15].

Perhaps some experts become doubtful about our study, asking why we tried CTrach after induction for general anesthesia even in patients who had high Malampatti scores or who proved to be difficult cases for intubation after airway examination. Indeed, this is optional in each department which way they prefer to choose for intubation of their difficult cas-

es, however in order to provide the patients' safety we also had fiberoptic laryngoscope, bougie, and even apparatus for jet ventilation already accessible. It would be nice also to mention another study which clarified this subject. A study held in France in 2008 had encountered a problem with a morbidly obese patient undergone intubation via CTrach, who had experienced pulmonary aspiration. In their discussion, and despite this problem, they say: "We might have proposed to perform an awake intubation procedure in this morbidly obese patient because preoperative airway evaluation anticipated both difficult ventilation and intubation scenarios. Indeed, the American Society of Anesthesiology recommends awake intubation if both difficult mask ventilation and difficult intubation are anticipated. However, over the past 3 yr, only one morbidly obese female received an elective fibreoptic tracheal intubation because of a 2 cm mouth aperture. Among the 317 morbidly obese patients who received general anaesthesia, 19 who could not be intubated via the tracheal conventionally were correctly ventilated and then intubated with the intubating laryngeal mask airways (LMAFastrach TM or CTrach TM). Because of the beneficial performance of the intubating laryngeal masks in this particular population of patients, we quite systematically managed the airways of our morbidly obese patients after general anaesthesia induction. Moreover, it was not certain that awake fibreoptic tracheal intubation which requires either intense pharyngeal, laryngeal, and proximal trachea sensory block or sedation (and sometimes both) would have prevented the pulmonary aspiration of regurgitated gastric content" [14].

### Conclusion

In this study, we were successfully able to intubate patients who had high Mallampati scores and obese, with short necks and unable to bite their upper lips. This was unbelievable even for ourselves; however patients who were conven-

tionally intubated while we could not achieve this goal with the CTrach LMA again unbelievably.

Finally, it should be emphasized that LMA CTrach could have an important role in difficult airway management by facilitating ventilation and enabling us to view the larynx before intubation despite problems regarding the quality of laryngeal views. Hence further investigation is required by the anesthesiologists and also the manufacturer's company.

### References

1. Utting JE. Pitfalls in anesthetic practice. *Anaesthesia* 1987; 59: 877-90.
2. Gannon K. Mortality associated with anesthesia. A case review study. *Anaesthesia* 1991; 46: 962-6.
3. Domino KB, Posner KL, Caplan RA, Cheney FW. Airway injury during anesthesia : a closed claim analysis. *Anesthesiology* 1999; 91: 1703-11.
4. Benumof JL, Scheller MS. The importance of transtracheal jet ventilation in the management of the difficult airway. *Anesthesiology* 1998; 71: 769-78.
5. Rich JM. Street Level Airway Management (SLAM): if your patient can't breathe- nothing else matters. *Anesthesia Today* 2005; 16: 13-22. Available From: [www.airwayeducation.com](http://www.airwayeducation.com).
6. Rich JM, Mason AM, Bey TA, Kraft P, Frass M. The critical airway, rescue ventilation, and the Combitube: part 1. *AANA* 2004; 72: 17-27.
7. Rai MR, Dering A, Verghese C. The Glidescope system: a clinical assessment of performance. *Anaesthesia* 2005; 60: 60-64.
8. Karkouti K, Rose DK, Ferris LE, Wigglesworth DF, Meisami-Fard T, Lee H. Inter-observer Reliability of ten tests used for predicting difficult tracheal intubation. *Can J Anesth* 1996; 43: 554-559.
9. Mallampati SR, Gatt SP, Guigno LD. A clinical sign to predict difficult tracheal intubation: a prospective study. *Can J Anesth*. 1985; 32: 429-434.
10. Wilson W. Difficult intubation. In Atlee J, ed. *Complications in ANESTHESIA*. Philadelphia: WB Saunders 1999; 4: 138-147.
11. Lieu EHC, Goy RWL, Chen FG. The LMA CTrach

ch, a new laryngeal mask airway for endotracheal intubation under vision. *British J of Anesthesia* 2006; 96 (3): 396-400.

12. Rich JM. Recognition and management of the difficult airway with special emphasis on the intubating LMA-Fastrach/ whistle technique. *BUMC Proceedings* 2005; 18: 220-227.

13. Ojeda A, , Lopez AM, Borrat X, Valero R. Failed Tracheal Intubation with the LMA-CTrach™ in Two Patients with Lingual Tonsil Hyperplasia: *Anesth Analg* 2008;107: 601-2 .

14. Abdi W, Ndoko S, Amathieu R, Dhonneur G. Evidence of pulmonary aspiration during difficult airway management of a morbidly obese patient with the LMA Ctrach: *BJA* 2008; 100 (2): 275-7.

15. Liu EHC, Goy RWL, Chen FD. An evaluation of poor LMA CTrach™ views with a fiberoptic laryngoscope and the effectiveness of corrective measures. *BJA* 2006; 97(6): 878-82.

16. Langeron O, Semjen F, Bourgain JL, Marsac A, Cros AM. Comparison of the intubating laryngeal mask airway with the fiberoptic intubation in anticipated difficult airway management. *Anesthesiology* 2001; 94: 968-72.