

Gastritis cystica polyposa in an unoperated stomach, treated by endoscopic polypectomy

Mahsa Molaei¹, Mahdi Yadollahzadeh², Reza Mashayekhi³
Mojgan Foroutan⁴, Mohammad-Reza Zali⁵

Research Center for Gastroenterology and Liver Disease in Shahid Beheshti University M.C., Tehran, Iran.

Received: 26 July 2009

Revised: 13 July 2010

Accepted: 20 July 2010

Absract

Gastritis cystic polyposa is a rare and peculiar polypoid lesion arising at a gastroenterostomy site, and almost always on the gastric side. It is characterized by elongation of the gastric foveolae along with hyperplasia and cystic dilatation of the gastric glands extending into the submucosal layer. Esophagogastroduodenoscopy in a 47-year-old woman without any history of gastric operation revealed a pedunculated polyp approximately 2 cm in diameter, in a background of erythematous gastric folds along the anterior wall of the fundus. Polypectomy was performed, with endoscopic impression of hyperplastic or fundic gland polyp, without any complications. Histopathological findings were consistent within gastritis cystic polyposa (GCP). A mild *Helicobacter pylori* colonization in gastric pits was seen. GCP could occur in an unoperated stomach and treated by endoscopic polypectomy. However, removal and histopathologic confirmation of these lesions are necessary.

Keywords: gastric polyp, gastritis cystica polyposa, endoscopic polypectomy, *H. pylori*

Introduction

Gastritis cystic polyposa/profunda (GCP) is defined as a hyperplastic polyp that contains foci of misplaced foveolar and/or glandular epithelium in the muscularis mucosae or in the deeper portions of the submucosa or the muscularis propria [1-6]. The lesion called polyposa when an intraluminal polyp is present [1,2] and profunda when the cystic lesion located within the submucosa [3] and the bulk of the lesion is located within the wall of the stomach [1,2].

The GCP is an uncommon lesion that develops in patients who have undergone gastroenterostomy with or without gastric resection [3-6] especially for treatment of a benign lesion, e. g., gastric ulcer [4,5]. GCP may rarely found in an unoperated stomach [3-8].

GCP was also described as polypoid tumors developed in the gastric mucosa adjacent to Billroth-II stoma at first time [3]. These lesion typically occur in patients with chronic bile reflux-induced gastritis as a result of partial gastrectomy [1,2]. Nonetheless, GCP could be re-

1. **Corresponding author.** Assistant Professor of Pathology, Shahid Beheshti University, M.C. Research Center for Gastroenterology and Liver Disease (RCGLD) in Shahid Beheshti University M.C., 7th floor, Taleghani Hospital, Evin, Tehran, Iran. P.O.Box 19835-187, Tel.: +9821 22432515, Fax: +9821 22432517, Email: m_molaei@sbmu.ac.ir

2. Resident of Internal Medicine, Shahid Beheshti University, M.C. Email: m_yad@yahoo.com

3. Assistant Professor of Pathology, Shahid Beheshti University, M.C. Email: reza mashayekhi@yahoo.com

4. Assistant Professor of Gastroenterology, Shahid Beheshti University, M.C. Email: mfrootan2003@yahoo.com

5. Professor of Gastroenterology, Shahid Beheshti University, M.C. Email: nnzali@hotmail.com

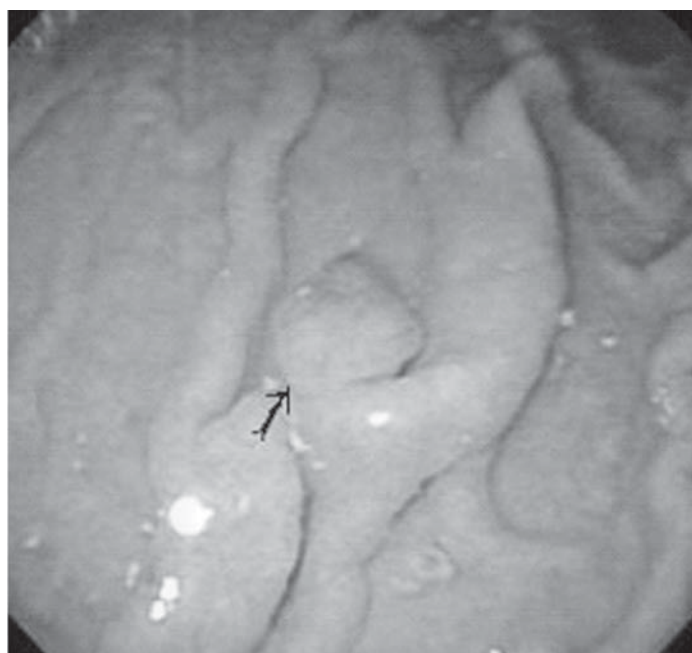


Fig. 1. Endoscopic view of a pedunculated polyp in anterior wall of the fundus.

ferred to a stromal polypoid hypertrophic gastritis when it occurs in the postoperative gastric remnant [1]. Endoscopically and radiologically GCP appears such as a polypoid mass that is almost always on the gastric side of the anastomosis. Because it is difficult to differentiate GCP from cancer by radiologically and endoscopically, surgery might be required in most cases for diagnosis [5].

There have been few case reports of GCP in

unoperated stomach. Herein, we report a case of GCP with slight sign and symptoms that occurred in a patient with an unoperated stomach, and was treated successfully by endoscopic polypectomy.

Case report

A 47-year-old woman was referred to the Gastroenterology department of Taleghani hospital for further evaluation and treatment of

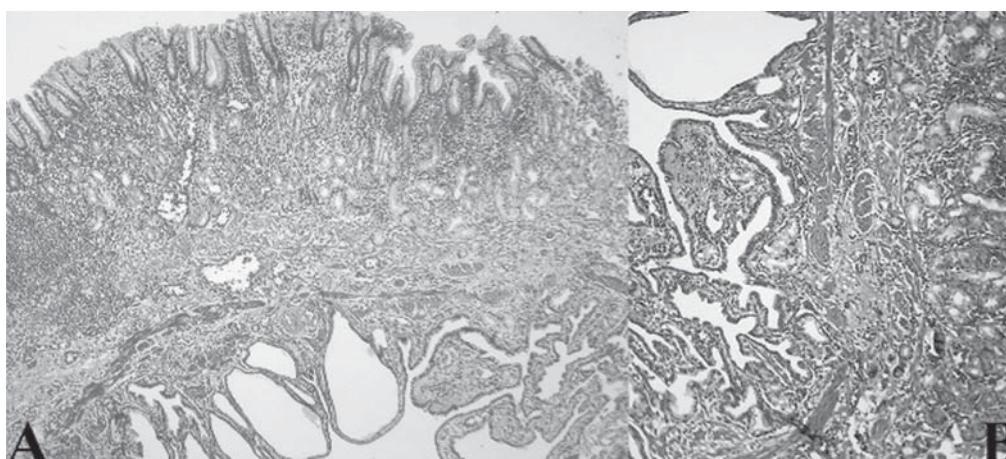


Fig. 2. A: Microscopic photography of polyp showed some cystic glands and entrapped epithelium within and beneath the muscularis mucosa in depth of the polyp (H&E, Mag. 100).

B: The misplaced glands covered by flat and glandular epithelium and surrounded by a rim of lamina propria . (H&E, Mag. 400).

a polypoid mass found in her esophagogastroduodenoscopy (EGD). She had chief complaint of dyspepsia and intermittent epigastric pain since six month ago. The patient did not express any history of gastric operation, and have had an EGD.

Another hospital one month before admission. It revealed a polypoid mass in the fundus but biopsy was not obtained and patient referred to our hospital for polypectomy.

Routine physical examination was normal e.g. BP = 130/80, PR = 80, and abdomen was soft with no mass or organomegaly. Laboratory tests including CBC, liver and thyroid function tests as well as serum electrolytes were within the normal range, The abdominopelvic ultrasonography was normal, and total colonoscopy was performed to obtain biopsies. The histologic examination of tissues were unremarkable.

The EGD at our hospital was done and revealed a pedunculated polyp approximately 2 cm in diameter, in a background of mild erythematous gastric folds along the anterior wall of the fundus (Fig. 1).

Polypectomy was performed without any complications. The resected specimen measured $2 \times 1.5 \times 1$ cm and its cut surface revealed small mucin-filled cysts with a background of pinkish stroma. On microscopic examination surface of polyp showed fundic type mucosa with congestion and moderate chronic inflammation without intestinal metaplasia or dysplasia. Mild *Helicobacter pylori* colonization in gastric pits was seen. Some cystic glands and entrapped epithelium within and beneath the muscularis mucosa was noted in depth of polyp. These misplaced glands was covered with flat and glandular epithelium surrounded by a rim of lamina propria (figure 2). These findings were consistent with gastritis cystica polyposa. After 6 month follow up she was well without any symptoms and her subsequent EGD was normal.

Discussion

The GCP is a rare and unusual polypoid lesion arising at a gastroenterostomy site. It is characterized by elongation of the gastric foveolae along with hyperplasia and cystic dilatation of the gastric glands extending into the submucosal layer [5]. Since 1972 when this entity was first described by Littler and Gleibermann several synonyms have been used, including multiple polypoid cystic gastritis, gastric cystic polyposis, stomal polypoid hypertrophic gastritis, hyperplastic polyps of the gastric mucosa adjacent to gastroenterostomy stomas, and gastritis cystica profunda [2,5]. These lesion usually occurs on the gastric side of the anastomosis [2,5], most probably because mucosal mobility increased by peristaltic contractions and damage repairing at preanastomotic gastric mucosa that caused by small intestinal contents reflux [3,5]. Ischaemia and chronic inflammation as such as the effects of surgery and suture material presence have a role in the pathogenesis of gastritis cystica profunda. In one report, a correlation found between gastritis cystica profunda and gastric ulcer [2]. However, as our case demonstrates, these lesions can also develop in the unoperated stomach [5]. The mechanism of GCP developing in the unoperated stomach is unclear yet [3], but has generally been assumed to be of congenital origin, mainly because of the lack of documented prior gastric ulceration or trauma [2,5].

Histologically, GCP major findings are elongation of the gastric pits, submucosal invasion by the hyperplastic process, and cystic dilatation of the pseudopyloric glands. Because the marked hyperplasia, foveolae are elongated, and The surface and foveolae are lined by cuboidal or short columnar, immature epithelial cells [2].

Commonly, the clinical manifestations of GCP include symptoms of gastric obstruction, abdominal pain, or bloating [5,9]. Superficial ulceration and bleeding may also result in com-

plications [5,6]. The intermittent epigastric pain in our patient (the same as two others[5,7]) might have been caused by the GCP because it resolved after polypectomy. The site of lesion in our patient was along the anterior wall of the fundus and similar to two other reports [5,7]. In some cases, it was suggested that GCP at a gastroenterostomy site could be a precancerous lesion because carcinoma is frequently found at old gastrojejunostomy stoma and the histologic features of GCP are similar to the experimental stomal polyps preceding carcinoma after partial gastrectomy in rats.[2,3,5,9] *Helicobacter pylori* was present only in our case and one of reported before [6]. One of the alarming problem that could derived from gastritis cystic polyposa is stomach cancer [5], due to mucosal high malignant potential in the remnant stomach [9], Furthermore, GCP together with Epstein-Barr virus (EBV) infection may have been facilitated the development of remnant carcinoma at the anastomotic site [10]. Therefore, removal and histopathologic confirmation of these lesions may be necessary when GCP is suspected at the anastomosis after gastroenterostomy. In our case, EGD, Ultrasonography, and colonoscopy findings suggested that the lesion was more likely to be benign than malignant.

The EGD showed a pedunculated polyp, resembling hyperplastic or fundic gland polyp clinically, hence the gastroenterologist did not performed other diagnostic examinations such as CT scan or endoscopic ultrasonography and because the lesion had a small stalk, the patient was a good candidate for endoscopic polypectomy. There were no complications during or after polypectomy. To our knowledge, this is one of rarely founded GCP in an unoperated stomach which was successfully treated by endoscopic polypectomy [5].

In conclusion, GCP could occur in an unoperated stomach, and could be treated by endoscopic polypectomy.[8] however removal and histopathologic confirmation of these lesions is necessary [5].

Acknowledgments

The authors would like to thank Research Center of Gastroenterology and Liver Disease.

References

1. Odze RD, Cranford JM, Goldblum JR. Surgical pathology of the GI Tract, liver, Biliary Tract, and Pancreas. Philadelphia: Saunders, 2004; 24: 273-274.
2. Franzin G, Novelli P. Gastritis cystica profunda. *Histopathology* 1981; 5(5): 535-47.
3. Park CH, Park JM, Jung CK, Kim DB, Kang SH, Lee SW, et al. Early gastric cancer associated with gastritis cystica polyposa in the unoperated stomach treated by endoscopic submucosal dissection. *Gastrointest Endosc* 2009; 23: [Epub ahead of print].
4. Hirasaki S, Tanimizu M, Tsubouchi E, Nasu J, Masumoto T. Gastritis cystica polyposa concomitant with gastric inflammatory fibroid polyp occurring in an unoperated stomach. *Intern Med* 2005; 44(1): 46-9.
5. Park JS, Myung SJ, Jung HY, Yang SK, Hong WS, Kim JH, et al. Endoscopic treatment of gastritis cystica polyposa found in an unoperated stomach. *Gastrointest Endosc* 2001; 54(1): 101-3.
6. Emna EJ, Haifa TG, Moussaddak A, Majda E, Ammar C, Samir B. [Gastritis cystica polyposa: report of 7 cases and literature review] [Article in French] *Tunis Med* 2005; 83(9): 562-7.
7. Béchade D, Desramé J, Algayres JP. Gastritis cystica profunda in an unoperated stomach 1: endoscopy 2007;39(Suppl 1): 80-1.
8. Tuncer K, Alkanat M, Musoglu A, Aydin A. Gastritis cystica polyposa found in an unoperated stomach: an unusual case treated by endoscopic polypectomy. *Endoscopy* 2003; 35(10): 882-7.
9. Qizilbash AH. Gastritis cystica and carcinoma arising in old gastrojejunostomy stoma, *Can Med Assoc J* 1975; 112: 1432-3.
10. Kaizaki Y, Hosokawa O, Sakurai S, Fukayama M. Epstein-Barr virus-associated gastric carcinoma in the remnant stomach: de novo and metachronous gastric remnant carcinoma. *J Gastroenterol* 2005; 40(6): 570-7.