

Meningeal melanomas associated with transforming Ota nevus to malignant melanoma: a case report

Maziar Azar¹, Farid Kazemi², Eshagh Bahrami³, Ebrahim Hejazian⁴, Seyed-Mohammad Fereshtehnejad⁵, Ali Ahmadi⁶, Masih Yasari⁷

Department of Neurosurgery, Iran University of Medical Sciences and Health Services, Tehran, Iran.

Received: 7 April 2010

Revised: 17 July 2010

Accepted: 25 July 2010

Abstract

Intracranial invasion of cellular blue nevus (CBN) from the skin is extremely rare and such a condition with malignant transformation is even rarer. A case of meningeal melanoma with malignant transformation which was derived from an Ota nevus is presented in this report.

A 21-year-old man with a neurocutaneous syndrome since childhood was referred with headache and mild left hemiparesia. CT scan and MRI demonstrated intracranial lesions and conjunctival biopsy leads to the pathologic diagnosis of blue nevus. Thereafter his parietal lesion was operated by craniotomy with total gross excision. On histopathological examination, diagnosis of malignant melanoma was confirmed. Approximately 2 months after radiotherapy and chemotherapy, he afflicted to diplopia and blurred vision on the leftside due to enlargement of orbital and cavernous sinus lesion. Following one year follow-up, he was survived and thrived with diffuse leptomeningeal nodular enhancement in favor of melanoma dissemination. Primary intracranial melanomas are though rare, but it should be suspected especially in the presence of periorbital blue nevus or nevus of Ota. Moreover, although CBN is considered benign, scalp or periorbital CBN has the potential for intracranial invasion and malignant transformation.

Keywords: Meningeal melanomas, Ota nevus, malignancy

Introduction

Solitary primary melanocytic tumors of the central nervous system (CNS) are consisted of a variety of lesions ranging from well-differentiated melanocytoma to melanoma. These primary intracranial melanomas are rare tumors derived from the melanocytic element normally

present in the leptomeninges [1]. These tumors may sometimes be associated with cutaneous pigmented lesions including neurocutaneous melanosis, cellular blue naevus, and the naevus of Ota [2]. All three of these conditions are usually diagnosed at birth or shortly thereafter, and the cutaneous involvement appears as a gray-blue discoloration with almost unknown patho-

1. Associate Professor of Neurosurgery, Department of Neurosurgery, Iran University of Medical Sciences and Health Services, Tehran, Iran. Email: maziarazar@yahoo.com.

2. Associate Professor of Neurosurgery, Department of Neurosurgery, Iran University of Medical Sciences and Health Services, Tehran, Iran. Email: faridkazemi_2006@yahoo.com.

3. Associate Professor of Neurosurgery, Department of Neurosurgery, Iran University of Medical Sciences and Health Services, Tehran, Iran. Email: bahrami_eses@yahoo.com.

4. **Corresponding author**, Resident of Neurosurgery, Department of Neurosurgery, Iran University of Medical Sciences and Health Services (IUMS), Tehran, Iran. Address: Rasool-e-Akram Hospital, Department of Neurosurgery, Iran University of Medical Science, Tehran, Iran. Email: ebi_hgqi@yahoo.com.

5. General Physicien, graduate of MPH, Iran University of Medical Sciences and Health Services, Tehran, Iran. Email: smf681@yahoo.com.

6. Resident of Neurosurgery, Department of Neurosurgery, Iran University of Medical Sciences and Health Services, Tehran, Iran. Email: ahmadi.sayedali@gmail.com

7. Resident of Neurosurgery, Department of Neurosurgery, Iran University of Medical Sciences and Health Services, Tehran, Iran. Email: my_md55@yahoo.com

genesis [3].

Oculodermal melanocytosis which is also known as Ota nevus is a flat, slate-gray cutaneous hyperpigmentation in the periocular region [3]. With ocular involvement, similar melanocytic cells are also found in the sclera and uvea [3,4]. When the heavily pigmented dendritic melanocytes aggregate together, forming a distinct pigmented mass, the lesion is called a blue nevus. A blue nevus appears as a gray-blue discoloration of the skin due to reflection of longer wave length of visible light (blue) during passage through the skin. The melanocytic cells of the blue nevus do not disturb normal architecture of the skin [3, 4]. When a blue nevus occurs as an elevated mass comprised of more numerous clustered melanocytes that disrupt the normal tissue architecture, it is called a cellular blue nevus (CBN) [3,4]. Intracranial invasion of CBN from the skin is extremely rare [5-7] and such a condition with malignant transformation is even rarer [6, 8]. Therefore, less than ten cases have been reported to date in regard to the association between meningeal melanocytoma and nevus of Ota. Herein we report a rare case of meningeal melanomas in a 21 years old man with malignant melanoma which was derived from an Ota nevus.

Case Presentation

The patient was a 21 years old man with a neurocutaneous syndrome since childhood. He was presented with headache and mild left hemiparesia. On examination, left proptosis with mild gaze limitation, blue discoloration of the forehead, sclera, conjunctiva and hard palate were detected (Fig. 1). On brain CTscan, a large hyperdense right parietal convexity lesion and retrobulbar lesion extending into the cavernous sinus through the superior orbital fissure with the same density, and expansion of the orbital cavity in favor of long lasting lesion were seen (Fig.2). On brain MRI, the lesions were hyperintense in T1 and mild hypointense

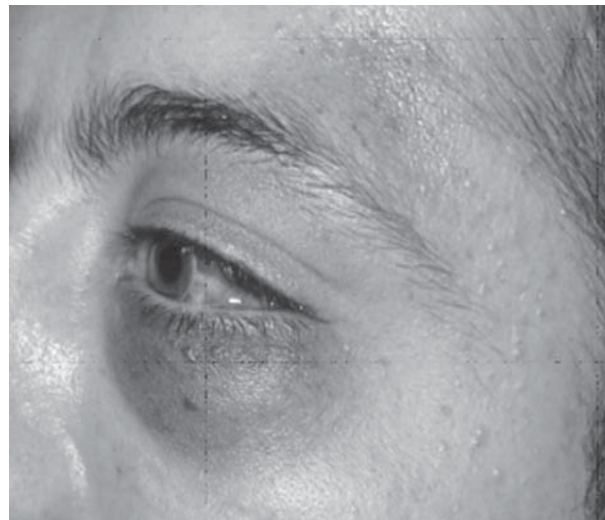

Fig. 1. Left proptosis with mild gaze limitation, blue discoloration of the forehead, sclera, conjunctiva and hard palate.

in T2 with diffuse FLAIR enhancement (Fig. 3).

The patient underwent conjunctival biopsy which leads to the pathologic diagnosis of blue nevus including Immunohistochemistry (IHC) study. Thereafter, his parietal lesion was operated by craniotomy and gross total excision of the lesion with neurologic recovery. On histopathological examination, Haematoxylin and Eosin (H&E) and IHC, diagnosis of malignant

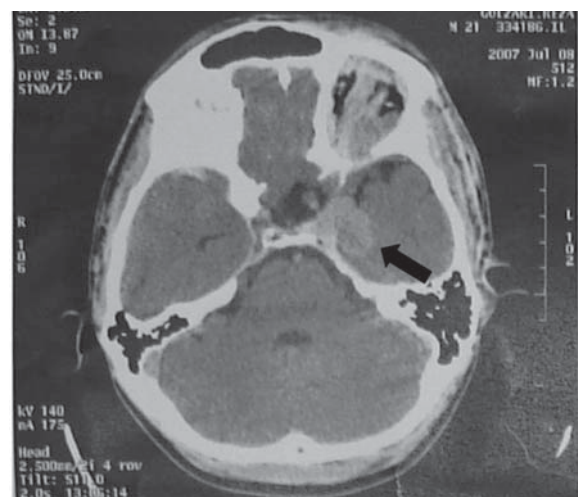


Fig. 2. Results of CT scan showing a large hyperdense right parietal convexity lesion and retrobulbar lesion extending into the cavernous sinus through the superior orbital fissure with the same density, and expansion of the orbital cavity in favor of long lasting lesion (black arrow).

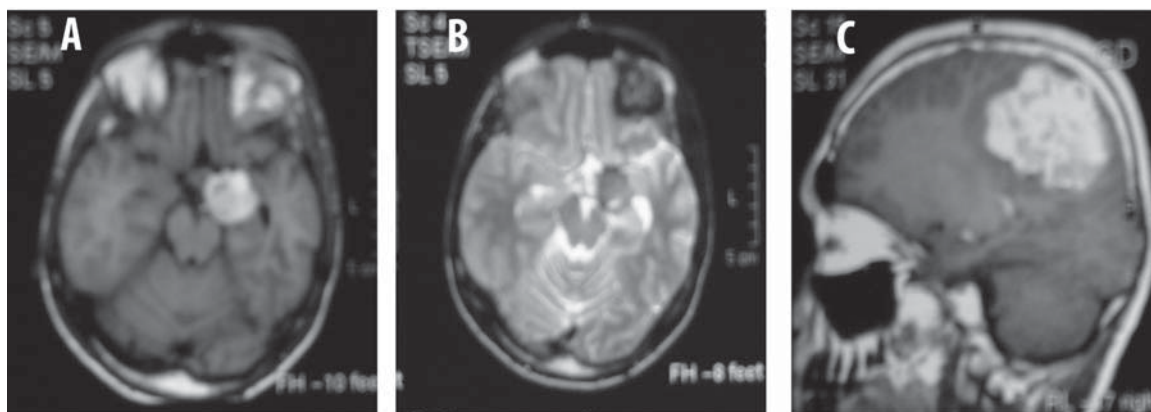


Fig. 3. Brain magnetic resonance imaging (MRI) on admission showing an irregular cavernous sinus mass lesion, hyperintense in T1 (A) and hypointense in T2 (B) (axial views) with diffuse enhancement of parietal lesion (C) (sagittal view).

melanoma was confirmed (Fig. 4).

Systemic evaluations (Skin, Lung, and GI) for melanoma as a metastatic source to the brain were negative. Therefore, whole brain radiotherapy and chemotherapy with temozolamide were started. After about 2 months he afflicted to diplopia and left blurred vision due to enlargement of orbital and cavernous sinus lesion. The patient was operated via pterional craniotomy and subtotal excision of the lesion due to severe bleeding problem. Unfortunately, severe orbital hemorrhage and catastrophic complication of blindness occurred despite the emergent orbital decompression. The histopathologic di-

agnosis of the lesion was malignant melanoma. After radiotherapy and chemotherapy for over one year follow-up, he was survived with diffuse leptomeningeal nodular enhancement in favor of melanoma dissemination (Fig. 5).

Discussion

In this report, a 21 years old man was presented with intracerebral melanomas associated with a blue nevus of the scalp and eye. Its location and appearance during childhood supported the diagnosis of a blue nevus. It is currently believed that the neural crest from which the melanocytes is derived, also contributes to the

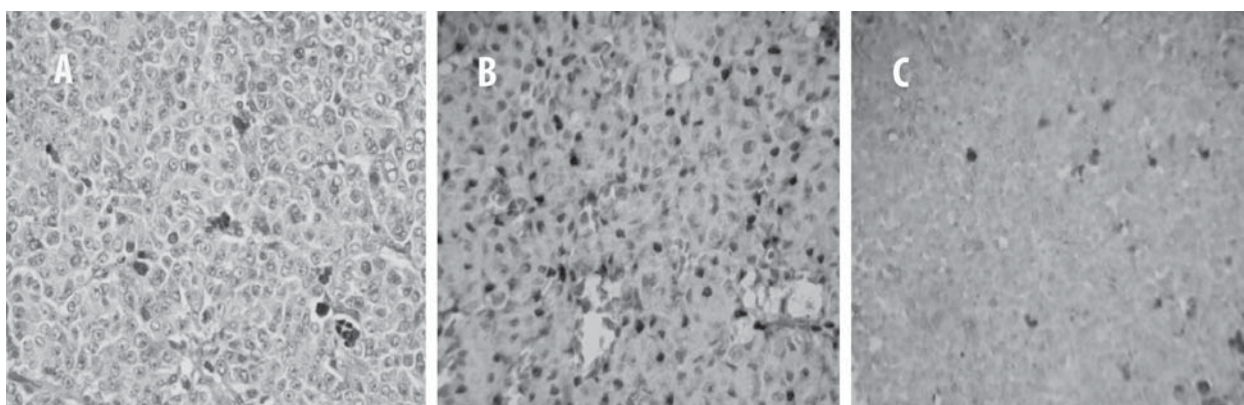


Fig. 4. Photomicrographs of the histopathologic evaluation of the surgical lesion which confirmed malignant melanoma. Haematoxylin and Eosin (H&E)-stained sections (A) revealed the epithelioid and fusiform-shaped tumor cells consisted of variably pigmented spindle cells with abundant scattered intracytoplasmic brown granules of melanin arranged in loose nests or sheets indicating increased malignancy (original magnification $\times 200$). Immunohistochemistry (IHC) examination depicts the tumor cells to be stained strongly positive for both S-100 (B) & HMB45 proteins (C) (original magnification $\times 250$).

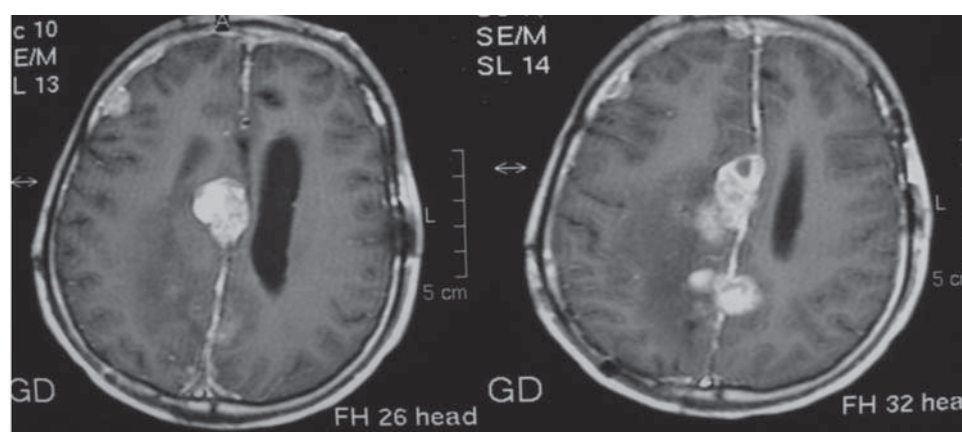


Fig. 5. One year follow-up brain magnetic resonance imaging (MRI) after radiotherapy and chemotherapy showing diffuse leptomeningeal nodular enhancement suggestive of melanoma dissemination.

formation of meninges and the pia mater and blue nevus is a congenital benign melanocytic lesion originating from a disorder of the neural crest [1,2,9]. However, intracranial invasion of CBN from the skin is extremely rare [5-7]. As mentioned, less than ten similar cases with meningeal melanocytoma and nevus of Ota have been reported so far.

In regard to the presentation of symptoms, the most common were ptosis, headache and visual loss [10-14]. Although headache was also presented in our patient, the main symptom appeared to be in left hemiparesia and proptosis. Nonetheless, hemiparesia was reported in two previous cases in right side presented by Moon et al [15] and Hino et al [16].

Theoretically, melanocytomas constitute low grade lesions potentially curable after gross total resection, whereas malignant melanocytic lesions are associated with a less favorable outcome with the possibility of recurrence despite extensive tumor removal. Therefore, an accurate histological classification of a meningeal melanocytic lesion is essential for guiding the treatment plans. Histopathologically, there are elongated, spindle-shaped, or dendritic melanocytes scattered among dermal collagen bundles in the lower two thirds of the dermis in oculodermal melanocytosis [3, 4]. A cellular blue nevus can present with a smooth or irregular

skin surface, which contain large islands of spindle-shaped melanocytes that generally contain little melanin. This may cause confusion with neural tumors such as neurofibroma or schwannoma on light microscopic examination. However, electron microscopic examination shows the presence of melanosomes in the spindle cells [17]. The histopathologic findings of our patients were consistent with blue nevus transforming to malignant melanoma.

Preorbital [18-20] and deep intraorbital cellular blue nevi [21-23] could alter malignant transformation into melanoma, as it occurred in our patient. These features that, alone or in combination, should raise the index of suspicion when evaluating the potentiality of malignancy of a cellular blue nevus with a solitary lesion and with a diameter greater than 2 cm, presence of multiple lesions in a multinodular or plaque form, and a history of rapid or progressive growth or sudden change [24]. All these features were detected in our case.

The intracranial invasion of CBN accompanying with malignant transformation is even rarer [6, 8] which was seen in our presented patient.

In 1989 Cordoba et al [25] considered the meningeal melanocytoma a borderline lesion which is presented by biological characteristics corresponding to a neoplasm with an intermedi-

ate degree of malignancy, with the capacity of modifying spontaneous transformation into a malignant melanoma. Indeed, a minority of primary melanocytic lesions showing intermediate-grade histological characteristics suggestive of more aggressive behavior than melanocytomas has been reported [26,27]. It is now believed that the most important of such intermediate-grade features are an increased mitotic activity and the invasion of the adjacent neural tissue, as opposed to the presence of cytoplasmic and nuclear atypia typically observed in melanomas [28,29]. These features were also seen in the histopathologic evaluation of presented patient; all suggestive of malignant transformation.

Regarding the prognosis, early local recurrences were observed in a few cases despite total [30,31] or subtotal [10] resection of the mass, especially in malignant lesions. Unfortunately, after subtotal excision of the lesion in the patient, severe orbital hemorrhage and catastrophic complication of blindness occurred which were consistent with poor prognosis. Even though the follow-up time of most similar cases were varied between several months to 6 years, the outcome in this case was not extremely bad and the patients survived and except for the one case reported by Navas et al [14] in 2009 a 25-year-old man with a giant fronto-temporal intracranial meningeal melanocytoma associated with a congenital nevus of Ota died after 7 days of follow-up [14]. It is most commonly believed that total resection of the tumor is a very important determinants of outcome in such cases. In an extensive review of the long-term postoperative outcome observed in 27 cases of meningeal melanocytomas, Rades et al [32] calculated a 5-year postoperative survival of 82% in cases of gross total resection, but this survival rate decreased to 43% among partially resected lesions. Additionally, it is recommended to perform postoperative adjuvant radiotherapy in cases of partial resection [33]. However, in the most recent case presented by Navas et al

[14], the patient died even after complete resection of the tumor due to cerebral infarction caused by the occlusion of the middle cerebral artery either by direct tumoral compression or by subsequent increased intracranial pressure [14]. Our patient initially underwent gross total excision of the parietal lesion and then subtotal excision due to severe bleeding and thrived after one year of follow-up. However, he suffered from blindness with diffuse leptomeningeal nodular enhancement of the lesion.

Conclusively, the present case of blue naevus with intracranial invasion and malignant transformation shows that although CBN is considered benign, scalp or periorbital CBN has the potential for intracranial invasion and malignant transformation. Moreover, although primary intracranial melanomas are rare, it should be suspected particularly in the presence of periorbital blue nevus or nevus of Ota.

Acknowledgment

The authors would like to thank the patient himself and his family for this report and also we appreciate the supports of research deputy of University of Medical Sciences and Health Services.

References

1. Hirabuki N, Morino H, Taki T, Yoshida W, Nakamura H. Primary solitary intracranial melanoma in the sylvian fissure: MR demonstration. *Eur Radiol* 2002; 12: S7-S10.
2. Balmaceda CM, Fetell MK, Powers J, O'Brian JL, Housepian EH. Nevus of Ota and leptomeningeal melanocytic lesions. *Neurology* 1993; 43: 381-386.
3. Shields JA. In: *Diagnosis and Management of Orbital Tumors*. Saunders, Philadelphia 1989: 275-287.
4. Dutton JJ, Anderson RL, Schelper RL et al. Orbital malignant melanoma and oculodermal melanocytosis: report of two new cases and review of the literature. *Ophthalmology* 1984; 91: 497-507.
5. Golden N, Maliawan S, Mulyadi K. Cellular blue nevus of the scalp with brain invasion. *J Clin Neurosci* 2000; 7: 453-454.

6. Gunduz K, Shields JA, Shields CL, Eagle RC Jr. Periorbital cellular blue naevus leading to orbitopalpebral and intracranial melanoma. *Ophthalmology* 1998; 105: 2046-2050.
7. Silverberg GD, Kadin ME, Dorfman RF, Hanbery JW, Prolo DJ. Invasion of the brain by a cellular blue naevus of the scalp. A case report with light and electron microscopic studies. *Cancer* 1971; 27: 349-355.
8. Ochiai H, Nakano S, Miyahara S, Goya T, Wakisaka S, Kinoshita K. Magnetic resonance imaging of a malignant transformation of an intracranial cellular blue naevus. A case report. *Surg Neurol* 1992; 37: 371-373.
9. O'Rahilly R, Miller F. The meninges in human development. *J Neuropathol Exp Neurol* 1986; 45: 588-608.
10. Boticelli AR, Villani M, Angiari P, Peserico L. Meningeal melanocytoma of Meckel's cave associated with ipsilateral Ota's nevus. *Cancer* 1983; 51: 2304-2310.
11. Piercecchi-Marti MD, Mohamed H, Liprandi A, Gambarelli D, Grisoli F, Pellissier JF. Intracranial meningeal melanocytoma associated with ipsilateral nevus of Ota. *J Neurosurg* 2002; 96: 619-623.
12. Rahimi-Movaghar V, Karimi M. Meningeal melanocytoma of the brain and oculodermal melanocytosis (nevus of Ota): case report and literature review. *Surg Neurol* 2003; 59: 200-210.
13. Rutten I, Bolle S, Kaschten B, Stevenaert A, Deneufbourg JM, Deprez M. Recurrent intracranial melanocytoma associated with a nevus of Ota. *Acta Neurochir (Wien)* 2005; 147: 313-315.
14. Navas M, Pascual JM, Fraga J, Pedrosa M, Shakur S, Carrasco R et al. Intracranial intermediate-grade meningeal melanocytoma with increased cellular proliferative index: an illustrative case associated with a nevus of Ota. *J Neurooncol* 2009; DOI 10.1007/s11060-009-9907-3.
15. Moon WS, Kim JH, Lee DG, Choi YH, Kim SS. Meningeal melanocytoma associated with Ota's Nevus. Report of a case. *Korean J Pathol* 1992; 26: 605-609.
16. Hino K, Nagane M, Fujioka Y, Shiokawa Y. Meningeal melanocytoma associated with ipsilateral nevus of Ota presenting as intracerebral hemorrhage: case report. *Neurosurgery* 2005; 56: 1376-1377.
17. Lever WF, Schaumburg-Lever G. In: *Histopathology of the Skin*, JB Lippincott, Philadelphia 1990: 776-796.
18. Speakman JS, Phillips MJ. Cellular and malignant blue nevus complicating oculodermal melanosis (nevus of Ota syndrome). *Can J Ophthalmol* 1973; 8: 539-547.
19. Jakobiec FA, Ellsworth R, Tannenbaum M. Primary orbital melanoma. *Am J Ophthalmol* 1974; 78: 24-39.
20. Hagler WS, Brown CC. Malignant melanoma of the orbit arising in a nevus of Ota. *Trans Am Acad Ophthalmol Otolaryngol* 1966; 70: 817-822.
21. Loffler KU, Witschel H. Primary malignant melanoma of the orbit arising in a cellular blue nevus. *Br J Ophthalmol* 1989; 73: 388-393.
22. Rice CD, Brown HH. Primary orbital melanoma associated with orbital melanocytosis. *Arch Ophthalmol* 1990; 108: 1130-1134.
23. Tellado M, Specht CS, McLean IW et al. Primary orbital melanomas. *Ophthalmology* 1996; 103: 929-932.
24. Goldenhersh MA, Savin RC, Barnhill RL, Stenn KS. Malignant blue nevus. Case report and literature review. *J Am Acad Dermatol* 1988; 19: 717-722.
25. Cordoba A, Tunon T, Vazquez JJ. Meningeal melanocytoma. A case report and literature review. *Arch Neurobiol (Madr)* 1989; 52: 93-99.
26. Roser F, Nakamura M, Brandis A, Hans V, Vorkapic P, Samii M. Transition from meningeal melanocytoma to primary cerebral melanoma. *J Neurosurg* 2004; 101: 528-531.
27. Wang F, Li X, Chen L, Pu X. Malignant transformation of spinal meningeal melanocytoma. *J Neurosurg Spine* 2007; 6: 451-454.
28. Brat D, Giannini C, Scheithauer B, Burger P (1999) Primary melanocytic neoplasms of the central nervous system. *Am J Surg Pathol* 1999; 23: 745-754.
29. Brat DJ, Perry A. Melanocytic lesions. In: Louis DN, Ohgaki H, Wiestler OD, Cavenee WK (eds) *WHO classification of tumours of the central nervous system*, 4th edn. IARC, Lyon, 2007; 181-183.
30. O'Brien TF, Moan M, Miller JH, Hemsley SD. Meningeal melanocytoma. An uncommon diagnostic pitfall in surgical neuropathology. *Arch Pathol Lab Med* 1995; 119: 542-546.
31. Winston KR, Sotrel A, Schnitt SJ. Meningeal melanocytoma. Case report and review of the clinical and histological features. *J Neurosurg* 1987; 66: 50-57.
32. Rades D, Heidenreich F, Tatagiba M, Brandis A, Hinrich Karstens J. Therapeutic options for meningeal melanocytoma. Case report. *J Neurosurg* 2001; 95(2 Suppl): 225-231.
33. Rades D, Tatagiba M, Brandis A, Dubben HH, Karstens JH. The value of radiotherapy in treatment of meningeal melanocytoma. *Strahlenther Onkol* 2002; 178: 336-342.