

Prophylactic gastrectomy in familial gastric cancer: case report and review of literature

Shirzad Nasiri¹, Anushiravan Hedayat², Reza malekzadeh³, Zhamak Khorgami⁴,
Nassim sodagari⁵

Department of General Surgery, Tehran University of Medical Sciences, Tehran, Iran.

Received: 28 December 2008

Revised: 7 July 2010

Accepted: 17 July 2010

Abstract

Gastric cancer is the fourth most common cancer and the second leading cause of cancer death. Most cases are sporadic and only 10% of patients, show familial clustering. Among these patients, 1 to 3 % have hereditary diffuse gastric cancer (HDGC), which is autosomal-dominant and present in younger ages. Mutations in E-cadherin gene CDH1 has been identified in 30 to 50% of patients. Because endoscopic surveillance is not effective in identifying early HDGC, gene-directed prophylactic gastrectomy is recommended for CDH1 mutation carriers. But in most carriers who underwent prophylactic gastrectomy, histological examinations on the resected stomach revealed foci of diffuse gastric cancer. It shows that gastrectomy could be curative instead of prophylactic in these cases. Individuals from families with HDGC should be recommended to genetic testing and in patients that have a CDH1 gene mutation, total gastrectomy is indicated. We are presenting a 27 year old patient with striking history of familial gastric cancer and positive E-cadherin gene mutation who underwent prophylactic gastrectomy.

Keywords: CDH1 mutations, hereditary diffuse gastric cancer, prophylactic total gastrectomy.

Introduction

Gastric cancer is a prevalent disease. It is the most common cancer in men in Iran with around 7300 cases per year. Also it is the most common cause of cancer death in men and women in Iran [1]. Life style and environment including Helicobacter pylori infection and diet are risk factors, but 10% of cases with gastric cancer show familial clustering, which suggest a genetic predisposition [2,3].

Somatic E-cadherin gene mutations occur in 30% to 50% of patients with diffuse-type gastric carcinoma but not the intestinal type [1, 4].

A germline mutation in the E-cadherin gene, CDH1 on chromosome locus 16q22.1, first was recognized in a Maori kindred from New Zealand with diffuse gastric cancer in a pattern suggestive of an auto-somal dominant inheritance with incomplete penetrance [1,2]. Hereditary diffuse gastric cancer (HDGC) is an autosomal dominant, inherited cancer syndrome which is described clinically by either 1) 2 or more documented cases of diffuse gastric cancer in first or second degree relatives with at least 1 diagnosed before age 50 years; or 2) 3 or more cases of documented diffuse gastric cancer in first or second degree relatives, inde-

1. **Corresponding author**, MD, Assistant Professor of Surgery, Tehran University of Medical Sciences. Address: General surgery ward, Shariati Hospital, North kargar St. Tehran, Iran. Email: nasiri@razi.tums.ac.ir

2. Associate Professor of Surgery, Tehran University of University of Medical Sciences. hedayat@tums.ac.ir

3. Professor of Gastroenterology, Tehran University of Medical Sciences. malek@ams.ac.ir

4. Assistant Professor of Surgery, Tehran University of Medical Sciences. khorgami@tums.ac.ir

5. Resident of General Surgery, Tehran University of Medical Sciences. nassimso@yahoo.com

pendent of the age of onset [5]. The CDH1 acts as a tumor suppressor gene. More than 50 mutations in different ethnical background have been recognized [5,6]. The CDH1 mutations are related to increased risk of lobular carcinoma of the breast, and colorectal and prostate cancer in addition to HDGC [7, 8].

The Prophylactic surgery for genetic mutations has been performed in patients with an increased risk of breast, thyroid, ovarian, and colon carcinomas and recently the genetic background for a familial form of gastric cancer were reported [3,9]. Endoscopic surveillance for diffuse gastric carcinoma is unreliable because lesions may be present without overlying mucosal irregularities, thereby evading endoscopic detection. In most case series of CDH1 mutation carriers who underwent prophylactic gastrectomy, the removed stomachs contained small foci of early diffuse gastric cancer in histological examination, making the surgery not prophylactic but curative [10,11]. There are very few cases in whom gastrectomy were prophylactic and there were no malignancy on histological findings [12].

Case report

We want to report a case with CDH1 mutation that underwent prophylactic total gastrectomy in shariati hospital and no malignancy was detected.

We had a 27 years old man patient with a striking family history of diffuse gastric carcinoma. Diffuse signet ring cell gastric carcinoma was diagnosed in his mother at age 48 years, in his sister at age 23 years, and in one of his brothers at age 24 years. All of them underwent operation and died within 6-12 months after surgery. His maternal uncle died of gastric cancer in age of 50 years (Fig. 1).

Preoperative esophagogastroduodenoscopy and endoscopic ultrasonography did not reveal any abnormalities. Random biopsies at 2-cm intervals from the entire mucosal plane of the cardia, fundus, body, and antrum were negative for malignancy.

Genetic analysis was performed by PCR amplification followed by sequence analysis of the entire coding region of exon 14 of the CDH1 gene including intron-exon boundaries. A heterozygous c.2275G>T mutation was identified in exon 14 of the CDH1 gene. This mutation alters a glycine into a premature stop codon on

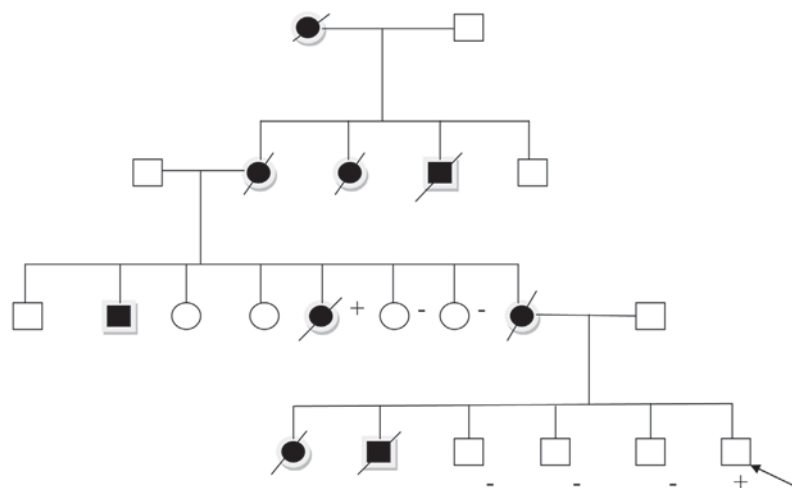


Fig. 1. The case family pedigree of gastric cancer. The squares represent male family members and the circles are female family members; open symbols indicate unaffected persons and solid symbols affected persons. A slash over the symbol denotes death. A plus sign indicates mutation-positive, a minus sign mutation-negative. The arrow identifies the pro-band.

position 759 (p.Gly759X). Genetic testing on patient's three brothers was negative. However, it was positive in one of the patient's three maternal aunts who died later on because of gastric carcinoma.

The Patient underwent total gastrectomy and esophagojejunostomy with jejunal pouch by open approach. Histologically margins were confirmed with frozen section to be without gastric cells and no gross mass was seen in stomach. No malignancy was detected on pathologic examination of the whole gastric mucosa. Nonetheless no intestinal metaplasia or dysplasia was detected.

Discussion

In 2001 the first prophylactic total gastrectomy was reported in five patients with a known germline E-cadherin mutation in whom preoperative endoscopic examination did not show carcinoma [3,13]. To our knowledge, most often histological examination of patients after prophylactic total gastrectomy reveals malignancy [14,15]. Our patient is one of the few cases in which gastrectomy performed as prophylactic measure without any histological malignancy.

Gastric cancer ranks second in the risk of mortality for cancer worldwide [16]. The most important risk factors for gastric cancer may attributed to nutritional habits and an infection with *Helicobacter pylori* [17]. Only a very small number of gastric carcinomas are caused by genetic alterations that lead to a familial gastric cancer, which is termed hereditary diffuse gastric cancer (HDGC) [4,5,11,15]. It is estimated that 25% of families meeting the criteria for familial diffuse gastric carcinoma will have germline mutations of the E-cadherin gene [16].

The CDH1 is localized on chromosome 16q22.1 and encodes the calcium dependent cell adhesion glycoprotein E-cadherin [17,23]. Cadherins are a family of calcium-dependent transmembrane linker proteins. They are the

most important intercellular adhesion receptors [8,12]. The first three cadherins discovered were named according to their tissue origin (E-cadherin from epithelium, N-cadherin from neural tissue, and P-cadherin from placenta) [6,18]. The glycoprotein E-cadherin is a calcium-dependent cell adhesion molecule localized in the epithelial cells that regulates the hemophilic and homotypic adhesion between epithelial cells [6]. The transmembrane protein, E-cadherin, connects to the actin cytoskeleton through a complex with α -catenin, β -catenin, and γ -catenin [19]. Functionally E-cadherin impacts maintenance of normal tissue morphology and cellular differentiation. Mutations of CDH1 leads to loss of cell adhesion, proliferation, invasion, and metastasis [23]. The first step leading to invasion is thought to be cancer cell detachment, which requires modulation of cell-cell interactions [7, 20]. Both intramucosal and advanced stage signet ring cell carcinoma demonstrate somatic E-cadherin mutations, suggesting that this gene mutation is an early event in the molecular evolution of diffuse gastric carcinoma [8, 21].

Numerous pathological studies have demonstrated a significant correlation between the degree of E-cadherin expression and the grade of tumor differentiation. An immunohistochemical analysis by Mayer et al.[10] found that low E-cadherin expression is significantly associated with tumor recurrence, cellular dedifferentiation, and the diffuse tumor type. The penetrance of germline CDH1 mutations is estimated to be 70% [4]. Thus an E-cadherin gene mutation carrier in a hereditary diffuse gastric carcinoma family has an approximately 70% life-time risk of developing gastric carcinoma [22]. The E-cadherin mutations are identified in 50% of diffuse type gastric cancer patients that typically result in inframe deletions removing partial or complete exon sequences from the extracellular portion of the transmembrane protein or point mutations resulting in amino acid substitutions [23]. All familial gas-

tric carcinomas occurring in families with the CDH1 mutation have been of the diffuse histological type, frequently resulting in linitis plastica, as a result, mucosal abnormalities tend to occur late and delay the endoscopic diagnosis. It is usually not associated with mass lesions or ulcers, therefore, surveillance endoscopy might identify only relatively advanced disease. In nonendemic regions, only about 15% of gastric cancer cases are diagnosed in the stage of early cancer with a really good prospect of curing the patient, [9,11] and more than 60% of the patients are diagnosed in incurable advanced stages [13,16]. Therefore preventive total gastrectomy should be the management of choice for all germline E-cadherin gene mutation carriers. Mortality is below 2% in these young and healthy patients, and the complication rate should not exceed 20% [25].

The average onset in both men and women is 38 years, although cases of onset at ages 14, 15, and 16 years have been documented in the reported literatures with several cases between 20-30 years of age [19]. It is essential that patients carrying the gene have the opportunity for extensive counseling, discussion, and reflection with knowledgeable clinicians, genetics, and counselors before making the decision to proceed. moreover, preventive total gastrectomy should not be suggested to the patient before the age of 18 years [20]. To our knowledge, the efficacy of surveillance for diffuse gastric carcinoma by current methods is unknown because the majority of tumors spread submucosally rather than form a visible exophytic mass. Furthermore, the prognosis for diffuse gastric carcinoma is poor, with a 5-year survival rate of 10% [14]. The cure rate in patients with Medullary Thyroid Carcinoma (MTC) diagnosed by RET gene mutations and operated early, is nearly 100%, and it has been anticipated a similar cure rate in HDGC patients diagnosed by CDH1 mutation [17,26].

The management of individuals with suspected familial diffuse gastric carcinoma in-

cludes: 1) pedigree analysis, 2) education and counseling to determine whether the patient wants genetic testing, 3) genetic testing, and disclosure of results, 4) determination of cancer risk, and 5) review of options for management and follow-up. Education and counseling for potential carriers of a germline CDH1 mutation should emphasize the unknown efficacy of current endoscopic surveillance methods in detecting diffuse gastric carcinoma, the need for more data to quantify the risk of developing gastric carcinoma, and the potential complications of total gastrectomy.

Van Kouwen et al [19] reported a single case in which a documented CDH1 carrier from a HDGC family had two abnormal foci identified by Positron Emission Tomography (PET) in the proximal and pyloric regions of the stomach, and following gastrectomy, signetring carcinoma was found in these and other areas. It is not wise to conduct all the standard diagnostic tests, including endoscopy with multiple biopsies, PET/CT, and endoscopic ultrasound, because none of these techniques were able to detect gastric cancer that was already present in patients [27]. Current recommendation is to proceed with total gastrectomy in gene carriers who are 5 years younger than the age of the youngest family member who developed gastric cancer [21,23].

The most crucial complication after total gastrectomy is the leakage of the esophagojejunostomy. A leakage rate of about 7% must be assumed [24]. However, there is a close correlation between morbidity and mortality after total gastrectomy and the experience of the surgeon executing this procedure. These data may not apply to a healthy, young population or to patients undergoing prophylactic gastrectomy, in which a very high rehabilitation rate can be anticipated.

Various methods of reconstruction after total gastrectomy have been described. After reconstruction with a jejunum pouch, patients have better food intake, slower food passage, fewer

postprandial symptoms, less weight loss and a tendency to better quality of life. A small 10-cm jejunum pouch is superior to longer pouches [28].

Conclusion

This study demonstrated an example of an inherited cancer that was diagnosed by a gene mutation but could not be detected at an early stage with current state-of-the-art screening methodologies mandating a potentially curative surgical procedure. At present, when individuals from families with HDGC have a CDH1 gene mutation, a total gastrectomy is indicated. The current results and the literature support this recommendation, despite negative preoperative studies in most patients have early invasive signet ring cell gastric cancer. Like MTC there is no curative treatment of gastric cancer other than early detection and total gastrectomy. This is another example of geneticists and genetic counselors, oncologists, gastroenterologists, radiologists, surgeons, and pathologists working together to turn an inherited lethal disease into a curable one. In the future, other molecular markers are expected to provide early diagnosis and curative surgery in other malignant lesions.

Acknowledgments

Thanks to surgery and gastroenterology department of Shariati Hospital for their aids in managing and data collecting for this patient.

References

1. Schwarz A. Preventive gastrectomy in patients with gastric cancer risk due to genetic alterations of the E-cadherin gene defect. *Langenbecks Arch Surg* 2007; 388:27-32.
2. Guilford P, Hopkins J, Harraway J, McLeod M, McLeod N, Harawira P, Taite H, Scoular R, Miller A, Reeve AE E-cadherin germline mutations in familial gastric cancer. *Nature* 1998; 392:402-405.

3. Lauren P. The two histological main types of gastric carcinoma: diffuse and so-called intestinal-type carcinoma. *APMIS* 1965;64:31-49.
4. Lewis FR, Mellinger JD, Hayashi A, et al. Prophylactic total gastrectomy for familial gastric cancer. *Surgery* 2001;130:612-617;discussion 617-619.
5. Boyle P. Global cancer burden. *Lancet* 1997; 349:23-26.
6. Caldas C, Carneiro F, Lynch HT, Yokota J, Wiesner GL, Powell SM Familial gastric cancer: overview and guidelines for management. *J Med Genet* 1999;36:873-880.
7. Guilford PJ, Hopkins JBW, Grady WM, Markowitz SD, Willis J, Lynch H E-cadherin germline mutations define an inherited cancer syndrome dominated by diffuse gastric cancer. *Hum Mutat* 1999;14:249-255.
8. Tanaka M, Kitajima Y, Edakuni G, Sato S, Miyazaki K Abnormal expression of E-cadherin and betacatenin may be a molecular marker of submucosal invasion and lymph node metastasis in early gastric cancer. *Br J Surg* 2002; 89:236-244.
9. Muta H, Noguchi M, Kanai Y, Ochiai A, Nawata H, Hirohashi S. E-cadherin gene mutations in signet ring cell carcinoma of the stomach. *Jpn J Cancer Res* 1996; 87:843-848.
10. Mayer B, Johnson JP, Leitzl F, Jauch KW, Heiss MM, et al. E-cadherin expression in primary and metastatic gastric cancer: down-regulation correlates with cellular dedifferentiation and glandular disintegration. *Cancer Res* 1993; 53:1690-1695.
11. Berx G, Becker KF, Hoefler H, Van Roy F Mutations of the human E-cadherin (CDH1) gene. *Hum Mutat* 1998; 12:226-37.
12. Schwarz A, Jung M, Kunz R, Beger HG Risiko der Gastrektomie wegen Magenkarzinom in Abhängigkeit vom Rekonstruktionsverfahren. *Langenbecks Arch Chir Suppl II Kongressbd* 1997; 1069-1971.
13. Schwarz A, Beger HG Gastric substitute after total gastrectomy clinical relevance for reconstruction techniques. *Langenbecks Arch Surg* 1998; 383:485-491.
14. Yoshida S, Saito D Gastric premalignancies and cancer screening in high-risk patients. *Am J Gastroenterol* 1996; 91:839-843.
15. Wanebo HJ, Kennedy BJ, Chmiel J, Steele G, Winchester D, Osteen R. Cancer of the stomach: a patient care study by the American College of Surgeons. *Ann Surg* 1993;218:583-92.
16. Caldas C, Carneiro F, Lynch HT, Yokota J, Wiesner GL, Powell SM, et al. Familial gastric cancer: overview and guidelines for management. *J Med Genet* 1999;36:873-80.
17. Charlton A, Blair V, Shaw D, et al. Hereditary diffuse gastric cancer: predominance of multiple foci of signet-ring cell carcinoma in distal stomach and transi-

tional zone. *Gut* 2004;53:814-820.

18. Dussaulx-Garin L, Blayau M, Pagenault M, et al. A new mutation of E-cadherin gene in familial gastric linitis plastica cancer with extra-digestive dissemination. *Eur J Gastroenterol Hepatol* 2001;13:711-715.

19. van Kouwen MC, Drenth JP, Oyen WJ, et al. ¹⁸F-Fluoro-2-deoxy- D-glucose posi-tron emission tomography detects gastric carcinoma in an early stage in an asymptomatic E-cadherin mutation carrier. *Clin Cancer Res* 2004;10:6456-6459.

20. Suriano G, Yew S, Ferreira P, et al. Characterization of a recurrent germ line mutation of the E-cadherin gene: implications for genetic testing and clinical management. *Clin Cancer Res* 2005;11:5401-5409.

21. Chun YS, Lindor NM, Smyrk TC, et al. Germline E-cadherin gene mutations: is prophylactic total gastrectomy indicated? *Cancer* 2001; 92:181-187.

22. Jeffrey A. Norton, MD, Christine M. Ham, MD, et al. CDH1 Truncating Mutations in the E-Cadherin Gene an Indication for Total Gastrectomy to Treat Hereditary Diffuse Gastric Cancer. *Annals of Surgery* 2007 ; 245, (6):873-79.

23. Robin M. Cisco, James M. Ford, Jeffrey A. Norton. Hereditary diffuse gastric cancer: Implications of genetic testing for screening and prophylactic surgery. *CANCER Supplement* 2008 ; 1;113(7):1850-6.

24. C.Oliveira et al. Hereditary gastric cancer. Best practice and research clinical gastro-enterology 2009;23:147-157.

25. Kaurah P, MacMillan A, Boyd N, et al. Founder and recurrent CDH1 mutations in families with hereditary diffuse gastric cancer. *JAMA* 2007; 297:2360-2372.

26. Keller G, Vogelsang H, Becker I, et al. Diffuse type gastric and lobular breast carcinoma in a familial gastric cancer patient with an E-cadherin germline mutation. *Am J Pathol* 1999; 155:337-342.

27. Richards FM, McKee SA, Rajpar MH, et al. Germline E-cadherin gene (CDH1) mutations predispose to familial gastric cancer and colorectal cancer. *Hum Mol Genet* 1999;8:607-610.

28. Huntsman DG, Carneiro F, Lewis FR, et al. Early gastric cancer in young asymptomatic carriers of germline E-cadherin mutations. *N Engl J Med* 2001; 344:1904-1909.