

Epidermal inclusion cysts of the breast

Amir R. Motabar, MD.¹

Department of Surgery, Iran University of Medical Sciences, Tehran, Iran.

Abstract

Epidermal inclusion cysts are uncommon in the breast, but the consequences can be severe when these cysts occur in the breast parenchyma. Here, we report two such cases. The patient in case 1 was a 37-year-old woman with a 3-cm palpable mass in the right breast. Mammography revealed a round and smoothly outlined mass, which indicated a benign tumor, and sonography showed an irregularly shaped and heterogeneous hypoechoic mass, fibroadenoma was suspected on the basis of clinical and image findings, but excisional biopsy revealed an epidermal inclusion cyst. The patient in case 2 was a 50-year-old woman with a 2.5-cm lesion in the left breast. Mammography revealed a round, dense, smoothly outlined mass, and sonography showed a well-defined, central hyperechoic mass. Breast cancer was suspected on the basis of the sonographic findings and the age of the patient, but the resected specimen revealed an epidermal inclusion cyst. Although epidermal inclusion cysts are benign, occasionally they may play a role in the origin of squamous carcinoma of the breast. Mammographic and sonographic features of an epidermal cyst may mimic a malignant lesion. Malignant change appears to occur more frequently in epidermal inclusion cysts in the mammary gland, compared to common epidermal inclusion cysts, and this may be associated with origination of mammary epidermal inclusion cysts from squamous metaplasia of the mammary duct epithelium.

Epidermoid inclusion cyst of the breast is potentially serious, although such cysts are rare, and differentiation from a malignant or benign breast tumor is required. Excision is probably the most appropriate treatment, and can eliminate the possible risk of malignant transformation.

Keywords: epidermal inclusion cyst, epidermoid cyst, breast, cancer.

Introduction

An epidermal inclusion cyst lined by a cornified epithelium, has a distinct granular layer, and contains lamellated keratin without calcification. Such cysts most commonly occur on the scalp and in the skin of the neck and back, whereas they are only rarely found in other areas, including the skin of the breast; to date,

fewer than 40 cases of epidermal inclusion cysts of the breast have been reported in the English-language literature [1-9].

Diagnosis is straightforward for epidermal inclusion cysts that occur in the breast subcutis as a small nodule, but enlarged cysts in the breast parenchyma require to be differentiated from malignant or benign tumors of the breast. This article two case of epidermoid cyst of breast were explored.

1. **Corresponding author**, Resident of General Surgery, Department of Surgery, Iran University of Medical Sciences, Rasool-e-Akram Hospital, Niayesh St. Tehran, Iran. Tel: +98912 1500971, email: amotabar@yahoo.com

Case 1

An 37-year-old woman was referred to our hospital for investigation of a palpable mass in her right breast. She had been aware of the mass for about six months after delivery. Examination revealed a 3-cm lesion in the lower outer quadrant of the right breast. The lesion appeared to be round, firm, well-described and without adherent to the overlying skin. Mammography revealed a round, dense, smoothly outlined mass (Fig. 1), and sonography showed a well-defined, but irregularly shaped and heterogeneous hypoechoic mass measuring 45×30 mm. Samples obtained by fine needle aspiration lacked epithelial cells and could not be used for evaluation. Breast cancer was unsuspected on the basis of the sonographic findings and the age of the patient, and excisional biopsy was performed. The mass measured 3.5×3.5 cm and the cut surface revealed a cystic cavity filled with fragile, greasy and dark-brown material.

Pathologic examination revealed the cyst consisted of mature squamous epithelium and with the multiple layers of keratin, consistent with an epidermal inclusion cyst (Fig. 2- 3).

Case 2

A 50-year-old woman was referred to our hospital for investigation of a mass in her right & left breast. The mass had persisted for 2 years and had history of hysterectomy due to uterine myoma three years ago also had lumpectomy in left breast two years ago and because of pain it diagnosed as fibroadenoma. Examination revealed a 2-cm lesion in the center of the right breast. The lesion appeared to be round, firm, well-described and partially attached to the skin in the lower half of the breast. Mammography revealed a round, dense, smoothly outlined mass measuring 2.5cm in the right breast and round masses 1*1 in left breast.

Sonography showed a well-defined, central hyperechoic mass measuring 3cm in the right

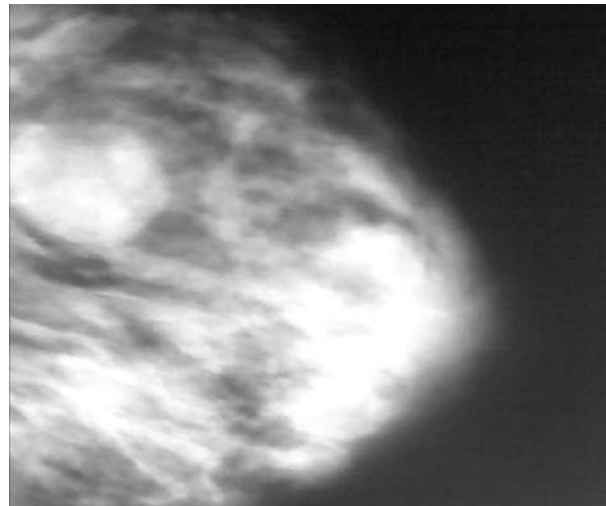


Fig. 1. Left craniocaudal mammogram in a 37-year-old woman shows an epidermal inclusion cyst with a 3-cm diameter

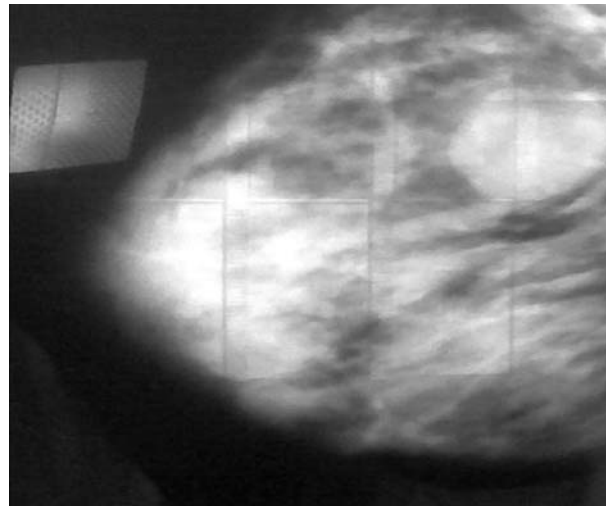


Fig. 2. Left lateral mammogram.

breast and multiple cysts in both breasts . Fine needle aspiration samples of the main lesion revealed an absence of epithelial cells and a small amount of keratin. On the basis of the clinical and imaging findings, a phyllodes tumor or a giant fibroadenoma with hyaline degeneration was suspected. After excisional removal of mass, an epidermoid cyst was confirmed, and also in left breast fibroadenoma was confirmed again.

Discussion

Epidermal cysts in the breast are believed to

arise through several different mechanisms. First, they can develop from obstructed hair follicles. Second, they may result from trauma, such as reduction in mammoplasty or needle biopsy of the breast, which may cause torn fragments of the epidermis with the deep infiltration within the breast tissue [1-3]. Third, they can be generated by squamous metaplasia of normal columnar cells within an ectatic duct in an area of fibrocystic disease or in a fibroadenoma [4]. In our two cases, the pathogenesis of the epidermal inclusion cysts may have been due to obstruction of the hair follicles. There was no past history of breast biopsy or trauma in either case and both tumors were adherent to the overlying skin, with no episode of inflammation of the cyst in either case. Generally, the epidermal inclusion cysts that develop in the skin of the head and dorsal regions are macroscopically noted as the skin protrusions, which may be due to the firm composition of subcutaneous tissue such as bone and muscle in those regions. On the other hand, histologically flexible fat and mammary gland tissues are present under the breast skin, and this may explain why epidermal inclusion cysts that develop in the breast skin grow toward the deep subcutaneous tissue and are difficult to distinguish clinically from a mammary gland tumor. On mammography, an epidermal inclusion cyst appears as a well-circumscribed, homogeneous density and thus is distinguishable from breast cancer [5]. Even when the mammographic appearance of a palpable mass is consistent with a benign lesion, the finding of a solid lesion on sonography may require tissue diagnosis to exclude a carcinoma with well-defined borders, as in case 1. On sonography, the breast epidermal inclusion cysts have a solid, well-circumscribed and complex appearance; the specific sonographic features of these cysts were described by Pavel et al. as an onion-ring appearance with alternating concentric hyperechoic and hypoechoic rings, which correspond to the pathologic features of lamellated keratin [6].

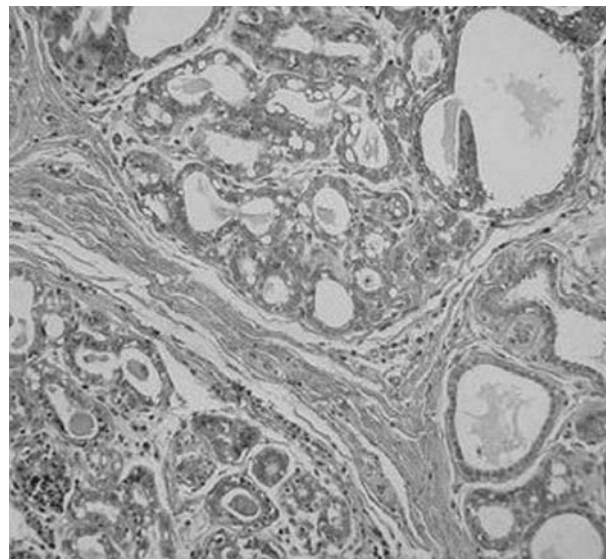


Fig. 3. Microscopic view of excisional biopsy.

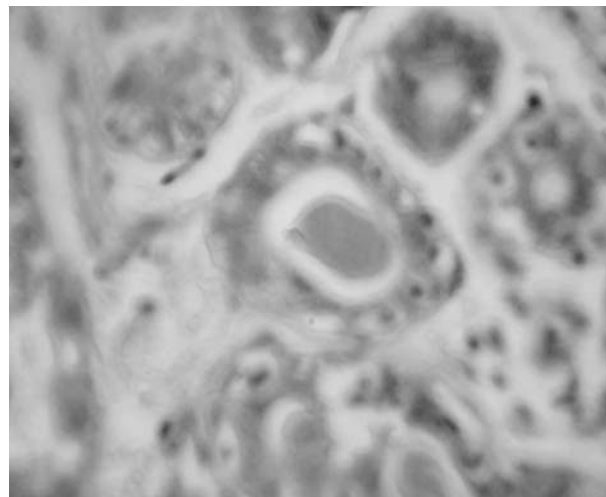


Fig. 4. Photomicrograph shows keratinaceous debris from the center of the epidermal inclusion cyst. (Hematoxylin-eosin stain; original magnification, X400).

Although epidermal inclusion cysts are benign, occasionally they may play a role in the origin of squamous carcinoma of the breast. Squamous cell carcinoma develops only rarely (0.045%) in the wall of common epidermal inclusion cysts [7].

Nonetheless, Menville et al. identified 36 cases of epidermal inclusion cysts of the breast out of a total of 3000 breast lesions, and found that 29 of these epidermal cysts were benign and 7 (19%) were malignant [8]. Willis and Hasleton also reported a possible role of epidermal inclu-

sion cyst in the origin of squamous carcinoma of the breast [9,10], but the true incidence of malignant change in epidermal inclusion cysts is not known.

Malignant change appears to occur more frequently in epidermal inclusion cysts in the mammary gland, compared to common epidermal inclusion cysts, and this may be associated with origination of mammary epidermal inclusion cysts from squamous metaplasia of the mammary duct epithelium.

In a search of the English-language literature, 12 cases of epidermal inclusion cysts were reported [5,9-13]. All but one of these cysts were circumscribed, round on oval, isodense on high-density masses with a diameter of 0.8-10.0cm; these appear to be the most common mammographic findings of an epidermal inclusion cyst—a conclusion that supports our results. Such cysts have been noted, at histopathologic examination, to have associated with calcifications [5,9], but, to our knowledge, we were the first to report the radiographic depiction of epidermal inclusion cysts that contain heterogeneous microcalcifications. Several causes for epidermal inclusion cysts have been proposed. The cysts may be congenital, or they may be metaplastic lesions in which the usual columnar cells of the breast transform to squamous cells [5,9,11].

Inflammatory downward growth of the epidermis caused by an obstructed hair follicle on pore has been postulated [5,10]. Epidermal inclusion cysts can also be a result of trauma, with tom fragments of the epidermis being mplantd more deeply [9,10,12,13]. Genlock [9] reported two cases of epidermal cysts associated with fineneedle aspiration biopsy, and Fajando and Bessen [12] and Brown et al [13] reported epidermal inclusion cysts that were resulted from reduction in mammoplasty. Because of the fatty content, steatocystomas typically appear on mammograms as radiolucent lesions [14]. Mammoplasty reduction has become an increasingly common surgical procedure in the

United States. Because the technique generally involves repositioning of the nipple-areolar unit with infolding of a vascularized tissue pedicle, epidermal inclusion cysts may develop after the procedure. The authors encountered three cases of epidermal inclusion cysts after reductionin mammoplasty and describe the associated mammographic and sonographic characteristics. The authors found that stereotaxic needle biopsy was useful for the diagnosis of these lesions [15].

In summary, an epidermal inclusion cyst of the breast is potentially serious, although such cysts are rare, and differentiation from a malignant or benign breast tumor is required. They may play a role in origin of the rare squamous carcinoma of the breast as suggested by Hasleton and colleagues [10]. Clinically they can mimic benign as well as malignant tumours [16]. Excision is probably the most appropriate treatment, which eliminates the possible risk of malignant transformation.

References

1. Gerlock AJ. Epidermal inclusion cyst of the breast associated with needle aspiration biopsy. *Radiology* 1974;112:69-70.
2. Davies JD, Nonni A, D'Costa HF. Mammary epidermoid inclusion cysts after wide-core needle biopsies. *Histopathology* 1997; 31: 549-551.
3. Fajardo LL, Bessen SC. Epidermal inclusion cyst after reduction mammoplasty. *Radiology* 1993;186: 103-106.
4. Chantra PK, Tnag JT, Stanley TM, Bassett LW. Circumscribed fibrocystic mastopathy with formation of an epidermal cyst. *AJR Am J Roentgeno* 1994; 163: 831-832.
5. Morris PC, Cawson JN, Balasubramaniam. Epidermal cyst of the breast: detection in a screening programme. *Australas Radio* 1991; 43: 12-15.
6. Crystal P, Shaco-Levy R. Concentric rings within a breast mass on sonography: lamellated keratin in an epidermal inclusion cyst. *AJR Am J Roentgenol* 2005, 184:S47-S48.

7. Cameron DS, Hilsinger RL. Squamous cell carcinoma in an epidermal inclusion cyst: case report. *Otolaryngol Head Neck Surg* 2003, 129:141-143
8. Menville JG: Simple dermoid cysts of the breast. *Ann Surg* 1936, 103: 49-56.
9. Willis RA: Squamous-cell mammary carcinoma of predominantly fibrosarcoma-like structure. *J Pathol Bacteriol* 1958; 76: 511-515.
10. Hasleton PS, Misch KA, Vasudev KS, George D. Squamous carcinoma of the breast. *J Clin Pathol* 1978; 31:116-124.
11. Mitnick JS, Roses DF, Harris MN, Colen SR. Calcifications of the breast after reduction mammoplasty. *Surg Gynecol Obstet* 1990; 171: 409-412.
12. Fajardo LL, Bessen SC. Epidermal inclusion cyst after reduction mammoplasty. *Radiology*, 1993; 186: 103-106.
13. Brown FE, Sargent SK, Cohen SR, Monan WD. Mammographic changes following reduction mammoplasty. *Plast Reconstr Surg* 1987; 80:691-698.
14. Pollack AH, Kuerer HM. Steatocystoma multiplex: appearance at mammography. *Radiology* 1991; 180:836-838.
15. Fajardo LL, Bessen SC. Epidermal inclusion cyst after reduction mammoplasty, *Radiology* 1999;186(1):103-6.
16. Chatterjee PK, Roy SN. Large epidermal cyst of breast simulating malignant growth. *Br Med J* 1979;1:167-168.