

An unusual localization of hydatid cyst in a patient with endometrial cancer

Afsaneh Tehranian, MD.¹, Bita Eslami, MPH.²

Department of Gynecology and Obstetrics, Roointan Arash Women's Health Research and Educational Hospital, Tehran University of Medical Sciences, Tehran, Iran.

Abstract

Hydatid disease is a widespread parasitic infection caused by tapeworm *Echinococcus* and it affects mainly the liver, but other organs such as pelvic organs could be involved very rare. Here we report a case of hydatid cyst with involvement of oviduct in a woman with endometrial cancer. It was misdiagnosed as a multicystic right ovarian mass before surgery and by microscopic study it was shown as a primary degenerated hydatid cyst which was also unusual. Although pelvic echinococcal cysts rarely occur, the gynecologists should be consider, and the possibility of a hydatid cyst when they find a pelvic cystic mass, especially in areas where the disease is endemic.

Keywords: hydatid disease, echinococcus, oviduct, endometrial cancer.

Introduction

Hydatid disease (*Echinococcus granulosus*) is endemic in cattle-and sheep-raising regions of the world such as the Middle East, the Mediterranean countries, Central Europe, India, Africa, South America, New Zealand, Australia and Southern Europe. The liver is the most frequently involved organ (75%), followed by the lung (15%) and the remainder of the body (10%) [1]. It can also affect the brain, heart, kidney, ureter, spleen, uterus, fallopian tube, mesentery, pancreas, diaphragm, and muscles [2]. Even though hydatid cysts can occur in any organ, it is very rare to see the disease in the pelvic organ reported in this communication.

The clinical presentation of hydatid disease depends on the size and site of the lesion and the

accessibility of the organ involved for clinical examination. The growing cyst might not include clinical manifestations but an increase in cyst size, terminates in either host or parasite death [3]. Clinical history, serologic tests and various imaging techniques such as ultrasonography, computed tomography (CT) and magnetic resonance imaging (MRI) can help the diagnosis. Hydatid disease may be confused with malignancies of the affected organs. The treatment of hydatid cysts is principally surgical. We report a case of oviduct hydatid cyst encountered in our operative practice.

Case report

An 84-years-old (gravida 5, para 5) woman was referred with spotting, followed by sever bleeding, which had begun approximately 2 months ago. Menopausal age was at 48 years-old. With a history of heart disease and bypass

1. **Corresponding author**, Assistant Professor of Gynecology and Obstetrics, Tehran University of Medical Sciences, Roointan Arash Women's Health Research and Educational Hospital, Tehran, Iran. P.O. Box:1653915981; Tel:+98-21 77883195; Fax:+9821 77883196, email: afsanehtehranian@yahoo.com

2. Assistant Professor of Gynecology and Obstetrics, Roointan Arash Women's Health Research and Educational Hospital, Tehran University of Medical Sciences, Tehran, Iran.

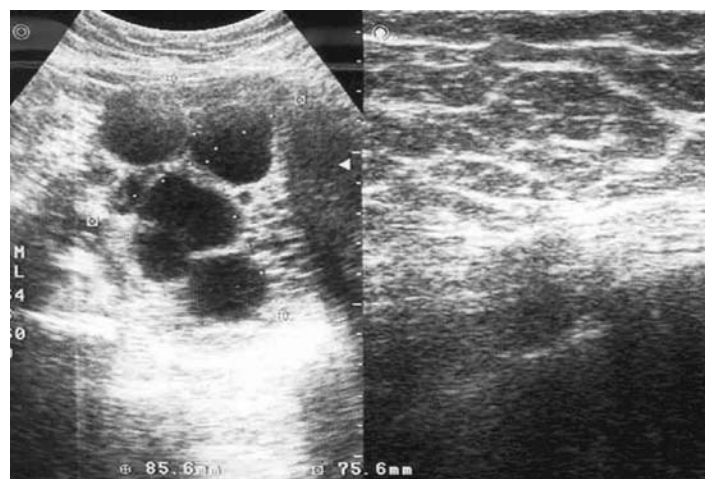


Fig. 1. Sonographic appearance of the oviduct hydatid cyst showing.

surgery. Furthermore, she had lived in the rural area for several years, and had no abnormality in general examination. An enlarged uterus and a right adnexal mass were found on bimanual examination. By endometrial biopsy, endometrial adenocarcinoma (endometrioid villoglandular type) was diagnosed in this patient. On Ultrasonography, a multi-cystic adnexal mass of about 92 × 73 × 69 mm was found on the right side (Fig. 1).

A subsequently performed MRI which was recommended by the sonographer, revealed a right multi-cystic ovary and enlarged uterus without any disease (Fig. 2). The diagnosis of endometrial cancer was determined and the patient was prepared for surgery. Chest X-ray and other routine preoperative tests include CBC, Platelet counts, serum chemistries and urine analyses were all normal. Surgical staging based on the 1988 FIGO system was performed. The uterine size was in about 12 weeks of gestation. Both ovaries were normal but the right sided one, adhered to pelvic side wall, bowel and dilated cystic fallopian tube, and full of adhesions. The cyst was ruptured during the operation and the diagnosis of hydatid cyst was made. Then, in order to prevent further spread or anaphylactic reaction, the cavity was washed by hypertonic saline solution, so, the rupture of cyst would not cause any problem for patient. Final pathologic works confirmed endometrial

cancer (stage IA, G1) and hydatid cyst of right oviduct. Two others pathologist were confirmed the diagnosis of hydatid cyst also (Fig. 3). Albendazol therapy was started on two days after surgery. The patient recovered well and was discharged on the fourth day of post-operation. She was well and asymptomatic after 5 months follow-up.

Discussion

Pelvic echinococcosis is rare with an incidence between 0.2 and 0.9%. They are usually secondary to rupture of cysts in other organs, but primary cases such as this one have been also reported [4]. The symptoms of pelvic echinococcosis are not specific [4]. It may be

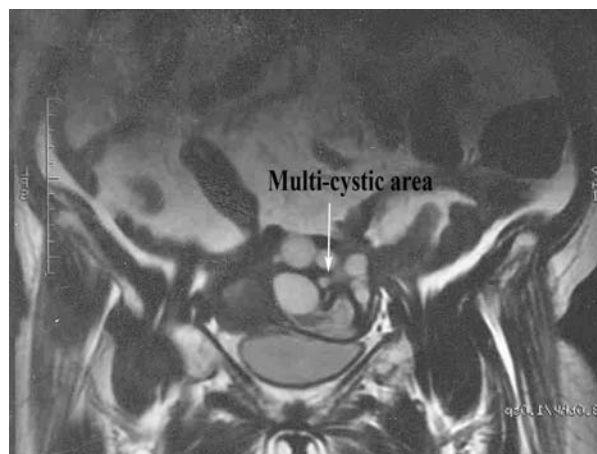


Fig. 2. A cystic area and enlarged uterus which was shown by MRI.

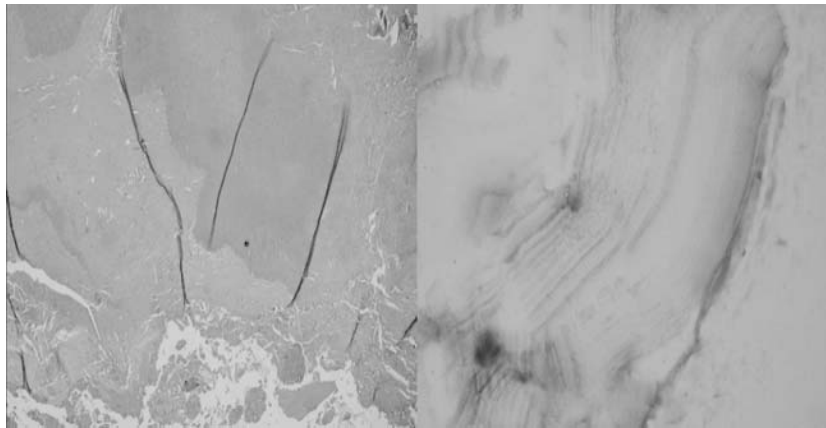


Fig. 3. Laminated membrane of hydatid cyst without scolex.

associated with unusual presentation, such as simulation of malignancies [5,6] and mimic a multicystic ovary [7]. Diagnosis of hydatid cysts is very difficult and should be considered in the differential diagnosis of cystic pelvic masses, especially in patients residing in or coming from endemic areas.

Serologic tests, sonography especially TVS, CT scans and MRI can be useful in the preoperative diagnosis, but definitive diagnosis is confirmed histologically.

In this case, it was difficult to make the correct diagnosis preoperatively. The sonographic appearance of the echinococcal cyst was as a hypoechogenic multicystic mass in association with endometrial carcinoma of the uterus, had brought the possibility of malignancy into mind.

The main treatment is surgery and intra-operation use of scolicedal agents such as hypertonic saline, 0.5% silver nitrate [8], NaCl or povidon iodine [9] solutions is used to prevent further spread or anaphylactic reaction [8]. Albendazol or mebendazol should be used as an adjunct to surgery [9].

As a result, although pelvic echinococcal cysts rarely occur, the gynecologists should consider the possibility of a hydatid cyst when they find a pelvic cystic mass, especially in areas where the disease is endemic. The diagnosis should be done with great care to avoid misin-

terpretation. If hydatid cyst was not diagnosed before operation, medical treatment should follow the surgery.

References

1. Basgul A, Kavak ZN, Gokaslan H, Kullu S. Hydatid cyst of the uterus. *Infec Dis Obstet Gynecol* 2002;10:67-70.
2. Abu-Eshy SA. Some rare presentations of hydatid cyst (*Echinococcus granulosus*). *J R Coll Surg Edinb* 1998;43:347-52.
3. Saidi F. Treatment of echinococcus cyst. In: Nyhus L, Baker RJ, Fischer JE, (eds), *Mastery of Surgery*. Little Brown, 1997;1035-53.
4. Rahman MS, Rahman J, Lysikiewicz ZA. Obstetrics and gynecological presentations of hydatid disease. *Br J Obstet Gynecol* 1982;89:665-70.
5. Pekindil G, Tenekeci N. Solid appearing Pelvic hydatid cyst; transabdominal and transvaginal sonographic diagnosis. *Ultrasound Obstet Gynecol* 1997;9:289-91.
6. Diaz-Recasens J, Garcia-Enguidanos A, Manoz I, Sainz de la cuesta R. Ultrasonographic appearance of an echinococcus ovarian cyst. *Obstet Gynecol* 1998; 91: 841-2.
7. Tampakoudis P, Assimakopoulos E, Zafrakas M, T Zeveletis P, Kostopoulon E, Bontis J. Pelvic echinococcus mimicking multicystic ovary. *Ultrasound Obstet Gynecol* 2002; 2:196-8.
8. Kune GA, Morris DI. Hydatid disease In: Schwasyz & Ellis. *Mingot's abdominal operations*, 9th edn. Appleton & lauge, 1989:1225-40.
9. Bekhti A, Shaapi JP, Lpron M, Dessaint JP, Santoro F, Capren A. Treatment of hepatic hydatid disease with mebendazol: preliminary results in four cases. *BMJ* 1997;1074-81.