

An unusual, giant and benign condyloma acuminatum lesion on the genital area for more than a decade

Soheila Aminimoghaddam¹, Mohammad Hossein Badakhsh², Farrokh Taftachi³,
Forough Nejadisalami⁴, Fatemeh Mahmoudzadeh⁵

Received: 19 June 2013

Accepted: 22 October 2013

Published: 13 July 2014

Abstract

Condyloma acuminatum, is a rare sexually transmitted disease. The virus responsible for condyloma is human papillomavirus. HPV-6 and HPV-11 are the most commonly detected HPV genotypes, but at least 20 other HPV genotypes have occasionally been found in genital wart tissue specimens. In fact genital HPV infection is common among sexually active populations. This disease may occur at any age after puberty and always seen in the mucosal area. It is characterized by slow growth. We reported here a case of a 42-year-old female patient with a 12 year history of a condyloma acuminatum lesion in her genitalia area without any medical treatment.

Keywords: Genital wart, Condyloma acuminatum, Human papilloma virus, Typing.

Cite this article as: Aminimoghaddam S, Badakhsh M.H, Taftachi F, Nejadisalami F, Mahmoudzadeh F. An unusual, giant and benign condyloma acuminatum lesion on the genital area for more than a decade. *Med J Islam Repub Iran* 2014 (13 July). Vol. 28:55.

Introduction

Genital warts or Condylomata acuminatum is a highly contagious sexually transmitted disease caused by wide variety of sub-types of human papillomavirus (HPV) (i.e. types 6 and 11 are responsible for 90% of genital warts) (1). It spreads through direct skin-to-skin contact during oral, genital, or anal sex with an infected partner (2). The prevalence of HPV has been observed at 27% of all sexually active people, with an increase of up to 45% between the ages of 14 and 33 but in overall 1% of the adult population are affected by condyloma acuminatum (3,4). Condyloma acuminatum lesions characterized as cauliflowerlike masses of tissues that can be found on the urethra, penis, female genitalia, perianal area, or rectum (5). The lesions are typically limited to a few centimeters in diameter at the time of presentation. We report the

case of a 42-year-old female with a 12 year history of a rather large wart.

Case Report

A 42-year-old woman came to oncology outpatient department complaining of extensive lesion in the genital part of the body for more than 12 years ago. She has 3 sons which all born by vaginal delivery. She married at age of twenty-four years and then divorced 12 years later and she did not have a history of extramarital contact. Also she gave a history of smoking for more than 20 years, one pack each day. Her last mense occurred two weeks ago, with the clinical and past medical history within normal limits. The Condyloma size was 25 to 5 cm (Fig.1) and grown for 12 years ago with pain that healed spontaneously without any treatment. During this she had itching and pain in her genitalia region and no

1. (Corresponding author) Gynecologist, Oncologist, Assistant Professor of Medicine, Department of Gynecology, Firoozgar hospital, Iran University of Medical Sciences, Tehran, Iran. dr_aminimoghaddam@yahoo.com

2. Gynecologist, Associated Professor of Medicine, Department of Gynecology, Firoozgar hospital, Iran University of Medical Sciences, Tehran, Iran. M_H_Badakhsh@yahoo.com.

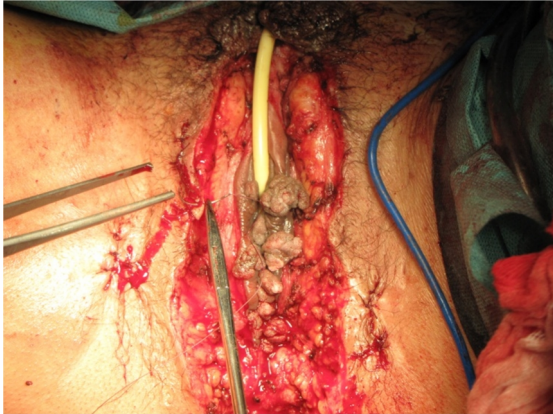
3. Forensic expert, Associated Professor of Medicine, Shahid Beheshti University of Medical Sciences, Tehran, Iran. ftaftachi@yahoo.com.

4. MD, resident of Gynecology, Department of Gynecology Firoozgar hospital, Iran University of Medical Sciences, Tehran, Iran. fnsalami@yahoo.com.

5. Medical student, Mazandaran University of MedicalS, Sari, Iran. fa_mahmoudzadeh@yahoo.com

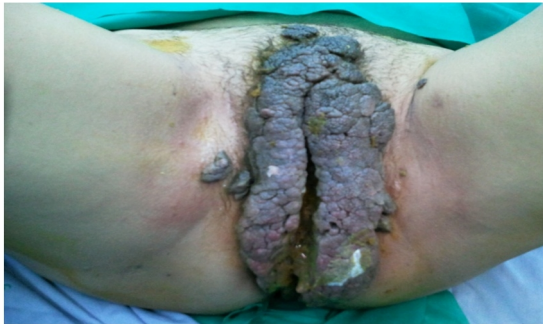

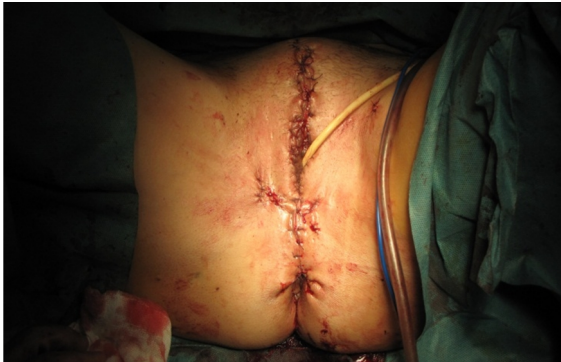Fig.1. Condyloma acuminatum lesion on the genital area



A



B

Fig. 2. Clinical resolution after surgical incision

treatment was applied. No other lesions were seen in other part of the body. Pathologic examination of lesions showed koilocytic changes that is pathognomic of HPV infection in specimen. The detection of epithelial acanthosis with atypical koilocytosis on histological examination, as well as the finding of human papillomavirus genotype 6 by in situ DNA hybridization, confirmed the diagnosis of condyloma acuminatum. Routine serological testing for other sexually transmitted infections, including human immunodeficiency virus, yielded negative results. After obtaining signed informed consent, wide local excision was done

(Fig.2). Follow-up visits occurred 15 days and 1, 3, 6, and 12 months after treatment; no relapses were registered.

Discussion

Condylomata acuminatum are caused by infection with the human papilloma virus. Most warts are caused by human papilloma virus genotype 6 or 11 (2). Genital condylomata are commonly transmitted by sexual contact. Risk factors for HPV transmission are: multiple sexual partners, prostitution, homosexuality, lack of hygiene, and chronic genital infections. It seems the most important risk factors in this patient are lack of hygiene and heavy smoking.

Condylomata acuminatum lesions may sometimes be localized on extragenital mucous membranes, such as lingual, anus, axilla and some other mucous membranes (6), but this case had no lesions in the other parts of her body.

We describe here the first case, to our knowledge, of condyloma acuminatum with giant lesions with no sign of neoplasia or dysplasia in the tissue for more than 12-year without any treatment. Lesions were treated by local excision. It seems that condyloma acuminatum might growth with no dysplasia and neoplasia if they were not treated.

Reference

1. Daneshpouy M, Socie G, Clavel C, et al. Human papilloma virus infection and anogenital condyloma in bone marrow transplant recipients. *Transplantation J.* 2001; 71:167-9.
2. Jamshidi mahin, et al. The impact of human papilloma virus (HPV) types 6, 11 in women with genital warts. *Arch Gynecol Obstet J.* 2012 Nov; 286(5):1261-7.
3. Lynde C, et al. Clinical features of external genital warts. *J Cutan Med Surg.* 2013 Dec; 17 Suppl 2:S55-60.
4. Patel H, et al. Systematic review of the incidence and prevalence of genital warts. *BMC Infect Dis.* 2013 Jan 25; 13:39. doi: 10.1186/1471-2334-13-39.
5. Uth Ovesen A. Perianal Buschke-Löwenstein tumour. *Ugeskr Laeger.* 2012 Jun 4; 174(23):1616-7.
6. Ljubojevic S, Skerlev M. HPV-associated diseases. *Clin Dermatol.* 2014 Mar- Apr; 32(2):227-34.