

## Instrumented transforaminal lumbar interbody fusion in surgical treatment of recurrent disc herniation

Farzad Omid-Kashani<sup>1</sup>, Ebrahim Ghayem Hasankhani<sup>2</sup>, Hamid Reza Noroozi<sup>3</sup>

Received: 15 April 2014

Accepted: 8 July 2014

Published: 1 November 2014

### Abstract

**Background:** The incidence of recurrence in patients undergoing primary discectomy due to lumbar disc herniation (LDH), is regularly reported as 5-15%. In this study we aimed to evaluate surgical outcome of instrumented transforaminal lumbar interbody fusion (TLIF) in the patients suffering from recurrent LDH.

**Methods:** We retrospectively studied 51 patients (30 female, 21 male) from August 2007 to October 2011. The mean age and follow-up of the patients was 46.4±14.8 (ranged; 29-77 years old) and 31.4±6.8 (ranged; 25-50 months), respectively. Clinical improvement was assessed by Oswestry Disability Index (ODI), visual analogue scale (VAS), and subjective satisfaction rate, while fusion was appraised radiologically. Data analysis was by one sample Kolmogorov-Smirnov, paired t, and Mann-Whitney tests.

**Results:** Surgery could significantly improve mean leg and lumbar VAS and ODI from preoperative 7.4±2.5, 7.8±3.1, and 72.1±21.5 to postoperative 3.4±3.6, 3.5±2.6, and 27.5±18.0, respectively at the last follow-up visit. Subjective satisfaction rate was excellent in 24 patients (47.1%), good in 14 (27.5%), fair 11 (21.6%), and poor in two (3.9%). We had one patient with iatrogenic partial L5 nerve root injury and one with unknown late onset refractory postoperative back pain. Fusion rate was 100% and instrument failure was nil.

**Conclusion:** In surgical treatment of the patients with recurrent LDH, bilaterally instrumented TLIF is a relatively safe and effective procedure and can be associated with least instrument failure and highest fusion rate while no postoperative bracing is also needed.

**Keywords:** Transforaminal lumbar interbody fusion, Recurrent disc herniation, Treatment outcome.

*Cite this article as:* Omid-Kashani F, Ghayem Hasankhani E, Noroozi H.R. Instrumented transforaminal lumbar interbody fusion in surgical treatment of recurrent disc herniation. *Med J Islam Repub Iran* 2014 (1 November). Vol. 28:124.

### Introduction

About 10% of patients with Low Back Pain (LBP) have sciatica (1, 2). Simple discectomy is the most prevalent surgery performed on the lumbar spine throughout the world (3). Literature reveals that in the patients undergoing primary discectomy due to lumbar disc herniation (LDH), leg pain or LBP persist in about 10-30%, but the incidence of real recurrent of LDH usually reported as 5- 15% (4-7).

Several factors are usually quoted as risk factors of recurrence. These include pre-operative minor disc herniation, limited

(versus aggressive) discectomy, increased preoperative disc height and sagittal range of motion, smoking, occupational lifting, and more preoperative disc degeneration (8-11). The factors that are not proven to be effective in creating recurrence comprise herniation volume (as a percentage of intervertebral disk volume), sport activities, and occupational driving (8, 11).

In recurrent LDH, comprehensive pre-operative clinical and paraclinical exams should be carried out to rule out other pathologies like infection, instability, or epidural scar (12). A variety of surgical tech-

1. (Corresponding author) Associate Professor of Orthopedic Surgery, Orthopedic Department, Orthopedic Research Center, Imam Reza Hospital, Mashhad University of Medical Sciences, Mashhad, Iran. [omidif@mums.ac.ir](mailto:omidif@mums.ac.ir)

2. Professor of Orthopedic Surgery, Orthopedic Department, Orthopedic Research Center, Imam Reza Hospital, Mashhad University of Medical Sciences, Mashhad, Iran. [hasankhanie@mums.ac.ir](mailto:hasankhanie@mums.ac.ir)

3. Orthopedic Resident, Orthopedic Department, Orthopedic Research Center, Imam Reza Hospital, Mashhad University of Medical Sciences, Mashhad, Iran. [noroozi\\_hr@yahoo.com](mailto:noroozi_hr@yahoo.com)

niques have been proposed for the treatment of recurrent LDH including aggressive medical management, minimally invasive discectomy, open conventional discectomy alone, or discectomy with instrumented fusion (12). As the number of back surgeries increases the probability of worse outcome also increases, some authors suggested that in recurrent LDH surgery, lumbar interbody fusion associated with aggressive discectomy and stabilization might be more effective in reducing the subsequent recurrences (9). One of these surgical procedures is transforaminal lumbar interbody fusion (TLIF) that is usually augmented with pedicular screws and rods. In this study we aimed to evaluate surgical outcome of instrumented TLIF in patients suffering from recurrent LDH.

### Methods

After Institutional Review Board approval (Code No 901032), we retrospectively studied the patients undergone instrumented TLIF due to recurrent LDH in our orthopedic department from August 2007 to October 2011. Many of these cases had been primarily operated by other neurosurgeons or orthopedic surgeons and then, referred to our center for revision surgery. Our inclusion criteria comprised the patients with recurrent LDH at the same level (Fig.1) associated with debilitating complains refractory to more than six weeks aggressive conservative treatment or iatrogenic instability (rotation > 10-15 ° or slip > 4-5<sup>mm</sup> in dynamic flexion extension views). Conservative treatment comprised physiotherapy, hydrotherapy, a variety of anti-inflammatory, analgesic, and antidepressant drugs, besides some modifications in patient's life style. In no cases epidural transforaminal injection was tried. We excluded those patients with less than two years follow-up, a history of infection or malignancy in affected segment, severe osteoporosis preventing any instrumentation, significant associated psychological disorders, and major underlying diseases like uncontrolled diabetes mellitus, uncorrectable coagulopa-

thies, systemic infection, and etcetera.

The informed consent was obtained after the patient was informed of the pros and cons of the surgery. Preoperatively, we had evaluated the patients with a comprehensive history and physical examination. The severity of disability and pain were assessed by Oswestry Disability Index (ODI, version 2.1) and visual analogue scale (VAS) (13, 14). The ODI has already been translated and validated in Persian speaking patients (15). To complete the pain questionnaire, patient specified the pain intensity on a ruler scaled from 0 to 10.

**Surgical Technique:** After prone position-

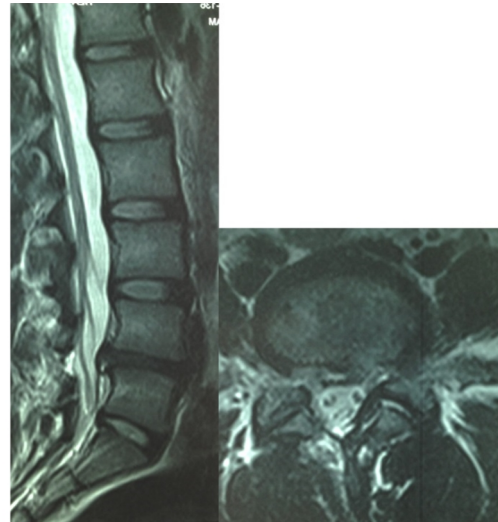


Fig. 1. A 35 years old female with recurrent right LDH. She was operated by simple discectomy performed seven years ago.

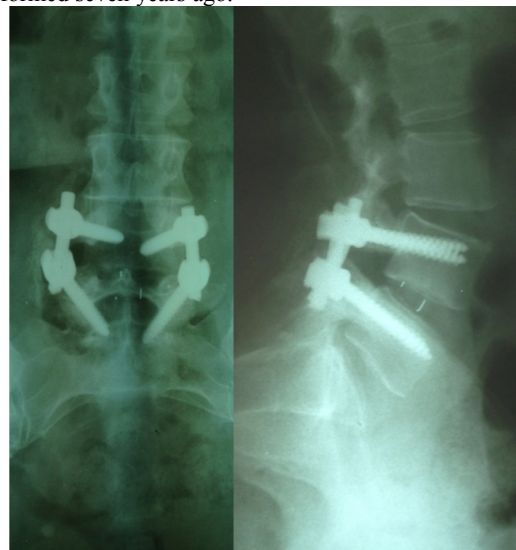

Fig. 2. Postoperative radiographs of the patient shown in Fig 1. Note that instrumented TLIF restored both intervertebral height and lumbar lordosis.

ing of the patient on the radiolucent operating table, midline incision, paravertebral muscles retraction and scar tissue resection were carried out. We did not enter the scar tissue itself; instead we released and decompressed it from the periphery. Facet joint on the affected side and then intervertebral disc were completely excised. In the presence of bilateral complains the same procedure was also carried out on the opposite side. After completion of the neural decompression, posterolateral fusion was achieved with local bone graft and match-stick allograft (on each side, 5 pieces  $5 \times 5 \times 35$  millimeters of freeze dried corticocancellous bone, Tissue Regeneration Corporation; TRC, Kish, Iran). Then, bilateral pedicular screws were inserted by free hand technique and temporary distraction was applied. After the intervertebral space was prepared, an appropriately sized banana-shape intervertebral implant (TLIF cage; Stryker AVS TL PEEK Spacer Implant) filled with local autogenous bone graft was inserted under fluoroscopic control through the intervertebral foramen. After that, distraction force between the screws was replaced with compression force to create intersegmental lordosis (Fig. 2).

**Postoperative Protocol:** As the procedure has an inherent vigorous stability, we did not routinely use any postoperative bracing. After the surgery, as soon as the patient was able to walk and void normally, he or she was discharged from the hospital. After

discharge, the patients were followed up at one, three, six months and then annually to assess radiologic and clinical improvement. At the latest follow-up visit, patient satisfaction rate was also evaluated according to Henderson questionnaire (16). This questionnaire categorized the patient satisfaction rate into four groups; excellent, good, fair, and poor.

Routinely, we did not use computerized tomography to confirm osseous union. Instead, we relied on observing the bony bridge between the two adjacent endplates (through the cage anteriorly) or transverse processes posteriorly on plain anteroposterior and Ferguson views of the lumbosacral areas (17). All remarkable intra- and post-operative complications were also reviewed and assessed.

#### Statistical Analysis

We used statistical package for the social sciences (SPSS), version 11.5 and considered  $p < 0.05$  as significant. We also used one sample Kolmogorov-Smirnov, paired t, and Mann-Whitney tests to analyze the data.

#### Results

We initially studied 56 patients with recurrent lumbar disc herniation who had undergone instrumented TLIF in our orthopedic department from August 2007 to October 2011. Later and throughout the follow-up, we were unable to track five cases and

Table 1. Improvement in pain and disability

Indices	Preoperative	Last Visit	t	p value
Mean VAS* leg	7.4±2.5	3.4±3.6	4.367	<0.001
Mean VAS lumbar	7.8±3.1	3.5±2.6	5.923	<0.001
Mean ODI*†	72.1±21.5	27.5±18.0	6.409	<0.001

\* VAS = Visual Analogue Scale, † ODI = Oswestry Disability Index

Table 2. Postoperative patients' satisfaction

Patient Satisfaction	Frequency	Percent
Excellent	24	47.1
Good	14	27.5
Fair	11	21.6
Poor	2	3.9

finally, 51 patients (30 female, 21 male) remained for evaluation. Levels of recurrent LDH included L3-L4 (four cases; three at right and one at left side), L4-L5 (25 cases; 14 right and 11 left), and L5-S1 (22 cases; 10 right and 12 left). Recurrences occurred at the same level same side in 42 cases (82.4%) and at the same level contralateral side in 9 (17.6%). The mean age and BMI of the patient was  $46.4 \pm 14.8$  (ranged; 29-77 years old and  $24.6 \pm 18.4$  (ranged; 16.4-37.3), respectively. The mean follow-up period in our patients was also  $31.4 \pm 6.8$  (ranged; 25-50 months). Surgery induced changes in leg and lumbar VAS and ODI are shown in Table 1. Postoperative indices were calculated at the last follow-up visits.

Subjective satisfaction rate are shown in Table 2. From the two patients with poor outcome, one developed refractory LBP six months postoperation. We could not find a reason for her pain, while no recurrent or adjacent stenosis or arthrosis was discovered in lumbar area. At the last follow-up visit (41 months later), she still complained of annoying LBP. The latter patient had an iatrogenic partial L5 nerve root injury (during cage passage) presented by drop foot. He denied to be operated by anterior transfer of tibialis posterior tendon. This case belonged to the first cases of our study and after that, we learned to use two fine nerve retractors (for both nerve roots) during intervertebral disc space preparation and cage insertion and thereafter, there was never a case with neural complication.

We also had three patients with superficial wound infection, all healed by local wound care and antibiotic therapy. No case with instrument failure (screw breakage, implant dislodgment or loosening) was found during this follow-up period. Solid fusion was happened in all cases including poor outcome cases. According to Mann-Whitney and independent samples t- tests, no significant difference existed between male and female patients regarding to satisfaction rate, disability improvement, or pain relief.

## Discussion

In this study we could evaluate the surgical outcome of instrumented TLIF in 51 patients with recurrent LDH in a reasonable follow-up period. According to our findings, this method made a remarkable improvement in pain and disability while was also not associated with significant complications. Proponents of TLIF believe that this technique not only completely excises the disc as a source of pain and recurrence but also achieves 360 degrees spinal fusion. In comparison with posterior LIF (PLIF), this technique has been noted to be associated with shorter operative time, less blood loss, and due to avoidance of excessive retraction on the roots during intervertebral disc space preparation and cage insertion, lesser complication have been reported; although this comparison was not carried out on the patients with recurrent LDH (18).

Acharya et al in a retrospective study evaluated the surgical outcomes of simple lumbar discectomy in both primary and revision cases with disc herniation in their institute for a period of three years (19). They defined recurrence as same level same side re-herniation. They had 259 primary and 14 revision cases and followed them up for more than one year. They reported a satisfactory outcome in 96.5% and 78.6% of the primary and revision surgeries, respectively, while complication rate was 3.5% and 21.43%. In comparison with our study, although the assessment tools for subjective patient satisfaction and mean follow-up periods in these two studies were different, satisfactory outcomes were similar (78.6% versus 74.6% that was the sum of excellent and good results in our study). They had no cases with intraoperative nerve root injury or postoperative infection in their revision cases.

TLIF procedure is usually carried out with single cage implanted centrally through the intervertebral space. Zhou et al in 2011 reported the surgical outcomes of this procedure on 76 cases (45 with degenerative disc disease, 23 with spondylolisthesis, and only

eight patients with recurrent LDH) (20). They routinely used both plain radiography and two-dimensional computed tomography reconstruction to assess the fusion status. Similar to our study, clinical outcomes were assessed by ODI and VAS, but unlike our study, they did not have any case with nerve injury during the surgery. Not all of their follow-up periods were over 24 months but throughout this time, they observed significant improvement in pain and disability, a fusion rate of 100% and no cases with instrument failure. These authors finally concluded that TLIF procedure is a harmless and successful technique for the management of degenerative diseases of the lumbar spine.

Chen and co-authors in 2009 reported their results on 43 patients with recurrent LDH treated by TLIF (21). The average age and follow-up period of their patients were 54.2 years and 45 months, respectively. Unlike our study, they evaluated the patients with Japanese Orthopedic Association (JOA) score system. The mean JOA score in their patients improved from 9.3 preoperatively to 25.0 at the last follow-up visit ( $p < 0.0001$ ). They reported excellent clinical outcome in 53.5%, good in 32.6%, and fair in 13.9%, while we had two cases (3.9%) with poor clinical outcome. No major complications were occurred in their study. Similar to our study, they also observed 100% fusion rate in their patients. Eventually, these authors proposed TLIF as an effective technique for surgical treatment of recurrent LDH.

Yung et al. in another retrospective study evaluated the outcomes of minimally invasive TLIF in three groups of patients involved by low grade spondylolytic spondylolisthesis, degenerative spondylolisthesis, and degenerative segmental instability, respectively (22). Like our study, they used VAS and ODI for clinical evaluation. In all the groups, the rate of pain and disability improvement, complications, and solid fusion were comparable and acceptable. They concluded that these diseases are among the ideal surgical indications for

minimally invasive TLIF. They did not consider recurrent LDH in their study. In a more advanced and delicate study with less invasive dissection, Mao evaluated the practicability of minimally invasive unilateral TLIF (unilateral incision through working channel) associated with unilateral pedicular screws and a translaminar facet screw into the contralateral facet joint through the same incision (23). The author carried out this procedure on 16 patients with recurrent LDH and evaluated the clinical and radiologic outcomes. The average operating time and blood loss was  $148 \pm 75$  minutes and  $186 \pm 226$  milliliters, respectively and they had no case with neural complication. They reported remarkable improvement in VAS and ODI with this minimally invasive technique and proposed this hybrid fixation for the patient with recurrent LDH due to its cosmetic appearance, less invasion, less blood loss, and quicker recovery.

Our study had some noteworthy strengths and weaknesses. The number of patients and duration of follow-up were the strengths of this study, but following limitations can be mentioned. The design was retrospective and inevitably, the limitations of a retrospective study are also applied to ours. We also did not use any minimally invasive or innovative technique, but we believe that TLIF procedure is still new and a long way remains to its ultimate perfection. We propose that a randomized clinical trial study should be carried out in the future to compare surgical outcome of preferably minimally invasive instrumented TLIF versus PLIF in only the patients with recurrent LDH to determine the preferred approach in these especial group.

### Conclusion

Based on this study we concluded that in surgical treatment of the patients with recurrent LDH, bilaterally instrumented TLIF is a relatively safe and effective procedure and associated with least instrument failure and highest fusion rate while no postoperative bracing is needed.

### Acknowledgments

The authors thank Student Research Committee, Faculty of Medicine, Mashhad University of Medical Sciences for its financial support. This paper is based on an orthopedic residency's thesis pertaining to Dr HR Noroozi.

### Conflict of interest

The authors declare that they have no conflict of interest.

### References

- Hagen KB, Hilde G, Jamtvedt G, Winnem M. WITHDRAWN: Bed rest for acute low-back pain and sciatica. *Cochrane Database Syst Rev.* 2010; (6):CD001254. doi: 10.1002/14651858.CD001254.pub3. Review.
- Koes BW, van Tulder MW, Peul WC. Diagnosis and treatment of sciatica. *BMJ.* 2007; 334(7607): 1313-7.
- Mehrotra A, Sloss EM, Hussey PS, Adams JL, Lovejoy S, SooHoo NF. Evaluation of a center of excellence program for spine surgery. *Med Care.* 2013; 51(8): 748-57.
- Shin BJ. Risk Factors for Recurrent Lumbar Disc Herniations. *Asian Spine J.* 2014; 8(2): 211-215.
- Carragee EJ, Spinnickie AO, Alamin TF, Paragioudakis S. A prospective controlled study of limited versus subtotal posterior discectomy: Short-term outcomes in patients with herniated lumbar intervertebral discs and large posterior anular defect. *Spine.* 2006; 31(6):653-7.
- Kleinig TJ, Brophy BP, Maher CG. Practical neurology - 3: Back pain and leg weakness. *Med J Aust.* 2011; 195(8): 454-7.
- Swartz KR, Trost GR. Recurrent lumbar disc herniation. *Neurosurg Focus.* 2003; 15(3): E10.
- Dora C, Schmid MR, Elfering A, Zanetti M, Holdler J, Boos N. Lumbar disk herniation: do MR imaging findings predict recurrence after surgical discectomy? *Radiology.* 2005; 235(2): 562-7.
- McGirt MJ, Ambrossi GL, Dato G, Sciubba DM, Witham TF, Wolinsky JP, et al. Recurrent disc herniation and long-term back pain after primary lumbar discectomy: review of outcomes reported for limited versus aggressive disc removal. *Neurosurgery.* 2009; 64(2): 338-44; discussion 344-5.
- Kim KT, Park SW, Kim YB. Disc height and segmental motion as risk factors for recurrent lumbar disc herniation. *Spine.* 2009; 34(24): 2674-8.
- Miwa S, Yokogawa A, Kobayashi T, Nishimura T, Igarashi K, Inatani H, et al. Risk Factors of Recurrent Lumbar Disc Herniation: A Single Center Study and Review of the Literature. *J Spinal Disord Tech.* 2013 Nov 8. [Epub ahead of print]
- Lee JK, Amorosa L, Cho SK, Weidenbaum M, Kim Y. Recurrent lumbar disk herniation. *J Am Acad Orthop Surg.* 2010; 18(6): 327-37.
- Wewers ME, Lowe NK. A critical review of visual analogue scales in the measurement of clinical phenomena. *Res Nurs Health.* 1990; 13(4): 227-36.
- Fairbank JC, Pynsent PB. The Oswestry Disability Index. *Spine.* 2000; 25(22): 2940-52.
- Mousavi SJ, Parnianpour M, Mehdian H, Montazeri A, Mobini B. The Oswestry Disability Index, the Roland-Morris Disability Questionnaire, and the Quebec Back Pain Disability Scale: translation and validation studies of the Iranian versions. *Spine.* 2006; 31(14): E454-9.
- Henderson ED. Results of the surgical treatment of spondylolisthesis. *J Bone J Surg Am* 1966; 48(4): 619-42.
- Whitley AS, Sloane C, Hoadley G, Moore AD, Alsop CW. Clark's positioning in radiography. 12<sup>th</sup> ed. Hodder Arnold, London, 2005: 139.
- Takeb N, Ahsan K. Comparison of the early results of transforaminal lumbar interbody fusion and posterior lumbar interbody fusion in symptomatic lumbar instability. *Indian J Orthop.* 2013; 47(3): 255-63.
- Acharya KN, Nathan TS, Kumar JR, Menon KV. Primary and revision lumbar discectomy: a three-year review from one center. *Indian J Orthop.* 2008; 42(2): 178-81.
- Zhou J, Wang B, Dong J, Li X, Zhou X, Fang T, et al. Instrumented transforaminal lumbar interbody fusion with single cage for the treatment of degenerative lumbar disease. *Arch Orthop Trauma Surg.* 2011; 131(9):1239-45.
- Chen Z, Zhao J, Liu A, Yuan J, Li Z. Surgical treatment of recurrent lumbar disc herniation by transforaminal lumbar interbody fusion. *Int Orthop.* 2009; 33(1): 197-201.
- Park Y, Ha JW, Lee YT, Oh HC, Yoo JH, Kim HB. Surgical outcomes of minimally invasive transforaminal lumbar interbody fusion for the treatment of spondylolisthesis and degenerative segmental instability. *Asian Spine J.* 2011; 5(4): 228-36.
- Mao KY, Wang Y, Xiao SH, Zhang YG, Liu BW, Wang Z, et al. A feasibility research of minimally invasive transforaminal lumbar interbody fusion (MIS-TLIF) using hybrid internal fixation for recurrent lumbar disc herniation. *Zhonghua Wai Ke Za Zhi.* 2013; 51(8): 723-7.