

Early detection of renal scarring in children with suspected pyelonephritis: Comparison of diuretic MAG3 scintigraphy (F0) and DMSA Scan

H. Otukesh, MD.¹, SM. Fereshtehnejad², V. Amir Jalali, MD.³, R. Hoseini, MD.⁴,
A. Bordbar, MD.⁵, N. Najimi⁶, and A. Tabarroki, MD.⁷

Department of Pediatrics, Labafi-Nejad Hospital, Iran University of Medical Sciences, Tehran. Iran.

Abstract

Background: Screening for patients at risk of renal scarring is a challenge in children with acute pyelonephritis (APN). Diuretic Tc-99m mercaptoacetyltriglycine (MAG3) scintigraphy with zero time injection of furosemide (MAG3-F0) was observed to display focal parenchymal disorders. The advantages of MAG3 include: lower radiation dose and short duration of the test. The aim of this study was to compare the role of Tc-MAG3 (F0) dynamic study and Tc-99m dimercaptosuccinic acid (DMSA) scan in early detection of renal scarring of children with suspected pyelonephritis in comparison to after-6-month Tc-DMSA scan as gold standard.

Methods: 28 patients (56 renal units) with their first urinary tract infection (UTI) episode were evaluated prospectively for renal scarring with radioisotope scan. The patients were divided into 2 groups: Group A consisted of patients who underwent MAG3 scintigraphy in acute phase of pyelonephritis and Group B consisted of patients who underwent DMSA scan in this phase for renal cortical assessment. Follow up DMSA scan was performed for all patients in both groups 4-6 months after UTI episode.

Results: The accuracy of MAG3-F0 scintigraphy and DMSA scan in detecting parenchymal changes in acute pyelonephritic phase were 89.3% and 96.4%, respectively. Positive predictive value (PPV) of both MAG3-F0 and DMSA was 100%. Whereas, negative predictive values (NPV) of MAG3-F0 and DMSA scan were 62.5% and 75%, respectively.

Conclusion: Conclusively, if the MAG3 parenchymal image is abnormal, then there is renal damage but if this image is normal, a focal defect has not been excluded. Thus an abnormal MAG3-F0 precludes the need for a Tc-DMSA scan for detection of persistent renal damage in acute phase of pyelonephritis.

Keywords: acute pyelonephritis, scar, dimercaptosuccinic acid (DMSA), mercaptoacetyltriglycine (MAG3)

Introduction

The clinical and laboratory classification of a

urinary tract infection (UTI) as lower versus upper remains controversial, mainly because of the lack of clinical and paraclinical findings particularly early in childhood, when UTIs are

1. Pediatric Nephrologist, Iran University of Medical Sciences and Health Services, Labafi Nejad Hospital, Tehran, Iran.

2. **Corresponding author**, medical student, Iran University of Medical Sciences, Tel: +98 21 22704696, Cell phone: +98 9125207595, email: sm_fereshtehnejad@yahoo.com

3. Nuclear physician, Shahid Beheshti University of Medical Sciences, Labafi-Nejad Hospital, Tehran, Iran.

4&5. Pediatrician, Iran University of Medical Sciences, Labafi-Nejad Hospital, Tehran, Iran.

6. Medical Student, Iran University of Medical Sciences and Health Services, Tehran, Iran.

7. General Practitioner.

relatively common [1]. However, children with pyelonephritis are at risk for renal damage and it has been established that acute infections of renal parenchyma lead to scarring which is often associated with complications [1,2].

Acute pyelonephritis (APN) can lead to irreversible changes within the renal parenchyma and alteration of renal function [3]. Renal scars after first pyelonephritis are in most cases not associated with abnormalities of the urinary tract, but are caused by the infection itself [2].

The pathophysiologic changes in acute pyelonephritis include tubulointerstitial inflammation/pus with impairment of the renal microcirculation due to compression of the glomeruli, small peritubular capillaries and vasa recta by interstitial edema [4]. Acute pyelonephritis in children can leave a kidney scar that eventually can lead to hypertension or renal failure [5].

Therefore, screening for patients at risk is a major challenge. Nowadays, nuclear medicine (using radioactive isotopes) is applied more frequently in the diagnosis and treatment of patients [6]. The main tool of radionuclide techniques applied to pediatric uro-nephrology is the quantitation of function, which is an information not easily obtained by other diagnostic modalities. The radiation burden is low. Drug sedation is only rarely needed, whatever the age of the patient [7].

Renal parenchymal (cortical) scintigraphy is indicated for the diagnosis and follow-up of focal functional disorders, such as acute pyelonephritis, and for accurate quantitation of split renal function, especially in cases of atypical location of the kidney(s) [8]. Tc-labeled cortical fixation agents have excellent sensitivity in the diagnosis of pyelonephritis. Tc-99m dimercaptosuccinic acid (DMSA) scintigraphy is an accurate method for evaluation of regional cortical impairment during acute pyelonephritis and later on, for detection of permanent scarring [7]. It is extracted by tubular cells and is the best available radiopharmaceutical for the scinti-

graphic evaluation of pyelonephritis because of high kidney to background ratio, and lack of liver and bowel activity [1,6].

On the other hand, Tc-99m mercaptoacetyl-triglycine (MAG3) is predominantly a proximal tubular secretion agent that is indicated for dynamic renal studies to evaluate the tubular function and collecting system drainage and is the agent of choice for obstructive uropathy. MAG3 accumulates rapidly in the cortex during the first few minutes after injection. Thus, MAG3 provides images with a sufficiently high kidney to background ratio and acceptable resolution at 2-4 minutes after injection, and therefore has been considered in the evaluation of focal parenchymal disorders [9,10].

Tc-99m MAG3 renography is nowadays a well-standardized method for accurate estimation of the split renal function and of renal drainage with or without furosemide challenge [7].

Reports about the use of MAG3 in acute pyelonephritis are conflicting because some authors found MAG3 equivalent to DMSA [2], whereas others found it inferior [10].

However, in those studies MAG3 was used without the benefit of a diuretic, and investigation of the renal parenchyma was focused on the first 2-3 min after injection.

Sfakianakis et al showed that using a diuretic simultaneously with MAG3 (furosemide at zero time or F0) produces prompt diuresis which eliminates physiologic urine activity from the calyces and renal pelvis. Thus, findings in the renal parenchyma (cortex) which occur at more than 10 min after injection can become prominent and easily recognized [11].

The aim of this study was to compare diagnostic values of Tc-MAG3 (F0) dynamic study and DMSA scan -during acute phase- in early detection of renal scarring of children with suspected pyelonephritis in comparison to after-6-month Tc-DMSA scan as a gold standard.

Methods

Patients

28 patients were evaluated prospectively (56 renal units) with their first UTI episode for parenchymal changes with radioisotope scan. They were admitted to Aliasghar children's hospital, Tehran, Iran.

Each patient with a strong clinical and laboratory suggestion of UTI episode included high fever ($>38^{\circ}\text{C}$), urinary symptoms (dysuria, frequency, urinary incontinence associated with urgency and bedwetting in a previously dry child) and abdominal pain in whom acute pyelonephritis was suspected, underwent routine blood tests, urinalysis and culture. Patients with previous history of UTI, Congenital urinary tract malformations, or autoimmune diseases were excluded by their history, search of medical records and previous imaging.

Assessment

This study was approved by the institutional research board. All patients began receiving intravenous antibiotics (cefotaxime and in newborns ampicillin) on admission. The gold standard for diagnosis of UTI is growth of pathogenic bacteria in a urine culture [12].

Its findings were considered positive when they showed a single urinary tract pathogen in any concentration in urine obtained by suprapubic tap or greater than 10^3 colony-forming units/ml if the urine was obtained by catheter. Therefore, when the result of urine culture was positive (24-48 hours after admission), a diuretic MAG3 or DMSA scan was performed. The imaging studies were completed with a cystogram once the repeated urine culture was negative for pathogen. The patients were divided into 2 groups using simple random method: Group A consisted of 14 patients (28 renal units) who underwent MAG3-F0 scintigraphy in acute phase of pyelonephritis and Group B consisted of 14 patients (28 renal units) who underwent DMSA

scan in this phase for renal cortical assessment. Follow-up-DMSA scan was performed as gold standard for all patients in both groups 4-6 months after UTI episode to detect renal scars. All patients received prophylactic antibiotic during this period. They did not have any episode of UTI in this period and it was demonstrated by monthly negative urine cultures. Findings of the first MAG3-F0 scintigraphy and DMSA scan were analyzed and compared with the results of the gold standard test (DMSA scan after 4-6 months).

Imaging protocols

The standard protocol for MAG3-F0 required hydration (oral using 10ml/kg water, milk, or other liquids, or intravenous) but not sedation or bladder catheterization. A 22-min (2 min per image) planar dynamic study was acquired in posterior projection with the patients supine, after an intravenous injection of 37-370 MBq (1-10 mCi) MAG3 and after 1 mg/kg (maximum 40 mg) furosemide was injected immediately after the radiopharmaceutical (at time zero, F0). A postvoiding or postupright holding image at 25-min completed the study. MAG3 studies were reviewed as 2-min sequential planar images.

Planar DMSA imaging was performed 4-6 hours after an intravenous injection of 19-148 MBq (0.5-4.0 mCi) $^{99\text{m}}\text{Tc}$ -DMSA. A pinhole collimator was used for infants, and a high-resolution parallel-hole collimator was used for older children. Posterior and oblique posterior right and left images with 150,000 and 500,000 counts per image were acquired for infants and older children, respectively.

The patients were restricted without sedation in the supine (parallel-hole imaging) or prone (pinhole imaging) position. If the patient moved, the images were repeated.

Additionally, all the images were reviewed and reported by one nuclear physician.

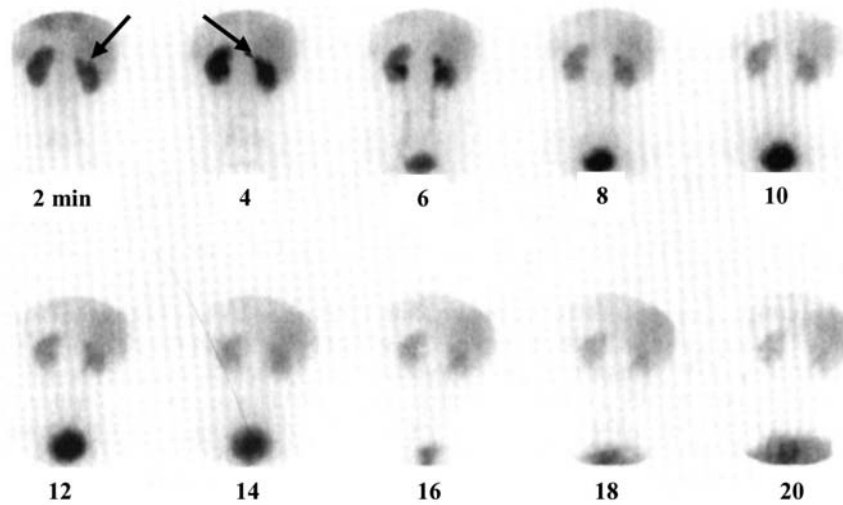


Fig. 1. Parenchymal scar on dynamic MAG3-F0 study. At 2 and 4 min, small focal defect with parenchymal loss is present in upper pole of right kidney (arrow).

Criteria for interpretation

MAG3. Normal MAG3-F0 findings were characterized by normal parenchymal and drainage function. Normal parenchyma rapidly accumulates activity and is visible with high contrast to the background at 2 min. At that time in the mature kidney (>1 mo old), the kidney-

to-background ratio (kidney activity/[kidney+ background activity]) is greater than 80%. Normal split renal function ranges from 45% to 55%. The contour is smooth (except for the shallow indentations around fetal lobulations), and no areas of absent or decreased activity are present, except for the limited-volume regions in the apices and over the drainage system (pelvis). Parenchymal activity peaks at 3-4 min and then declines exponentially under the influence of the diuretic, with the half-life reached

		The result of DMSA after 6 months	
		Scar in kidney (Positive)	Normal kidney (Negative)
The result of MAG3 at baseline	Scar in kidney (Positive)	20	0
	Normal kidney (Negative)	3	5
The result of DMSA at baseline	Scar in kidney (Positive)	24	0
	Normal kidney (Negative)	1	3

Table 1. Comparison of diuretic MAG3-F0 scintigraphy (group A) and DMSA scintigraphy (group B) at baseline with DMSA results after 6 months in children with acute pyelonephritis.

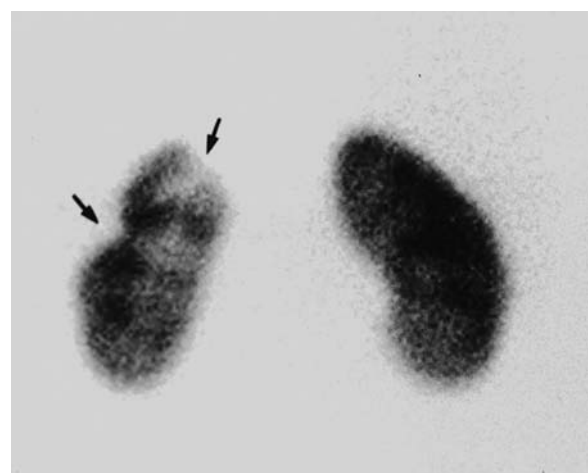


Fig. 2. ^{99m}Tc-DMSA scan (posterior view) in patient with pyelonephritis. Cortical defects (arrows) at upper pole and lateral margin of left kidney indicate scarring.

before 10-12 min, and with residual parenchymal activity at 20 min less than 20% of the peak activity, smoothly distributed, and equal on both sides. Normally, the drainage system appears at 3-5 min and its activity declines exponentially like that of the cortex. At 20 min, the drainage system may not be visible or may show slightly higher activity than does the parenchyma [13].

Parenchymal dysfunction was characterized by relatively decreased or even absent (focal defect) early (2min) uptake and slowed tubular transport (10-20 min), with resultant delayed normalization or even relative retention of MAG3 (Fig. 1).

The parenchymal renogram showed a delay in peak time (>5 min), a flat pattern with a half-life greater than 12 min, and a residual parenchymal activity greater than 20% in the mature kidney; uptake at 2 min was reduced (kidney-to-background ratio < 80%).

The abnormality was transient and focal (regional parenchymal dysfunction), involving 1 or both kidneys with 1 or more foci of abnormality present, or diffuse (diffuse parenchymal dysfunction), involving 1 or both kidneys and the entire parenchyma [13]. The renograms were abnormal focally or throughout the entire parenchyma.

Planar DMSA. Normal findings were equally sized kidneys with 45%-55% relative (split) function and showing a smooth outline without focal defects. A focal defect, or area showing a pronounced decrease or lack of activity, was considered compatible with acute pyelonephritis in the acute phase. A focal defect, regardless

of whether it was associated with perceptible parenchymal loss, was considered to indicate a scar in follow-up studies (Fig. 2).

Statistical Analysis

Diagnostic values of MAG3-F0 scintigraphy and DMSA scan in detection of persistent renal injuries in acute phase of febrile UTI were compared using EPI info-6 software.

Sensitivity, specificity, Positive Predictive Value (PPV), Negative Predictive Value (NPV) of these scintigraphic imaging (DMSA and MAG3-F0) were reported. In addition, as the PPV and NPV of a diagnostic test are dependent of disease prevalence in the original community, PPV and NPV of DMSA and MAG3-F0 were modified using Bayes' rule [14].

The analytical procedures were performed using SPSS v.13 software for windows. In order to compare accuracy of MAG3-F0 dynamic study and DMSA scan, χ^2 test was performed. A 5 percent probability of a type I error (two-tailed), and a power of 80 percent were considered in the analysis. All reported p-values are two-tailed.

Results

Twenty-eight children [22 (78.6%) girls, 6 (21.4%) boys] who had fever and positive urine culture participated in this study during a 6-month period.

They were 12 (85.7%) girls and 2(14.3%) boys in group A (MAG3-F0 group) and 10 (71.4%) girls and 4 (28.6%) boys in group B (DMSA group). The total mean age was 3.43 (SD= 2.62) years ranging from 3 months to 9.5

	Sensitivity (95% CI)	Specificity (95% CI)	Positive Predictive Value (95% CI)	Negative Predictive Value (95% CI)	Accuracy
MAG3-F0	87 (65.3-96.6)	100 (46.3-100)	100 (80-100)	62.5 (25.9-89.8)	89.3
DMSA	96 (77.7-99.8)	100 (31-100)	100 (82.8-100)	75 (21.9-98.7)	96.4

Table 2. Diagnostic values of diuretic MAG3-F0 scintigraphy (group A) and DMSA scintigraphy (group B) in children with acute pyelonephritis.

years, and it was 3.51 (SD=2.90) and 3.29 (SD=2.17) years in groups A and B, respectively.

We assessed 28 renal units in each of these groups. Vesicoureteral reflux (VUR) was reported in 15% of patients in MAG3-F0 group (A), in contrast VUR was not reported in DMSA group (B). The main scintigraphic findings in acute pyelonephritic phase and at 4-6 months after UTI in two groups are shown in Table 1. The accuracy of MAG3-F0 scintigraphy (group A) and DMSA scan (group B) in detecting parenchymal changes in acute pyelonephritic phase were 89.3% (25 out of 28) and 96.4% (27 out of 28), respectively.

The result of Fischer exact test shows that this difference is not statistically significant ($P=0.611$, Power=64.3%).

Diagnostic values of MAG3-F0 scintigraphy and DMSA scan are shown in Table 2. As it is shown in these two tables, specificity and sensitivity of MAG3-F0 scintigraphy were 100% and 87%, respectively. Whereas, specificity and sensitivity of DMSA scan in detecting parenchymal changes in acute pyelonephritic phase were 100% and 96%, respectively.

Calculated PPV and NPV of MAG3-F0 scintigraphy are 100% and 62.5% versus 100% and 75% for DMSA scan. As the prevalence of renal scarring in children with acute pyelonephritis is estimated about 40% in our region [15], PPV and NPV of these imagings are modified as 100% and 92% for MAG3-F0 scintigraphy, versus 100% and 97% for DMSA scan.

Conclusion

Renal scans have been used to evaluate children with UTIs since the 1980s [16], and their sensitivity and specificity for pyelonephritis have been well documented in animal models [17]. A substantial number of defects on DMSA scans occur in the absence of reflux (62 to 82%) [1,18-23]. This has led some to recommend that if renal scarring is to be avoided, a renal scan should be the initial investigation in a child with

UTI to detect those at greatest risk for a persistent scar. However, there is a lack of evidence documenting what the presence of a scar on a renal scan means for a child long-term, although at least one study showed a strong correlation between the absence of nocturnal blood pressure drop (a risk factor for hypertension in adults) and the severity of renal scarring following UTI [24].

Recent studies reporting on investigation during a febrile UTI document initial defect and subsequent scarring in 34 to 70% and 9.5 to 38%, respectively [1,18-23,25]. Unfortunately, many studies do not have complete enough follow-up to determine the true incidence of scarring, as it has been shown that defects will change up to 6 months later [21,26]. There is also the potential for interobserver variability in renal scans, with differences ranging from small to notable [27,28]. The ramifications of renal scarring for the risk of long-term morbidity such as hypertension and renal failure are also unclear. Perhaps the most definite clinical situation is one in which a renal scan is done at the time of an acute UTI and no defect is found; these children appear not to be at risk for further scarring, and omitting further anatomic work-up may be appropriate in this situation [19,29].

High resolution renal parenchymal (cortical) scintigraphy is indicated for the diagnosis and follow-up of focal disorders of the kidneys especially in children. Currently the technique of choice for renal parenchymal scintigraphy is static late imaging after an intravenous injection of a cortical fixation agent, such as DMSA.

MAG3 is primarily a tubular renal imaging agent and is used for dynamic studies in order to assess global renal blood flow and excretory function and to determine drainage adequacy of kidneys. The greatest advantage of MAG3 is the short duration of the test, which requires no waiting period after injection and is acquired after 4 minutes. Immobilization is easier for this short period of time and sedation is not needed.

Pickworth et al showed that Tc-MAG3 (with-

out furosemide injection) is less effective for the detection of focal cortical scarring than Tc-DMSA. But they believed that this advantage was offset partly by the benefits of a lower radiation dose, the additional information concerning drainage and reflux and a much shorter examination time. In addition, Tc-DMSA may underestimate the degree of cortical scarring particularly in instances where there is bilateral global cortical loss and thus equal function. This is less likely to occur with Tc-MAG3 since visualization of the underlying calyces allows a better estimation of cortical thickness and the detection of dilated or obstructed collecting system [30].

Sfakianakis et al performed diuretic MAG3 scintigraphy with zero time injection of furosemide (MAG3-F0) to focal parenchymal decrease in early uptake; slow filling in and prolonged late retention of activity. He and his colleagues performed two retrospective and prospective studies for evaluation of MAG3 scintigraphy in assessment of renal cortex. In the retrospective study, for 36 children with UTI and regional parenchymal findings on MAG3 F0, data were compared with the results of concurrent DMSA studies. In the prospective study, for 57 children with clinical and laboratory findings of pyelonephritis, the results of two scintigraphy imagings were compared. In both studies, MAG3 F0 was as sensitive as DMSA in diagnosis of renal parenchymal damage. These authors believed that MAG3-F0 scintigraphy is a fast and accurate technique for the diagnosis of acute pyelonephritis, and concluded that A fast (25-min) planar dynamic MAG3-F0 study was found to be as sensitive at depicting focal parenchymal abnormalities in APN as was the 3- to 4-h DMSA routine procedure. The sensitivity and specificity of both studies need further evaluation [11].

In the literature, a sensitivity of between 50% and 70% has been reported using MAG3 that was performed concurrently with DMSA. However based on the Patlac Plot, a sensitivity

of 80% has been reported [31].

In our study, we did not perform MAG3 and DMSA scans concurrently in one group, because of ethical problems due to over-radiation. Another limitation of our study was the low sample size, which is recommended to cover in further studies. However, this study showed that the accuracy of MAG3 and DMSA scans for detection of renal parenchymal scars was not significantly different and MAG3-F0 imaging during acute pyelonephritis had the same specificity and PPV of DMSA scan for persistent kidney lesions which were detected by late DMSA scan.

We concluded that if the MAG3 parenchymal image is abnormal, then there is renal damage but if this image is normal, a focal defect has not been excluded. Thus an abnormal MAG3-F0 precludes the need for a Tc-DMSA scan for detection of renal damage in acute phase of pyelonephritis. Whereas, an abnormal MAG3 scintigraphy and even DMSA scan in acute phase of pyelonephritis, must be followed by an after 6-months DMSA scan to authenticate the presence of persistent scar in renal parenchyma, later in the follow up period.

References

1. Majd M, Rushton HG. Renal cortical scintigraphy in the diagnosis of acute pyelonephritis. *Semin Nucl Med* 1992; 22:98-111.
2. Taskinen S, Ronnholm K. Post-pyelonephritic renal scars are not associated with vesicoureteral reflux in children. *J Urol* 2005; 173(4):1345-8.
3. Dolezel Z, Mach V, Kopecna L, Starha J, Dostalkova D. Diagnosis of acute pyelonephritis in childhood: comparison of ultrasonographic examination and renal scintigraphy using ^{99m}Tc DMSA. *Bratisl Lek Listy* 2000; 101(9):495-8.
4. Puseljc S, Arambasic J, Gardasanic J, Milas V, Puseljc I, Sipl M. The value of Tc^{99m}-DMSA renal scintigraphy in evaluation of severity of parenchymal lesions in children with acute urinary tract infection. *Acta Med Croatica* 2003; 57(1):5-10.
5. Donoso R G, Lobo S G, Arnello V F, Arteaga V MP,

- Coll C C, Hevia J P, et al. Renal scars after one year of follow up in children with a first episode of acute pyelonephritis. *Rev Med Chil* 2006; 134(3):305-11.
6. Prvulovich EM, Bomanji JB. The role of nuclear medicine in clinical investigation. *BMJ* 1998; 316(11 April):1140-6.
7. Piepsz A. Radionuclide studies in pediatric nephrology. *Eur J Radiol* 2002; 43(2):146-53.
8. Sfakianakis GN, Georgiou MF. MAG3 SPECT: a rapid procedure to evaluate the renal parenchyma. *J Nucl Med* 1997; 38(3):478-83.
9. Gordon I, Anderson PI, Lythgone MF, Orton M. Can technetium 99-m-mercaptoacetyl triglycine replace technetium 99-m-dimercaptosuccinic acid in the exclusion of a focal renal defect? *J Nucl Med* 1992; 33:2090-3.
10. Piepsz A, Pintelon H, Verboven M, Keuppens F, Jacobs A. Replacing 99 m-Tc-DMSA for renal imaging? *Nucl Med Commun* 1992; 133:494-496.
11. Sfakianakis GN, Cavagnaro F, Zilleruelo G, Abitbol C, Montane B, Georgiou M et al. Diuretic MAG3 scintigraphy (F0) in acute pyelonephritis: regional parenchymal dysfunction and comparison with DMSA. *J Nucl Med* 2000; 41(12):1955-63.
12. Zorc JJ, Kiddoo DA, Shaw KN. Diagnosis and management of pediatric urinary tract infections. *Clinical Microbiology Reviews* 2005; 18(2):417-422.
13. Sfakianakis GN, Carmona AJ, Sharma A, Strauss J, Georgiou MF, Zilleruelo GE et al. Diuretic MAG3 scintigraphy in children with HIV nephropathy: diffuse parenchymal dysfunction. *J Nucl Med* 2000; 41:1037-1042.
14. Knapp RG, Miller MC (eds). Describing the performance of a diagnostic test. In: *Clinical epidemiology and biostatistics*. 1st ed. Baltimore, Maryland: Williams & Wilkins; 1992. pp.41-2.
15. Zaki M, Badawi M, Al Mutari G, Ramadan D, Abdul Rahman M. Acute pyelonephritis and renal scarring in Kuwaiti children: a follow-up study using 99mTc DMSA renal scintigraphy. *Pediatr Nephrol* 2005; 20(8): 1116-9.
16. Winberg J, Bollgren I, Kallenius G, Mollby R, Svenson SB. Clinical pyelonephritis and focal renal scarring. A selected review of pathogenesis, prevention, and prognosis. *Pediatr Clin North Am*. 1982; 29:801-14.
17. Rushton HG, Majd M, Chandra R, Yim D. Evaluation of 99 m-Technetium-dimercapto-succinic acid renal scans in experimental acute pyelonephritis in piglets. *J Urol* 1988; 140:1169-74.
18. Benador D, Benador N, Slosman D, Mermillod B, Girardin E. Are younger children at highest risk of renal sequelae after pyelonephritis? *Lancet* 1997; 349:17-9.
19. Biggi A, Dardanelli L, Pomerio G, Cussino P, Noello C, Sernia O, et al. Acute renal cortical scintigraphy with a first urinary tract infection. *Pediatr Nephrol* 2001; 16:733-8.
20. Ditchfield MR, Nadle HR. The DMSA scan in pediatric urinary tract infection. *Australasian Radiol* 1998; 42:318-20.
21. Ditchfield MR, Grimwood K, Cook DJ, Powell HR, Sloane R, Nolan TM et al. Time course of transient cortical scintigraphic defects associated with acute pyelonephritis. *Pediatr Radiol* 2002; 32:849-52.
22. Lin KY, Chiu NT, Chen MJ, Lai CH, Huang JJ, Wang YT et al. Acute pyelonephritis and sequelae of renal scar in pediatric first febrile urinary tract infection. *Pediatr Nephrol* 2003; 18:362-5.
23. Stokland M, Hellstrom M, Jacobsson B, Jodal U, Lundgren P, Sixt R. Early 99mTc dimercaptosuccinic acid (DMSA) scintigraphy in symptomatic first-time urinary tract infections. *Acta Paediatr* 1996; 85:430-6.
24. Patzer L, Seeman T, Luck C, Wuhl E, Janda J, Miseselwitz J. Day- and night-time blood pressure elevation in children with higher grades of renal scarring. *J Pediatr* 2003; 142:117-22.
25. Hoberman A, Hickey RW, Baskin M, Kearney DH, Wald ER. Imaging studies after a first febrile urinary tract infection in young children. *N Engl J Med* 2003; 348:195-202.
26. Wallin L, Helin I, Bajc M. Follow-up of acute pyelonephritis in children by Tc-99m DMSA scintigraphy: quantitative and qualitative assessment. *Clin Nuclear Med* 2001;26:423-32.
27. Gacinovic S, Buscombe J, Costa DC, Hilson A, Bomanji J, Ell PJ. Inter-observer agreement in the reporting of 99Tcm-DMSA renal studies. *Nuclear Med Commun* 1996; 17:596-602.
28. Shanon A, Feldman W, McDonald P, Martin DJ, Matzinger MA, Shillinger JF et al. Evaluation of renal scars by technetium-labeled dimercaptosuccinic acid scan, intravenous urography, and ultrasonography: a comparative study. *J Pediatr* 1992; 120:399-403.
29. Rushton HG, Majd M, Jantusch B, Wiedermann BL, Belman AB. Renal scarring following reflux and nonreflux pyelonephritis in children: evaluation with 99m technetium-dimercaptosuccinic acid scintigraphy. *J Urol* 1992; 147:1327-32.
30. Pickworth FE, Vivian GC, Franklin K, Brown EF. 99Tcm-mercapto acetyl triglycine in paediatric renal tract disease. *Br J Radiol* 1992; 65(769):21-9.
31. Gad HM, Shokeir AA, Mohy El-Din MS. C9-99mTc-MAG3 dynamic imaging in diagnosis of pyelonephritic changes and renal scarring: a comparative study with 99m-Tc-DMSA. *Alasbimn Journal* 2004; 6(25): 120-160.