

Computed Tomographic measurement of distal femor rotation in Iranian population

Mehdi Moghtadaei¹, Javad Moghimi², Gholamreza Shahhoseini³

Received: 10 July 2014

Accepted: 29 September 2014

Published: 28 January 2015

Abstract

Background: Proper rotation of components in total knee arthroplasty (TKA) will largely affect the postoperative outcome. Ethnic variation may affect rotational profile. We aimed to evaluate distal femur rotation in Iranian population using transepicondylar axes.

Methods: From a total of 450 knee CT scans and via consecutive sampling, 150 qualified subjects with normal lower extremities alignment were selected comprising 96 (64%) males and 54 (36%) females aging 17-80 years. The posterior condylar angle and condylar twist angles were defined as angles between either surgical epicondylar axis (line connecting lateral epicondylar prominence and the medial sulcus) or clinical epicondylar axis (line connecting most prominent points of both epicondyle) and posterior conylar line. Data were compared among genders.

Results: Average age of our samples was 43 years (ranging 11-80). Mean (\pm sd) values for posterior condylar angle and condylar twist angles were $2.35^\circ (\pm 1.34)$ and $5.77^\circ (\pm 1.70)$, respectively. The former variable was not discernible in twenty of our subjects because of obscure medial sulcus. Our findings were totally appeared similar to studies from other ethnicities and the observed minor differences may have originated from amount of osteoarthritis and malalignment.

Conclusion: Overall, Iranian distal femur rotational profile was similar to other reports. Some minor observed differences may be partially due to samples' age and different amount of knee osteoarthritis. It is proposed to rely on several methods for determining rotational profile while performing TKA. Moreover, preoperative computed tomography should be fully scrutinized especially in severely osteoarthritic knees.

Keywords: Femur, Rotation, computed tomography, Iranian.

Cite this article as: Moghtadaei M, Moghimi J, Shahhoseini Gh. Computed Tomographic measurement of distal femor rotation in Iranian population. *Med J Islam Repub Iran* 2015 (28 January). Vol. 29:169.

Introduction

Reconstructive surgery of the lower limb such as total knee arthroplasty (TKA) depends highly on proper sizing and positioning for longevity. Correct rotational alignment of the femoral component is an important factor to reduce patellofemoral maltracking and asymmetrical flexion gap. Most emphasis has been put on the dangers of internal rotation of the femoral component (1, 2).

Rotation of the femoral component can be assessed relative to the landmarks located

on the distal femur or its relation with the tibia. Distal femoral references include the posterior condylar line (PCL), the anatomical transepicondylar axis (TEA), the surgical TEA, the trochlear anteroposterior (AP) axis, and the femoral transverse axis (2-9). Posterior condylar angle and condylar twist angle are defined as angle between anatomical and surgical TEA relative to PCL, respectively.

Mounting evidence denotes that racial differences exist in the geometry of the femur between ethnicities (1, 6, 10). Most of

1. MD, Associate Professor of Orthopedics, Department of Orthopedic Surgery, Rasoul-e-Akram Hospital, Iran University of Medical Sciences, Tehran, Iran. mmoghtadaei@gmail.com

2. (Corresponding author) MD, Orthopedic Surgeon, Department of Orthopedic Surgery, Rasoul-e-Akram Hospital, Iran University of Medical Sciences, Tehran, Iran. moghimi_javad@yahoo.com

3. MD, Assistant Professor of Orthopedics, Department of Orthopedic Surgery, Rasoul-e-Akram Hospital, Iran University of Medical Sciences, Tehran, Iran. dr.shahhoseini@gmail.com

these literatures are from white population yielded mainly from cadaveric or imaging studies (7-9, 11, 12). The best of the rotational landmarks to which all other parameters can be compared is yet unclear. Some authors even questioned the definition of “correct” or “normal” rotations. It is also stated that lower extremity alignment (i.e. varus or valgus) and severity of osteoarthritis can affect these variables (2, 13, 14).

Geographic and racial differences in these rotational landmarks are less scrutinized in Asian ethnicity (14-18). To the best of our knowledge, there is only a few of such data in Iranians. In the present study, we evaluated two rotational indices, posterior condylar angle and condylar twist angle, in CT measurement of distal femur. Better definition of this profile will result in more precise placement of TKA component in our population and improve its outcomes.

Methods

During 2013, a descriptive study was conducted at the outpatient orthopedics clinic of Rasoul Akram hospital. This is a referral center for patients of diverse ethnic groups and various socioeconomic conditions. Consultation with a statistician and review of previous literatures suggested an acceptable sample size of 150 (6, 8, 11, 12).

The selection criteria were defined as ages after maturity, normal apparent lower limb alignment. Patients with severe osteoarthritis, any rheumatoid condition, gross congenital anomaly or deformity and patients with concomitant hip or spine deformities were excluded.

A computerized tomography (CT) scan of the knee was obtained using a helical CT scanner with 1-3 millimeter of slice thickness. After review of several consecutive cuts, following landmarks were delineated: the posterior condylar line (PCL) was drawn from the most posterior point of the medial and lateral posterior condyles; the surgical epicondylar axis (sTEA) is formed by connecting the lateral epicondylar prominence and the medial sulcus (figure 1); the clinical epicondylar axis (cTEA) that con-

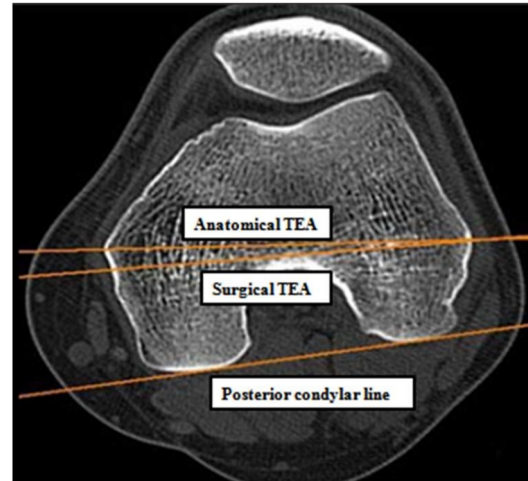


Fig. 1. Landmarks applied to determine rotational profile on CT scan

nects the most prominent points of both epicondyle. The angles between surgical and clinical TEA corresponding to posterior condylar line were measured and defined as “posterior condylar angle” and “condylar twist angle”, respectively.

All measurements were recorded in millimeters in MarcoPacs software. Differences between genders were compared using Student’s t-test. Paired t-test was applied for comparison of the angles in the same gender. A p value of less than 0.05 was considered significant.

Informed consents were obtained from all participants of the study and the study proposal was approved by the institutional review board of Iran University of Medical Sciences (IUMS). The protocol was also in accordance with the ethical standards stated in the 1964 Declaration of Helsinki and its later amendments.

Results

We evaluated a total of 150 subjects, comprising 96 males (64%) and 54 females (36%). Mean (\pm sd) age was 43.02 (\pm 1.04) ranging 17-80 years. No statistical difference was observed among genders’ age ($p=0.063$). The demographic data are shown in Table 1. In most of our cases, required anatomic landmarks were obtained on one CT scan cut. Medial sulcus was not discernable in 20 cases, therefore only the condylar twist angle was measured for

Table 1. Discriptive statistics of subjects' demographic variables

Parameter	Total (n=150)	Male (n=96)	Female (n=54)
	Mean±SD (range)	Mean±SD (range)	Mean±SD (range)
Age (year)	43.0± 17.18 (17-80)	41.8± 17.11(18-80)	45.6±16.86 (17-78)
Height (cm)	168.7±7.57 (150–175)	171.8±8.11 (152–175)	156.8±5.85 (150–170)

Table 2. Rotational characteristics of distal femur

	Posterior condylar angle	Condylar twist angle	P value
	Mean ±SD	Mean ±SD	
Total (range)	2.3±1.34(0-5)	5.7±1.70 (2.5-9)	P<0.001
Male	2.4±1.28	5.9±1.89	P<0.001
Female	2.1±1.45	5.6±1.88	P<0.001

them (Table 2).

Totally, Condylar twist angle was in 3.42 degree more external rotation relative to posterior condylar angle. Such discrepancy was also significant when scrutinized among genders ($p<0.001$). No meaningful difference was observed among genders regarding each angle. Significant correlation was found among both angles ($r=0.836$), while there was no remarkable correlation between age and either of these angles.

Discussion

Proper sizing and rotation of components will largely affect the postoperative outcome in total knee arthroplasty (TKA). Malrotation may lead to abnormal patellofemoral kinematics, asymmetrical flexion gap, and early failure (2, 3, 4). Most emphasis was put on the dangers of internally rotating the femoral component. In current TKA systems, the PCL line is used widely as a guide for rotational profile although it may not be reliable when the posterior portion of the femoral condyle is severely damaged (1, 2).

Several landmarks on distal femur and proximal tibia have been applied for rotational alignment. The best rotational reference to which all other parameters can be compared is not clear yet (5, 8, 9). Moreover, information of ethnical variations in rotational profile is important in reconstructive surgery of the lower limb (6, 17, 18, 19). Cadaveric or imaging evaluation studies were conducted to evaluate these anatomical variations and inter- and intra-observer reliability of each land mark.

From biomechanical aspect of view, TEA is shown to be corresponded to flexion axis of the knee (15). The axis is approximately vertical to the mechanical axis and, therefore, resection of distal femur parallel to it seems to be reasonable. Berger et al were from the pioneers of using CT scans for evaluation of the rotational alignment (12). They defined surgical transepicondylar axis and recommend it because of easy localization via finger palpation during TKA. Considering average widths of 11.4 mm for medial sulcus as defined by Griffin (20), surgical TEA was also posed as an optimal landmark during TKA especially in revision procedures (2, 4, 6, 17).

The medial sulcus, however, may be obscured as a result of osteoarthritis. Some study reported it was discernible in only one fifth of patients with severe osteoarthritis (14). In younger samples like ours this could be demarcated in up to eighty percent. As an alternative, it was suggested to use condylar twist angle that is placed in more external rotation. On the other hand, preoperative CT scan is emphasized as a priceless remedy for evaluation of rotational profile in patients with obscure medial sulcus and posterior condylar defect as a result of severe osteoarthritis.

In reported studies, there sometimes were significant discrepancies between samples of the same nationality. This may in part be explained because of different ethnicities recruited during sampling. For better comparison of such variability, we gathered some reports of white and Asian population in Table 3. Totally, rotational measurements based on transepicondylar axes sug-

Table 3. Distal femoral rotational axes reported in various studies

	Posterior Condylar Angle (°)			Condylar Twist Angle (°)			Age
	Total (±SD)	Male (±SD)	Female (±SD)	Total (±SD)	Male (±SD)	Female (±SD)	
CT or MRI study							
Present study	2.35(1.34)	2.45(1.28)	2.12(1.45)	5.77(1.7)	5.88(1.89)	5.57(1.88)	43 (17-80)
Jabalameili (17) (Iran)	1.90(1.85)	2.60(1.67)	1.00(1.69)	5.68(1.89)	6.23(1.95)	4.97(1.55)	38.8(16-75)
Mullaji (18) (India)				5(1.7)			31.3 (26-40)
Nagamine (19) (Japan)				5.8(Normal)			50.2
				6.4 (PF-OA)			
				6.2 (FT-OA)			
Yoshino (14) (Japanese)	2.9 (1.8)			6.4 (1.7)			75.5(49-89)
Griffin (20)	3.11(1.75)	2.75(1.61)	3.33(1.82)				
	2.7 (<41 years)						
	3.5 (>41 years)						
Arima (11)				5.7(1.7)			
Cadaveric study							
Berger (12)		3.5 (1.2)	0.3 (1.2)		4.7(3.5)	5.2 (4.1)	
Yip (15) (Chinese)		5.1(1.9)	5.8(1.8)				78(18-94)
Griffin (21)	3.3(1.9) (varus)	3.6 (1.8)	3.7(2.6)				
	3.3(2.3)(neutral)						
	5.4(2.3)(valgus)						
Arima (11)				4.4(2.9)			

PF, patellofemoral; OA, osteoarthritis; FT, femorotibial.

gest similar profile among Iranian population and reported values from most of Asian and Caucasian ethnicities. Nevertheless, there are some minor discrepancies even among studies from the same populations. These may be attributed to older age and more osteoarthritic knees selected in the samples with higher reported values. Interestingly, a review article by Victor also stated that younger patients seemed to have smaller amounts of rotational angles compared with older patients. It was hypothesized that this might be due to posterolateral cartilage wear resulted from advancing age. However, some authors (e.g. Matsuda) are against this (2, 16). In our review of literatures, only reported values from a Chinese study by Yip et al. was indicative of significant external rotation of Asian distal femur relative to Caucasians (15).

Females enjoyed slightly greater value of these rotational values in majority of the studies. However, our findings accompanying with Berger and some other reports showed that males' distal femur are more

externally rotated (12, 17). The difference between genders was not statistically significant. This is supported by most of current studies, although a few authors report significant gap (5, 15).

In another study conducted over Iranian population with similar age distribution, Jabalameili and colleagues also found that males have more externally rotated distal femur. Their reported discrepancy had significant statistical difference. Moreover, further analysis of their data failed to reveal any significant correlation between subjects' age and distal femur rotation.

Conclusion

We observed minor difference among Iranian distal femoral rotational profile with other reports that are insignificant either statically or clinically. This may be explained more by different age of samples. However, even such minor gaps can affect knee arthroplasty adversely. Therefore, relying on a single technique for determining rotational characteristics of the patients even from the same ethnicity may not be

reasonable. This is more emphasized regarding the worst track record on inter- and intraobserver variability reported for the TEA (2). Given that most candidates of TKA are cases with severe osteoarthritis and malaligned lower extremity, using CT scans as a preoperative planning tool for rotational alignment is suggested.

References

1. Zhang XL, Zhang W, Shao J. Rotational alignment in total knee arthroplasty: nonimage-based navigation system versus conventional technique. *Chin Med J* 2012;125(2):236-243.
2. Victor J. Rotational alignment of the distal femur: A literature review. *Orthop Traumatol Surg Res* 2009;95(5):365-372.
3. Victor J, Van Doninck D, Labey L, Van Glabbeek F, Parizel P. A common reference frame for describing rotation of the distal femur: a CT based kinematic study using cadavers. *J Bone Joint Surg* 2009;91(5):683-689.
4. Uehara K, Kadoya Y, Kobayashi A, Ohashi H, Yamano Y. Bone anatomy and rotational alignment in total knee arthroplasty. *Clin Orthop Relat Res* 2002;402:196-201.
5. Yoshioka Y, Siu D, Cooke T. The anatomy and functional axes of the femur. *J Bone Joint Surg* 1987; 69: 873-880
6. Vaidya SV, Gadhiya RM, Bagaria V, Ranawat AS, Ranawat CS. Computed tomographic evaluation of femoral component rotation in total knee arthroplasty. *Indian J Orthop* 2013;47(1):40-44
7. Berhouet J, Beaufils P, Boisrenoult P, Frasca D, Pujol N. Rotational positioning of the tibial tray in total knee arthroplasty: a CT evaluation. *Orthop Traumatol Surg Res* 2011;97(7):699-704.
8. Aglietti P, Sensi L, Cuomo P, Ciardullo A. Rotational position of femoral and tibial components in TKA using the femoral transepicondylar axis. *Clin Orthop Relat Res* 2008;466(11):2751-275.
9. Rossi R, Bruzzone M, Bonasia DE, Marmotti A, Castoldi F. Evaluation of tibial rotational alignment in total knee arthroplasty: a cadaver study. *Knee Surg Sports Traumatol Arthrosc* 2010;18(7):889-893.
10. Mahfouz M, Abdel Fatah EE, Bowers LS, Scuderi G. Three-dimensional morphology of the knee reveals ethnic differences. *Clin Orthop Relat Res* 2012; 470:172-85.
11. Arima J, Whiteside LA, McCarthy DS, White S. Femoral rotational alignment, based on the anteroposterior axis, in total knee arthroplasty in a valgus knee. *J Bone Joint Surg* 1995;77:1331-1334.
12. Berger RA, Rubash HE, Seel MJ, Thompson WH, Crossett LS (1993) Determining the rotational alignment of the femoral component in total knee arthroplasty using the epicondylar axis. *Clin Orthop Relat Res* 286:40-47.
13. Victor J, Van Doninck D, Labey L, Innocenti B, Parizel PM. How precise can bony landmarks be determined on a CT scan of the knee? *Knee*. 2009; 16(5):358-365.
14. Yoshino N, Takai S, Ohtsuki Y, Hirasawa Y. Computed tomography measurement of surgical and clinical transepicondylar axis of the distal femur in osteoarthritic knees. *J Arthroplasty* 2001;16: 493-494.
15. Yip DK, Zhu YH, Chiu KY, Ng TP. Distal rotational alignment of the Chinese femur and its relevance in total knee arthroplasty. *J Arthroplasty* 2004; 19:613-9.
16. Matsuda S, Matsuda H, Miyagi T, Sasaki K, Iwamoto Y, Miura H. Femoral condyle geometry in the normal and the varus knee. *Clin Orthop* 1998; 349:183-8.
17. Jabalameli M, Rahbar M, Bagherifard A, Hadi H, Moradi A, Radi M, Mokhtari T. Evaluation of distal femoral rotational alignment according to transepicondylar axis and Whiteside's line: a study in Iranian population. *Shafa Ortho J* 2013;1(3): 22-28.
18. Mullaji A, Sharma A, Marawar S, et al. Distal femoral rotational axes in Indian knees. *Journal of Orthopaedic Surgery* 2009;17(2):166-9
19. Nagamine R, Miura H, Inoue Y, Urabe K, Matsuda S. Reliability of the anteroposterior axis and the posterior condylar axis for determining rotational alignment of the femoral component in total knee arthroplasty. *J Orthop Sci* 1998;3(4):194-198.
20. Griffin FM, Math K, Scuderi GR, et al. Anatomy of the epicondyles of the distal femur: MRI analysis of normal knees. *J Arthroplasty* 2000; 15:354.
21. Griffin FM, Insall JN, Scuderi GR. The posterior condylar angle in osteoarthritic knees. *J Arthroplasty* 1998;13:812-5.