

## Cushing syndrome secondary to thymic carcinoid synchronous with tuberculous lymphadenitis and pulmonary tuberculosis: a case report

F. Esfahanian, MD.<sup>1</sup>, A. Sadeghi, MD.<sup>2</sup>

*Department of Endocrinology, Imam Khomeini Hospital, Tehran University of Medical Sciences, Tehran, Iran.*

### Abstract

Thymic carcinoid is an uncommon neoplasm that can present with Cushing syndrome. We report a 39-year old woman with symptoms of Cushing syndrome secondary to thymic carcinoid and synchronous with tuberculous lymphadenitis and pulmonary tuberculosis.

**Keywords:** thymic carcinoid, tuberculosis, Cushing syndrome

### Introduction

Ectopic ACTH syndrome is the second most common etiology of Cushing syndrome.

Thymic carcinoid is an uncommon cause of Cushing syndrome that has a more aggressive nature than other carcinoid tumors with tendency of local invasion and distant metastases. Treatment includes surgical excision while adjuvant therapy with radiotherapy and chemotherapy is typically ineffective. The immunodeficiency state secondary to Cushing syndrome can reveal occult Mycobacterium tuberculosis infection.

### Case report

A 39-year old woman presented with a history of three months of generalized weakness, blurred vision, low back pain, lower extremity edema and easy bruising. She had no cough, chest pain, constitutional symptoms, and weight changes. In physical examination, there was bilateral cataract, left axillary lymph nodes, multiple echymoses on her arm and low-

er extremity edema. There was proximal and distal motor weakness and decreased deep tendon reflexes but normal cranial and sensory nerve examination. Blood pressure was 160/90 mmHg and she had no fever. The past medical history was negative. Drug history was positive for receiving potassium chloride and spironolactone for treatment of hypokalemia.

The hemoglobin level was 11.1gr/dl the hematocrit 34 percent and the mean corpuscular volume  $80.4\mu\text{m}^3$ . White cell count was 14600 with dominancy of neutrophils and the platelet count 291000 per cubic millimeter. The ACTH level was 200 pg/ml (normal range, 6 to 76), urinary cortisol level 1100  $\mu\text{m}$  per 24 hours (normal range 20 to 70) and the fasting cortisol level 1010 ng/ml (normal range, 50 to 250). The parathyroid hormone level was 12.6pg/ml (normal range, 10 to 60). Renin and aldosterone levels were 10 ng per ml/hr (normal range, 1 to 6) and 355 pg/ml (normal range, 35 to 300). Other laboratory results were as follows: potassium, 1.9 mmol per liter; sodium, 140 mmol per liter; calcium, 9.5 mg per deciliter; phosphorus, 4.4 mg/dl; alkaline phosphatase, 651 U per liter;

1. **Corresponding author**, Assistant Professor of Internal Medicine, Tehran University of Medical Sciences. Endoscopic Ward, 1st. Floor, Imam Khomeini Hospital, Keshavarz Boulevard, Tehran, Iran. Tel: +9821 66935456, email: amirsadeghi7651@yahoo.com.

2. Associate Professor of Endocrinology, Tehran University of Medical Sciences, Imam Khomeini Hospital, Tehran, Iran.

and fasting blood glucose 240 mg per milliliter. The serum creatinine, blood urine nitrogen, thyroid function tests and liver function tests were normal.

Computed tomography of chest showed an heterogeneous anterior mediastinal mass and one nodule in the right lower lobe (Fig 1). Abdominal sonography showed bilateral adrenal hypertrophy. Magnetic resonance imaging of the lumbosacral spine showed mild diffuse collapse in the lumbar area compatible with osteoporosis. In DEXA bone densitometry the mean femoral T score and Z score were -1.26 and -1.11, respectively; and the mean lumbar T score and Z score were -2.79 and -2.73, respectively.

An excisional biopsy was obtained from the axillary lymph node that revealed caseating granuloma with varied size tubercles compatible with tuberculosis. Quadruple antituberculosis therapy with Isoniazide, Rifampin, Ethambutol and Pyrazinamide was instituted and then thoracotomy was performed that showed an encapsulated anterior mediastinal mass (12×9 cm) and one nodule at the right lower lobe (2×2 cm) but without lymph node and other thoracic

organ involvement. Exisional biopsy was undertaken. Histological evaluation of the mediastinal mass showed thymic carcinoid with typical appearance and extensive hemorrhagic infarction and the pathological report of the lung nodule was noncaseating granulomatous inflammatory reaction consistent with tuberculosis.

The final diagnosis was ACTH-related Cushing syndrome secondary to thymic carcinoid synchronous with lymph node and pulmonary tuberculosis. Our concept is that the immunodeficiency state secondary to Cushing syndrome culminated in revealing occult mycobacterium tuberculosis infection.

One month after surgery and medical therapy for tuberculosis infection the general condition of the patient improved, the hypokalemia was corrected and the serum cortisol level had returned to normal.

### Discussion

Ectopic secretion of ACTH by nonpituitary tumors composes 10 to 15 percent of cases of Cushing syndrome. Tumors of a wide variety of tissues, usually carcinomas rather than sarco-

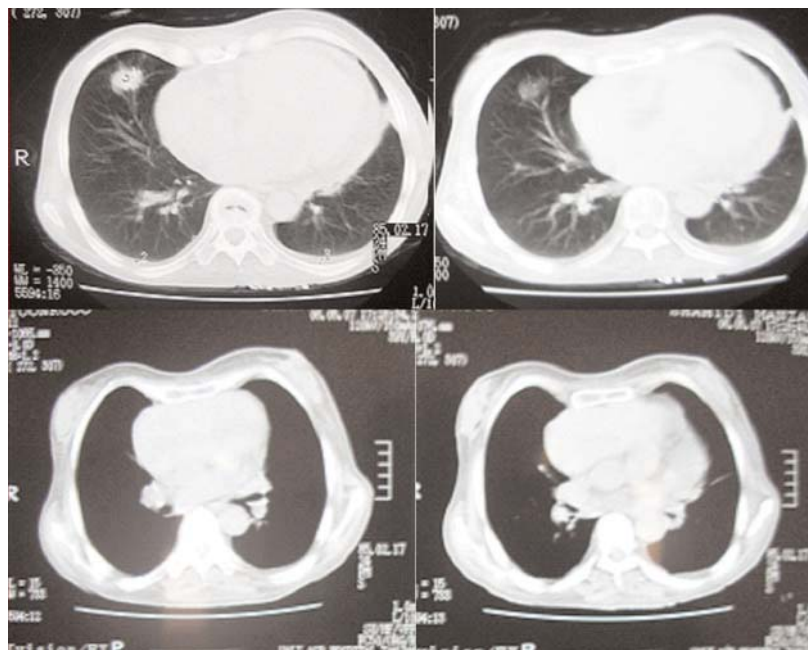


Fig. 1. Heterogeneous anterior mediastinal mass and one nodule in the right lower lobe.

mas or lymphomas, have been associated with the ectopic ACTH syndrome. Most cases are caused by tumors of the lung, pancreas, or thymus [1,2]. Among them the most common are small-cell carcinomas of the lung which, like pulmonary carcinoids and rare multiple pulmonary tumorlets, arise from neuroendocrine cells in the distal bronchioles [3]. The ACTH-secreting pancreatic and thymic tumors are also carcinoid tumors that arise from neuroendocrine cells in those tissues. Ectopic ACTH syndrome is probably the second most common cause of Cushing's syndrome, but is often not diagnosed. The incidence of ectopic ACTH syndrome can be estimated to be about 660 per million per year.

The clinical signs and symptoms of Cushing's syndrome may be absent or minimal with ectopic ACTH production and hypokalemic alkalosis is a prominent manifestation. The onset of Cushing's syndrome may be sudden, particularly in patients with carcinoma of the lung, and this feature accounts in part for the failure of these patients to exhibit the classic manifestations. On the other hand, patients with carcinoid tumors have longer clinical courses and usually exhibit the typical Cushingoid features [4].

Until 1972, all epithelial tumors of the thymus were referred to as "epithelial thymoma." In 1972, Rosai and Higa reported 8 cases of neuroendocrine tumors of the thymus and coined the term "thymic carcinoid" [5]. Thymic carcinoid is an uncommon neoplasm and accounts for two percent of all mediastinal tumors and five percent of thymic lesions [6]. All cases have been reported in adults, with a mean age of 48 to 54 years and a male preponderance [5,7,9,10,11].

Primary neuroendocrine carcinomas of the thymus comprise a wide spectrum of lesions ranging from well-differentiated to poorly-differentiated neoplasms. By convention, the better-differentiated examples have been traditionally designated as thymic carcinoids and thought to represent the mediastinal counter-

part of carcinoid tumors in other foregut locations. However, recent studies have shown that such neoplasms, when arising in the thymus, exhibit a much more aggressive behavior than those originating at other locations [6]. Thymic carcinoid tumors can be considered thymic neuroendocrine carcinomas because of their malignant behavior and histologic appearance of atypical carcinoid tumors [7].

Symptoms include chest and shoulder pain, cough, and dyspnea. Associations with carcinoid syndrome or myasthenia gravis are distinctly unusual, although, one third of carcinoids are functionally active and can produce Cushing's syndrome in some cases [9]. Fifteen to 30 percent of patients are asymptomatic [5,7]. In the study of Wick et al [9] thymic carcinoid presented either as asymptomatic, radiographically detected mediastinal masses or as neoplasms producing symptoms of thoracic structural displacement or Cushing's syndrome.

Chest radiographs and CT scans typically show a well-circumscribed anterior mediastinal mass. In patients who present with Cushing's syndrome, the tumor may be too small to be detected by radiograph, and a CT scan may be required [13,14].

In a study of 15 cases of carcinoid tumor of the thymus, diagnosed and treated at the Mayo Clinic, the tumor was associated with ectopic ACTH production in six patients, of whom five had Cushing's syndrome [14].

Up to 25% of thymic carcinoids are found in patients with multiple endocrine neoplasia (MEN). In contrast with metastatic midgut carcinoids and sporadic thymic carcinoids, MEN1-related thymic carcinoid is rarely associated with carcinoid syndrome [12]. Local invasion and metastasis are common. Prognosis is poor [13,14]. When an apparent thymic carcinoid is detected, it is important to exclude mediastinal metastasis from a primary carcinoid elsewhere (e.g. in the lung) and also to search for other clinical manifestations of MEN I or MEN II.

Thymic carcinoids vary in size from 1.3 to 18 cm. They are well-circumscribed or encapsulated tumors, and the cut surface is solid, gray tan with frequent areas of hemorrhage and necrosis [5,9].

Thymic carcinoid tumors behave in a malignant fashion. They are prone to mediastinal and cervical lymph node and distant metastases (especially lung and bone) several years after surgical excision. Lymph node metastases are present in 60 percent of cases at the time of resection [16]. Metastases occur in over 70 percent of patients with a delay as long as 8 years after the initial diagnosis [9]. The mortality rate is high. In the study of de Montpreville et al among 14 patients with the diagnosis of thymic carcinoid, overall survival was 46% and 31% at 3 and 5 years, respectively. However, all patients died of the disease within 109 months as a result of local progression (n=5), local relapse (n=3), distant metastases (n=8), or a combination of these reasons [7].

Treatment includes surgical excision, as total resection of the tumor produces longer survival than partial resection or simple biopsy [7].

Adjuvant therapy with radiotherapy and chemotherapy is typically ineffective. There are few reports of the synchronous occurrence of pulmonary tuberculosis and bronchial carcinoid tumor [17] but still there is not any report of the synchronous occurrence of thymic carcinoid and tuberculosis.

## References

1. Beitr K, et al. Bronchial carcinoid with concomitant active pulmonary tuberculosis [article in German]. Berlin 1963;126 :243-52.
2. Orth DN. Ectopic hormone production. In: Endocrinology and Metabolism, 2nd ed. Felig P, Baxter, Broadus AE, Frohman LA editors. New York: McGraw-Hill; 1987. pp.1692.
3. Ilias I, et al. Cushing's syndrome due to ectopic corticotropin secretion: twenty years' experience at the National Institutes of Health. J Clin Endocrinol Metab 2005;

90(8):4955-62

4. Kasper D, et al. Harrison's principles of internal medicine, 16th ed. NY: McGraw Hill; 2005. pp.940-956.
5. Rosai J, Higa E. Mediastinal endocrine neoplasm, of probable thymic origin, related to carcinoid tumor. Clinicopathologic study of 8 cases. Cancer 1972; 29:1061.
6. Klemm KM, Moran CA. Primary neuroendocrine carcinomas of the thymus. Semin Diagn Pathol 1999; 16(1):32-41.
7. De Montpreville VT, Macchiarini P, Dulmet E. Thymic neuroendocrine carcinoma (carcinoid): a clinicopathologic study of fourteen cases. J Thorac Cardiovasc Surg 1996;111(1):134-41.
8. Shimosato Y, Mukai K. Tumors of the mediastinum, 3rd ed. Washington, DC: Armed Forces Institute of Pathology; 1995. pp. 234-247.
9. Wick MR, Scheithauer BW. Thymic carcinoid. A histologic, immunohistochemical, and ultrastructural study of 12 cases. Cancer 1984 ;53(3):475-84.
10. Economopoulos GC, Lewis JW, Lee MW, Silverman NA. Carcinoid tumors of the thymus. Ann Thorac Surg 1990;50(1):58-61.
11. Valli M, et al. Atypical carcinoid tumor of the thymus: a study of eight cases. Histopathology 1994;24 (4):371-5.
12. Esfahanian F, Nakhjavani M, Hoseini R. Cushing syndrome due to thymic carcinoid in multiple endocrine neoplasia type 1 and brief review about causes of hypercortisolism in MEN syndrome. IJEM 2005; 7(1):79-86 .
13. Teh BT, et al. Clinicopathologic studies of thymic carcinoids in multiple endocrine neoplasia type 1. Medicine (Baltimore) 1997 ;76(1):21-9.
14. Gibril F, et al. Prospective study of thymic carcinoids in patients with multiple endocrine neoplasia type 1. J Clin Endocrinol Metab 2003;88(3):1066-81.
15. Wick MR, Carney JA, Bernatz PE; Brown LR. Primary mediastinal carcinoid tumors. Am J Surg Pathol 1982;6(3):195-205.
16. Fukai I, et al. Thymic neuroendocrine tumor (thymic carcinoid): a clinicopathologic study in 15 patients. Ann Thorac Surg 1999;67(1):208-11.
17. Yilmaz A, et al. Coexisting bronchial carcinoid tumor and pulmonary tuberculosis in the same lobe: a case report. Tuberk Toraks 2004;52(4):369-72.