

Thyroglossal cyst carcinoma: overview of 15 years experience

S. Nikakhlagh, MD.¹, N. Saki, MD.², N. Ranjbari, MD.³

Department of Otolaryngology, Head and Neck Surgery, Ahwaz Jondishapour University of Medical Sciences, Ahwaz, Iran.

Abstract

Background: Thyroglossal duct cysts (TDC) are the most common congenital neck masses arising from the expansion of the epithelial tract remnants occurring during embryogenic thyroid migration. About 7% of the population have thyroglossal duct remnants. Clinical presentation is frequent in children, but adults can also present with thyroglossal duct cysts. Thyroglossal duct cysts may rarely develop carcinomas (1-1.6 %) but tend to occur more in adults than children.

Methods: We retrospectively reviewed all cases of TDC carcinoma surgically treated during a 15-years period at Ahwaz Emam Hospital center.

Results: Three patients (two female and one male patient), who were 23 to 46 years old (mean 38 yr.) were identified. The frequency of TDC carcinoma among surgically removed TDC cysts was 0.7%. A midline upper neck mass was the initial symptom in all patients. The diagnosis of cancer was made after the Sistrunk's procedure in all three cases. All patients had papillary carcinoma. Thyroid involvement was noted in one case. One patient had near-total thyroidectomy, and two received postoperative radioactive iodine. After a mean follow-up of 11 years (range: 1 to 15 yr.), no patient had a documented local recurrence or distant metastatic involvement, and no tumor-associated mortality was observed.

Conclusion: Although development of a papillary thyroid carcinoma from thyroglossal cyst is very rare, it should be born in the mind of the surgeon and the pathologist that this possibility exists and the ductal wall should be examined elaborately.

Keywords: thyroglossal duct, cyst, papillary carcinoma, neck surgery.

Introduction

The thyroid gland begins to develop on the 24th day of embryogenesis and is identifiable as a segment of mesodermal cells in the floor of the pharynx, between the first and second pouches. The gland subsequently descends on an S-shaped path anterior to the trachea and reaches the thyroid cartilage by the 7th week. During this descent, the connection between the thyroid gland and the floor of the pharynx

(foramen cecum) may persist to form a thyroglossal duct. Secretions by the cells lining the remnant duct form thyroglossal duct cysts [1,2,3]. Thyroglossal duct cysts are the most common congenital cervical abnormality in childhood, with a frequency of 70% and about 7% in adults [4]. The condition is more common in women (1.5:1 ratio) than in men [5,6,7].

Only 1% of thyroid carcinomas evolve from a thyroglossal duct cyst [5,8]. Hence, since the first description by Bretano in 1911 until the present, only approximately 217 cases of thy-

1. Assistant Professor of Otolaryngology, Head and Neck Surgery, Imam Khomeini Hospital, Jondishapour University of Medicine Sciences, Ahwaz, Iran.

2. **Corresponding author**, Associate Professor of Otolaryngology, Head and Neck Surgery, Department of Otolaryngology, Head and Neck Surgery, Jondishapour University of Medical Sciences, Ahwaz, Iran. Tel/ Fax: +9861 13772027, email: nsaki_ir@yahoo.com

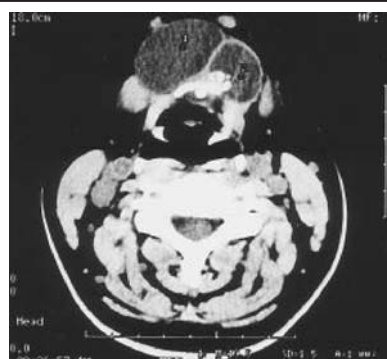3. Assistant Professor of Pathology, Department of Pathology, Jondishapour University of Medical Sciences, Ahwaz, Iran.

roglossal duct carcinoma have been reported in the relevant literature [3,6]. There are two malignant entities that affect the thyroglossal duct: carcinoma of the thyroid and squamous cell carcinoma [8,9,10]. Papillary carcinoma represents 80% of the cases [3,11,12]. Prognosis depends on the histological findings; the best prognosis is for well-differentiated carcinomas, and worsens for squamous cell carcinoma. It has not been clearly defined whether resection of the duct and the thyroglossal cyst must be accompanied by total thyroidectomy, neck dissection, and adjuvant therapy [6,7,13]. We describe three cases of papillary carcinoma in a thyroglossal duct cyst, and discuss the current opinions concerning management of the thyroid gland.

Methods

An archival search for all diagnosed cases of TDC carcinoma encountered at Ahwaz Emam Khomeini hospital from 1990 through 2004 was undertaken. During this period, 187 patients underwent a Sistrunk's procedure for TDC. Three cases were found. Criteria for inclusion in this study were clinical and operative evidence of a midline upper neck mass or a cyst above the thyroid gland, surgical and gross anatomic diagnosis of TDC, and confirmed histological diagnosis of a malignant lesion.

Three patients (two females and one male), aged 23 to 46 years old (mean 38 yr.) fulfilled the inclusion criteria. Two patients underwent an initial operation (Sistrunk's procedure). One patient was referred from another institution for completion thyroidectomy or suspicion of local recurrence after an initial Sistrunk's procedure elsewhere. No patient had a previous history of external irradiation to the head and neck. Preoperative levels of serum T3, T4, were available in three patients. A preoperative thyroid scan was performed in all patients, and a preoperative fine-needle aspiration (FNA) biopsy was done in one patient only. One patient underwent a



completion near-total thyroidectomy. Mean follow-up time was 10 years (range: 1 to 14 yr.).

Results

Among the 187 patients who underwent surgical excision of TDC at Emam Center between 1990 and 2004, the prevalence of TDC carcinoma associated with TDC was 1.6%. All three patients with TDC cancer were euthyroid preoperatively and had a midline upper neck mass at the time of initial examination. The TDC mass showed no uptake in isotopic neck scans. Tumor size was 0.8 to 3.0 cm, and all three cases were papillary carcinoma (Fig 1,2).

Surgical and gross pathologic findings, however, suggested carcinoma in the TDC remnant rather than in the pyramidal lobe. Foci of papillary carcinoma in the isthmus or thyroid lobes were found in one patient who underwent thyroidectomy. Invasion of the carcinoma to the adjacent tissues or lymph node metastases were not found. Thyroid function tests were normal as well as the thyroid scan. During follow-up the patient remained asymptomatic with no evidence of recurrence, as tested clinically and by ultrasonography, and all three patients received T4 therapy. No patient had documented local recurrence or postoperative distant metastatic involvement, and no tumor-associated mortality was observed.

Discussion

Thyroglossal duct cyst carcinoma is rare and has been reported in just over 200 cases. Van

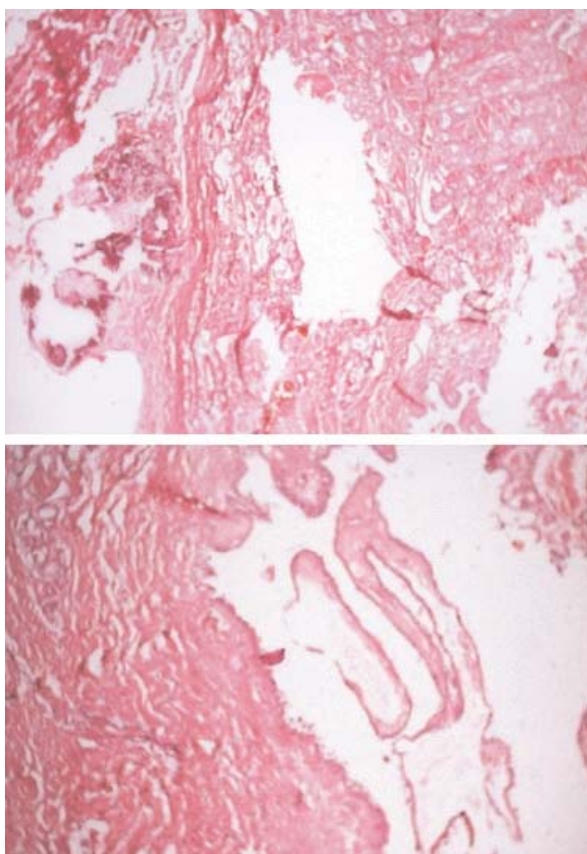


Fig. 2. Microscopic finding of TDC with intracystic papillary carcinoma.

Vuuren and associates collected 158 cases from the literature [4,8]. In a MedLine search of reported cases between 1990 and 2005, we encountered 59 cases not cited by Van Vuuren and colleagues [7,9,13]. Thus, with the addition of our 3 current cases, 220 cases of TDC carcinoma have been reported.

The incidence of thyroglossal duct cyst carcinoma varies from 0.7 to 1% of thyroglossal duct cysts [5,14,15]. The most common symptom is the presence of an anterior neck mass indistinguishable from those of thyroglossal duct cysts [4,6,12]. However, neoplasia must be suspected in cases of thyroglossal duct cyst with recent changes in clinical features. Imaging tests (ultrasound, computed tomography) do not allow a preoperative diagnosis and fine needle aspiration yields a correct result in only 66% of the cases. The histological diagnosis of thyroglossal duct cyst carcinoma requires the presence of

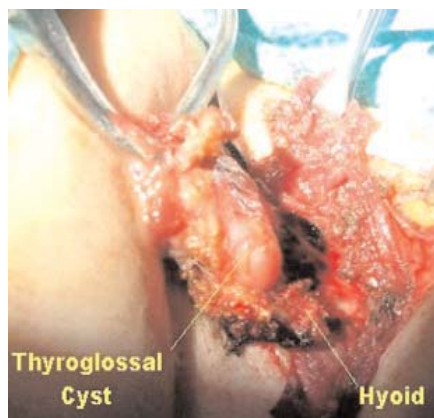


Fig. 3. Sistrunk's procedure.

malignant cells and also the presence of normal thyroid tissue within the cyst [12,15].

The most common histological type of thyroglossal duct cyst carcinoma is papillary carcinoma (80%); medullary carcinoma has not been reported in thyroglossal duct cyst, and anaplastic carcinoma is rare. Metastasis to regional lymph nodes is fairly rare, occurring about 10% of the time [11,12].

Our results on the prevalence of TDC carcinoma and the age distribution of patients are in agreement with data from the literature. No predisposing factor, such as irradiation, was noted. The initial symptoms were indistinguishable from those of a benign thyroglossal duct cyst. Thyroid scans were of no diagnostic help, and TDC carcinoma was diagnosed preoperatively only in the patient who had undergone FNA biopsy. FNA biopsy is the most reliable method of detecting a malignant process in these midline neck masses before surgical intervention [10,13].

Thyroid involvement has been observed in 11% of the reported cases of TDC carcinoma [3,7]. In our series, such involvement was present in 33% of patients. Because 2 of the 3 patients who underwent a Sistrunk's procedure did not undergo thyroidectomy and thus had no histopathologic evaluation of the thyroid, the actual incidence of thyroid involvement may be underestimated. Nevertheless, because of the absence of clinically recurrent disease in these

three patients after prolonged follow-up, the likelihood of a clinically significant thyroidal lesion in these subjects is minimal. In a patient with thyroid involvement, the foci of cancer in the thyroid ranged from 0.5 to 1 cm. In these cases, a metastatic lesion from occult thyroid cancer could not be excluded with certainty. Histological examination, however, showed no evidence of residual or adjacent lymph node tissue in the midline mass in our cases.

The recommended treatment of TDC carcinoma is the Sistrunk's procedure, in which the cyst, the middle part of the hyoid bone, and the TDC are removed in continuity (Fig. 3).

Sistrunk's procedure is associated with a reported cure rate of 95% in papillary carcinoma [14,15]. The need for completion bilateral subtotal or near-total thyroidectomy is controversial. Some surgeons have recommended that the Sistrunk's operation is adequate both for benign cysts and for malignant TDC cysts [5,13]. If thyroid abnormalities are demonstrated by palpation or ultrasound evaluation, however, thyroidectomy will become necessary.

Postoperatively, patients should be given T4 therapy similar to that for differentiated cancers of the thyroid gland. The indication for radioactive iodine ablative therapy in papillary thyroid cancer is controversial [2,13].

The prognosis associated with TDC papillary carcinoma is excellent and the occurrence of distant metastatic lesions is rarely reported (less than 2% of cases) [15]. In our series, none of the patients had local recurrence of disease, distant metastatic lesions or tumor-related mortality during a mean follow-up interval of 13 years.

TDC carcinoma is a rare malignant tumor that is usually diagnosed after surgery. Papillary carcinoma is the most common type. The currently recommended treatment is a Sistrunk procedure, with a tendency to deferred total thyroidectomy in selected cases. Long term follow-up is needed and the prognosis of patients with papillary cancer of the TDC cyst is excellent.

References

1. Allard RH. The thyroglossal duct cyst. In: Som PM, Curtin HD. *Head and Neck Surgery*. 3rd ed. St Louis: Mosby-Year Book; 1996. pp.1-134.
2. Hsu CY, Tsay SH, Hsieh RJ, Chiang H. Papillary carcinoma of thyroglossal duct cyst: a case report. *Chung Hua I Hsueh Tsa Chih (Taipei)* 1995; 55:199-202.
3. Chen KT. Cytology of thyroglossal cyst papillary carcinoma. *Diagn Cytopathol* 2003; 9:318-321.
4. Boswell W, Zoller M, Williams J, Lord S, Check W. Thyroglossal duct carcinoma. *Am Surg* 1994; 60:650-655.
5. Grabowska H. Papillary carcinoma arising from ectopic thyroid gland in the wall of a thyroglossal duct cyst. *Pathol Res Pract* 2003;189:1228-1229.
6. Khoo AK, Sittampalam K, Ooi LL. Primary papillary carcinoma in a thyroglossal cyst-a case report. *Ann Acad Med Singapore* 2003; 22:606-608.
7. Martin Pérez M, Burguio GM, Echevarria IC, Martinez PD. Papillary carcinoma arising in a thyroglossal duct cyst: report of two cases. *J Oral Maxillofac Surg* 1998; 51:89-93.
8. Kum CK, Goh P, Teh M. Papillary carcinoma arising in a thyroglossal cyst. *Aust N Z J Surg* 1999; 63:738-740.
9. Heshmati HM, Fatourehchi V, van Heerden JA, Hay ID, Goellner JR. Thyroglossal duct carcinoma: report of 12 cases. *Mayo Clin Proc* 1997; 72:315-319.
10. Renard TH, Choucair RJ, Stevenson WD. Carcinoma of the thyroglossal duct. *Surg Gynecol Obstet* 2003; 171:305-307.
11. Maziak D, Borowy J, Deitel M, Jaksic T, Ralph EA. Management of papillary carcinoma arising in thyroglossal duct anlage. *Can J Surg* 2004; 35:522-525.
12. Cote DN, Sturgis EM, Peterson T, Miller RH. Thyroglossal duct cyst carcinoma: an unusual case of Hürthle cell carcinoma. *Otolaryngol Head Neck Surg* 1995; 113:153-156.
13. Van Vuuren PA, Balm AJ, Gregor RT, Hilgers FJ. Carcinoma arising in thyroglossal remnants. *Clin Otolaryngol* 1994; 19:509-515.
14. Fernandez JF, Ordonez NG, Schultz PN, Saman NA, Hickey S. Thyroglossal duct carcinoma. *Surgery* 2001; 110:928-934.
15. Bdesha S, Layer T. Primary papillary carcinoma of a thyroglossal duct cyst: a report of a case and literature review [letter]. *Br J Surg* 1999; 79:1248-1249.